

Dextran-Coated Superparamagnetic Iron Oxide, an MR Contrast Agent for Assessing Lymph Nodes in the Head and Neck

Yoshimi Anzai, Stuart McLachlan, Marie Morris, Romaine Saxton, and Robert B. Lufkin

PURPOSE: To investigate dextran-coated superparamagnetic iron oxide particles (BMS 180549) as an MR contrast agent for assessing lymph nodes. **METHODS:** Five different doses ranging from 0.3 to 1.7 mg Fe/kg were evaluated in five healthy human male subjects as part of a phase 1 clinical study. T1-, T2-, and proton density-weighted spin-echo images as well as multiplanar gradient-echo and spoiled gradient-echo images were acquired before and 1 hour, 4 hours, and 24 hours after contrast administration. Image analysis was performed with visually selected regions of interest. Signal intensities were measured for neck lymph nodes and the adjacent muscle. Enhancement effects were evaluated as a function of dose, imaging time after contrast administration, and MR pulse sequence. **RESULTS:** The iron oxide particles were phagocytized by macrophages within the normal functioning lymph nodes, resulting in a dramatic decrease in signal intensity because of magnetic susceptibility effects. T2*-weighted gradient echo and T2-weighted spin echo showed significant decrease in the signal intensity of normal lymph nodes at 24 hours after contrast injection at a dose of 1.7 mg Fe/kg. No significant changes in lymph node signal intensity on T1-weighted spin-echo images were noted at any dose or imaging time point. **CONCLUSIONS:** This preliminary clinical evaluation demonstrates intravenous delivery of an iron-based contrast agent, resulting in negative enhancement of normal lymph nodes.

Index terms: Magnetic resonance, contrast enhancement; Contrast media, paramagnetic; Neck, magnetic resonance

AJNR Am J Neuroradiol 15:87-94, Jan 1994

The presence of lymph node metastases has a strong influence on treatment planning and prognosis of patients with head and neck cancers. It is difficult to differentiate metastatic lymph nodes reliably by either computed tomography (CT) or magnetic resonance (MR) using other than simple morphologic criteria. Radiologic findings suggesting lymph node metastasis include lymph node size larger than 1 to 1.5 cm in diameter, presence of central necrosis, and distortion of the adjacent fascial plane indicating extracapsular spread (1-5). However, there are small metastatic lymph

nodes without central necrosis and extracapsular spread; alternatively, they have large reactive nodes (larger than 1.5 cm) that contain no metastatic disease. This lack of definitive criteria to differentiate whether lymph nodes seen on CT or MR are metastatic or reactive is a serious shortcoming of our current imaging technique for patients with possible metastatic disease.

We have investigated the utility of an MR contrast agent, dextran-coated superparamagnetic iron oxide particles (BMS 180549; Squibb Diagnostics, Princeton, NJ), for assessing lymph nodes in the head and neck of healthy male volunteers as part of a phase-1 clinical evaluation of this agent. Iron oxide particles have strong T2 and susceptibility effects, which decrease the signal intensity of tissue in which they accumulate.

BMS 180549 consists of superparamagnetic iron oxide particles 17 to 20 nm in diameter, comparable in size to plasma proteins, which are able to leave the vascular compartment. When injected intravenously they are phagocytized by elements of the reticuloendothelial system including liver, spleen, lymph nodes, and bone marrow.

Received May 11, 1993; revision received and accepted August 12.

The Radiologist in Training Award is given by the American Society of Head and Neck Radiology. This paper was presented at the joint session of the American Society of Head and Neck Radiology and the American Society of Neuroradiology in Vancouver, May 1993.

From the Department of Radiological Sciences (Y.A., R.S., R.B.L.), University of California Los Angeles Medical Center, Los Angeles, Calif; and Bristol-Myers Squibb Diagnostics (S.M., M.M.), Princeton, NJ.

Address reprint requests to Yoshimi Anzai, MD, Department of Radiological Sciences, University of California Los Angeles Medical Center, 10833 Le Conte Ave, Los Angeles, CA 90024-1721.

AJNR 15:87-94, Jan 1994 0195-6108/94/1501-0087

© American Society of Neuroradiology

Enhancement effects were evaluated as a function of dose, imaging time after contrast administration, and MR pulse sequences.

Materials and Methods

Physical Characterization and Pharmacokinetics

BMS 180549 was provided as a lyophilized powder consisting of biodegradable ultrasmall superparamagnetic iron oxide particles covered with low-molecular-weight T10 dextran. The iron oxide core is a form of nonstoichiometric magnetite, 4.3 to 6.0 nm in diameter, with a total particle diameter in solution of 17 to 21 nm.

Preclinical animal studies with BMS 180549 have demonstrated that the agent has a long blood half-life of greater than 200 minutes and is taken up by elements of the reticuloendothelial system (RES) including liver, spleen, lymph nodes, and bone marrow (6). This drug is a biodegradable iron oxide particle which is metabolized in the same way as nonmagnetic iron dextran compounds. The biodegradable degradation of the particles releases iron which is metabolized in the usual iron metabolism pathway involving transferrin, ferritin, hemosiderin, and hemoglobin. Because the iron enters the normal body iron pool, excretion is expected to parallel that of normal body iron stores. The maximum dose is 1.7 mg Fe/kg, which equals 120 mg Fe for a 70-kg person. Consequently BMS 180549 makes only a small contribution to total iron stores, normally 2 to 4000 mg depending on sex and body weight.

MR Imaging

Five healthy men, 19 to 33 years old, underwent MR before and after intravenous injection of BMS 180549 as part of the phase-1 clinical evaluation of this agent. MR imaging was performed with a 1.5-T whole body MR superconducting instrument (General Electric, Signa, Milwaukee, Wis). Transverse multisection images were obtained with a section thickness of 5 mm using a 256 × 128 matrix. Images were acquired using a variety of spin-echo and gradient-echo pulse sequences. T1-, T2-, and proton density-weighted spin-echo images were obtained at 600/12/4, 2000/30/1, and 2000/80/1 (repetition time/echo time/excitations), respectively. Spoiled gradient-echo and multiplanar gradient-echo images were obtained using 34/5/2, 45° flip angle, and 900/17/4, 15° flip angle, respectively. A posterior neck surface coil was used with fields of view of 18 cm for spin-echo and 20 cm for gradient-echo. All five pulse sequences were obtained before contrast, at 1 hour, 4 hours, and 24 hours after intravenous administration of BMS 180549. MR images were obtained from the skull base to the supraclavicular region.

Contrast Agent Administration

Five different doses were evaluated: 0.3, 0.6, 0.8, 1.1, and 1.7 mg Fe/kg body weight. Each subject received a single dose of BMS 180549. BMS 180549 was provided as

a lyophilized powder which was reconstituted in 9.7 mL of 0.9% saline. The appropriate dose of reconstituted BMS 180549, based on the subject's body weight, was drawn up and diluted to 100 mL with normal saline (NaCl 0.9%). The diluted drug was infused into an antecubital vein at a rate of 4 mL/min. The total infusion time was 25 minutes.

Signal-Intensity Measurements

Signal-intensity measurements were made on neck lymph nodes visualized on axial images. Ten regions of interest on neck lymph nodes were selected for every pulse sequence in each volunteer on all images. The regions of interest were selected on lymph nodes with diameters larger than 5 mm. An additional five regions of interest were selected for the adjacent muscle. The percentage of enhancement relative to the precontrast image was calculated using the formula: $100 \times (SI_{\text{post}} - SI_{\text{pre}}) / SI_{\text{pre}}$, where SI_{pre} and SI_{post} are the precontrast and postcontrast signal intensity, respectively.

Because BMS 180549 has predominantly T2- and T2*-shortening effects, the signal intensity decreases are represented as negative enhancement ratios using the above formula. The enhancement effects were analyzed with regard to dose, imaging time after injection, and imaging sequence.

Sample means and standard deviations of signal intensity in regions of interest were calculated for all doses, imaging time points, and pulse sequences. The change in signal intensity (enhancement) of the lymph nodes and muscle was compared for the precontrast and postcontrast images using a paired Student *t* test.

Results

Dose Response

There was a dramatic decrease in signal intensity (negative enhancement) of the lymph nodes noted at 24 hours after intravenous administration at a dose of 1.7 mg Fe/kg for all MR pulse sequences except T1-weighted spin-echo images (Fig 1). However, no significant enhancement effects were observed on images at doses below 1.1 mg Fe/kg (see Fig 1), regardless of the pulse sequences or imaging time. Figure 2 illustrates the enhancement effects for lymph nodes and muscle measured from multiplanar gradient-echo images, clearly demonstrating that BMS 180549 significantly reduced the signal intensity at a dose of 1.7 mg Fe/kg 24 hours after administration (Fig 2). Therefore, in this preliminary study the optimum dose appeared to be 1.7 mg/kg body weight.

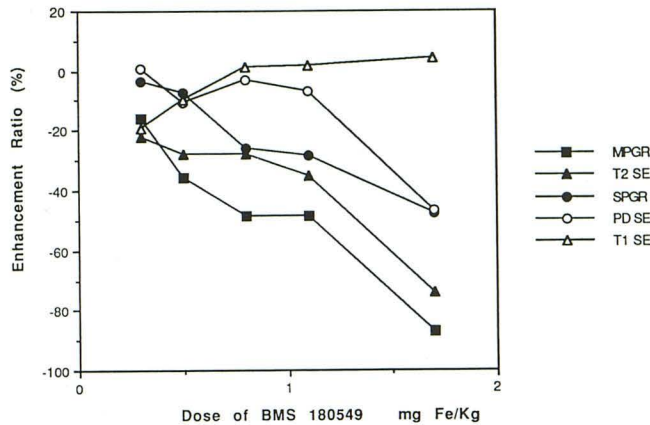


Fig. 1. Enhancement ratio as a function of dose with varying pulse sequences at 24 hours after contrast administration. Note dramatic enhancement seen at a dose of 1.7 mg Fe/kg on multiplanar gradient-echo (MPGR) and T2-weighted spin-echo (T2 SE) images. SPGR indicates spoiled gradient-echo; PDSE, proton-density spin-echo; and T1 SE, T1-weighted spin-echo.

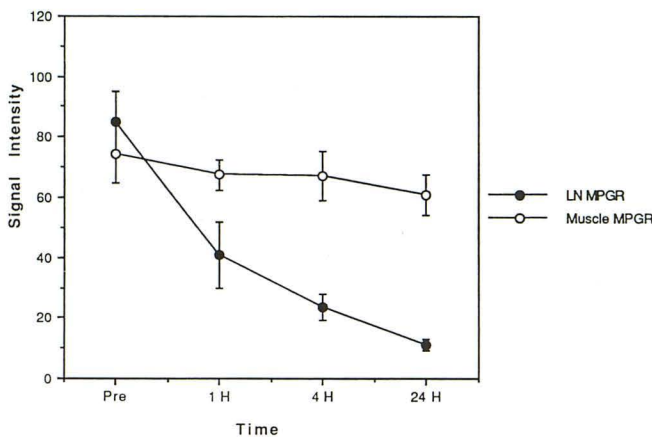


Fig. 2. Signal intensity of lymph nodes (LN) and muscle as a function of time after contrast administration of 1.7 mg Fe/kg on multiplanar gradient-echo images (MPGR). Closed circles and the error bar show means and SD of signal intensity for lymph nodes. Open circles and error bars represent the mean and SD signal intensity for muscle. Note significant signal intensity reduction of lymph nodes at 24 hours after contrast administration.

Optimum Time after Administration

The relationship between the enhancement ratio and time after injection was found to vary with pulse sequences at the maximum dose (1.7 mg Fe/kg) as shown in Figure 3. The enhancement effect was first detected on MR images 4 hours after administration. Negative enhancement effect was most prominent on images acquired 24 hours after administration on both multiplanar gradient-echo (T2*-weighted gradient-echo) images and T2-weighted spin-echo images in this study. Although it is possible that a peak enhancement ratio occurred either

between 4 and 24 hours or after 24 hours, the 24-hour images appeared to show adequately the enhancement effect with multiplanar gradient-echo (T2*-weighted gradient-echo) and T2-weighted spin-echo images (Figs 4 and Fig 5).

Optimum Pulse Sequence

Among the five MR pulse sequences evaluated, the multiplanar gradient-echo (T2*-weighted gradient-echo) images showed the most prominent enhancement effects, followed by the T2-weighted spin-echo image and the spoiled gradient-echo image (Figs 1 and Fig 3). Signal intensity measurement on regional lymph nodes and adjacent muscle showed a statistically significant signal reduction observed for lymph nodes 24 hours after administration of 1.7 mg Fe/kg; however, no significant changes were seen on adjacent muscle (Table 1). T1-weighted spin-echo showed no significant enhancement even at the maximum dose evaluated. The multiplanar gradient-echo (T2*-weighted gradient-echo) image and the T2-weighted spin-echo image with the maximum dose showed 87% and 75% reduction of signal intensity, respectively.

MR Imaging of Neck Lymph Nodes

Normal lymph nodes appeared as areas of low intensity compared with adjacent muscle on pre-contrast T1-weighted images and did not demonstrate any signal change at any dose or time point after contrast administration (Fig 6). On precontrast multiplanar gradient-echo images,

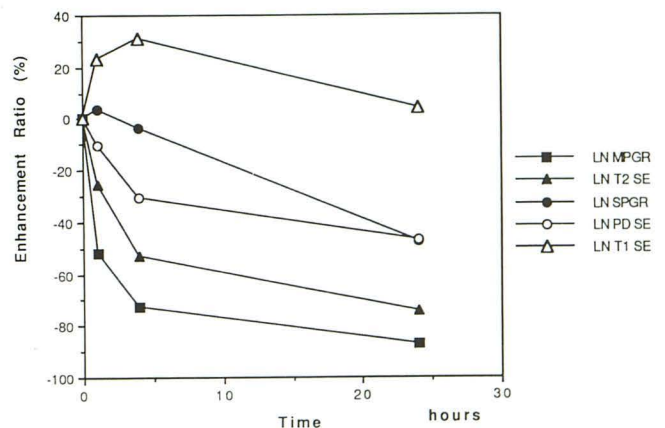


Fig. 3. Enhancement ratio as a function of time after contrast administration of 1.7 mg Fe/kg for the different imaging sequence evaluated. The maximum enhancement is seen at 24 hours after contrast administration for all pulse sequences. Abbreviations are as in Fig 1.

Fig. 4. Multiplanar gradient-echo images before (A) and 24 hours after (B) intravenous administration of 1.7 mg Fe/kg. Note dramatic signal intensity reduction of lymph nodes (arrow) on postcontrast images.

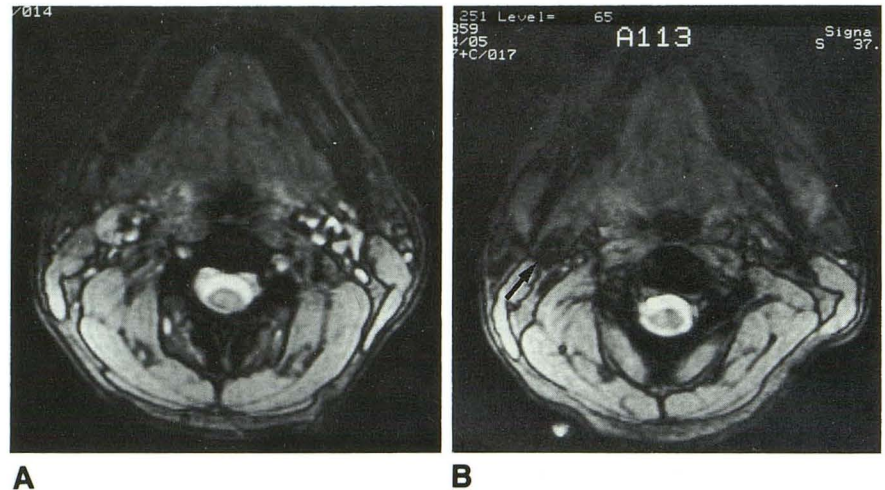


Fig. 5. T2-weighted spin-echo images before (A) and 24 hours after (B) intravenous administration of 1.7 mg Fe/kg. Signal intensity of the right jugulodigastric lymph nodes (arrow) shows significant signal decrease.

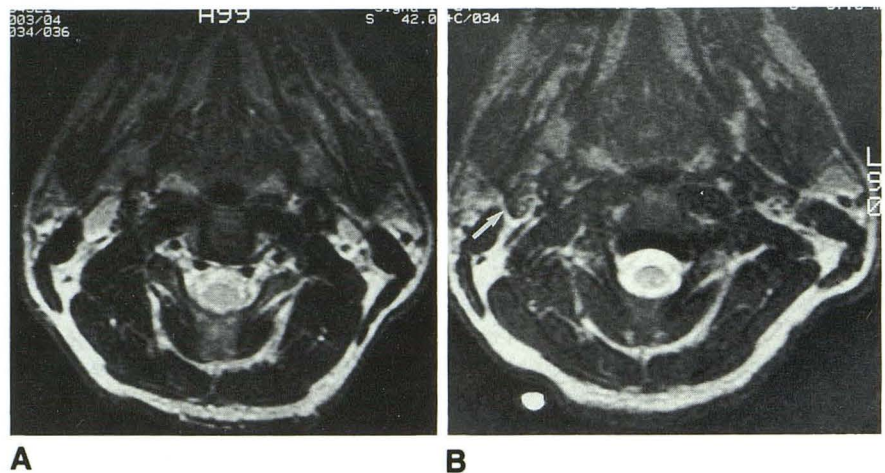


TABLE 1: Mean signal intensities and standard deviations of 10 regions of interest of lymph nodes and 5 regions of interest of muscle with a dose of 1.7 mg Fe/kg of dextran-coated superparamagnetic iron oxide

Imaging Sequence	Precontrast	24 hours after Contrast	Statistical Significance
T1-weighted spin-echo			
Lymph node	99.0 ± 13.5	103 ± 12	NS
Muscle	97.6 ± 12.5	98.0 ± 5.9	NS
T2-weighted spin-echo			
Lymph node	97.5 ± 10	25.2 ± 5.8	$P < .001$
Muscle	16.0 ± 0.8	15.1 ± 1.7	NS
Proton density weighted spin-echo			
Lymph node	197 ± 29	105 ± 19	$P < .001$
Muscle	120 ± 24	102 ± 10	NS
Multiplanar gradient-echo			
Lymph node	85.0 ± 9.9	11.1 ± 2.0	$P < .001$
Muscle	74.3 ± 9.8	61.1 ± 8.2	NS
Spoiled gradient-echo			
Lymph node	33.5 ± 6.3	17.6 ± 3.8	$P < .001$
Muscle	35.5 ± 3.8	38.0 ± 5.8	NS

lymph nodes were isointense with adjacent muscles. Twenty four hours after injection, the lymph node signal intensity dramatically decreased because of T2* effects from the accumulation of iron oxide particles within normal lymph nodes (Fig 5). The signal intensity of the normal lymph nodes after contrast was nearly equivalent to the signal void seen in airway or bony structures. The susceptibility effects seen in lymph nodes did not significantly decrease image quality. Postcontrast T2-weighted spin-echo images showed a substantial decrease in lymph node signal intensity compared with the precontrast images while providing sufficient contrast and clear anatomic details of other structures in the head and neck region (Fig 6).

Detectable differences were obtained on T2-weighted spin-echo and gradient-echo images at doses above 1.1 mg Fe/kg. At a dose of 1.1 mg Fe/kg, lymph nodes appeared to be heterogeneous with focal low-intensity areas, whereas at

a dose of 1.7 mg/kg, lymph nodes showed homogeneous low intensity. These findings were consistent and independent of lymph node size in the single subject done at that dose level.

Spoiled gradient-echo images demonstrated decreased signal intensity in lymph nodes and high signal in vascular structures 24 hours after injection, allowing normal lymph nodes to be easily differentiated from vascular structures (Fig 7). In addition, spoiled gradient-echo images provided almost identical soft-tissue contrast to that on T1-weighted spin-echo images, which is believed best to demonstrate anatomic details in the head and neck region (1, 7-9). The relatively short echo time used in these images also reduced magnetic susceptibility artifacts on spoiled gradient-echo images caused by adjacent bony structure or paranasal sinuses.

Discussion

The presence of lymph node metastasis in patients presenting with head and neck cancer has been suggested by the criteria of size of lymph nodes, evidence of central necrosis, or extracapsular spread. Central necrosis and extracapsular spread are relatively late findings seen in advanced cases. The majority of metastatic lymph nodes do not have central necrosis or extracapsular spread. The size criterion is also insensitive because there is obviously overlap between sizes of metastatic and reactive lymph nodes. Moreover, T1 and T2 relaxation times of metastatic and normal lymph nodes show substantial overlap and appear to be uninformative (10, 11). Administration of gadopentetate dimeglumine may improve the detectability of central

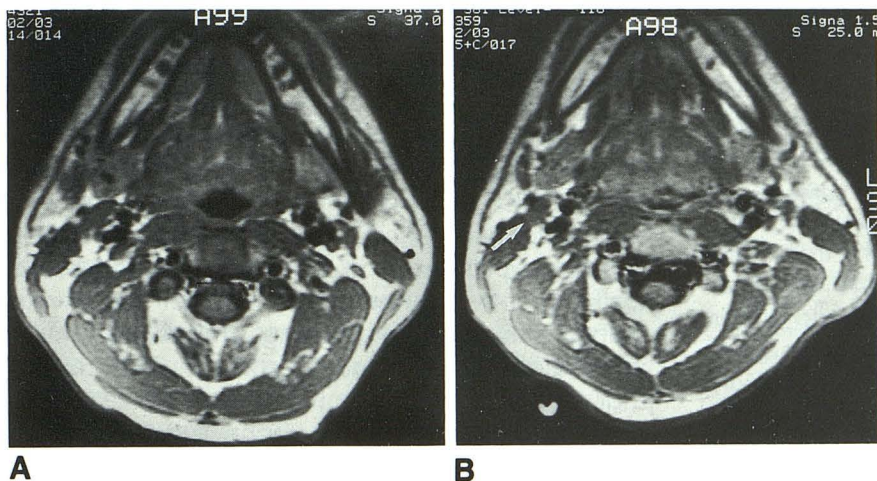


Fig. 6. T1-weighted spin-echo images before (A) and 24 hours after (B) intravenous administration of 1.7 mg Fe/kg. Signal intensity of lymph nodes (arrow) remains unchanged.

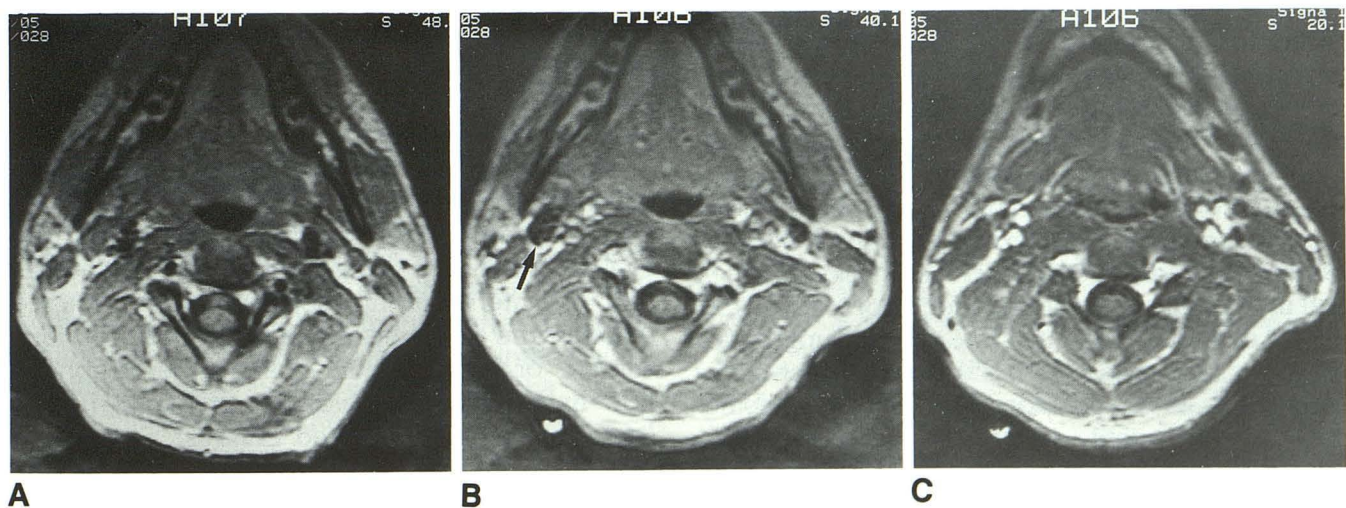


Fig. 7. Spoiled gradient-echo images before (A) and 24 hours after (B and C) intravenous administration of 1.7 mg Fe/kg. Signal intensity of lymph nodes (arrow) decreases after the contrast administration. In addition, significant signal is seen in the vascular structures (C), which allow easy differentiation of lymph nodes from vascular structure.

necrosis within lymph nodes, because the area of necrosis does not show enhancement. However, the efficacy of gadopentetate dimeglumine for differentiating metastatic from reactive lymph node is limited because lymph node metastasis can occur without necrosis.

More recently positron emission tomography using 18F-fluoro-deoxyglucose has been of interest as a new imaging mode of the head and neck region (12–14). 18F-fluoro-deoxyglucose positron emission tomography imaging allows cross-sectional imaging of the status of glucose metabolism in biologic tissue. 18F-fluoro-deoxyglucose can detect the presence of small neoplasms or recurrent tumor after surgery or radiation therapy, which have been difficult to find using imaging modalities based on morphology, such as CT and even MR. It has been reported, however, that 18F-fluoro-deoxyglucose positron emission tomography images show activity in some reactive lymph nodes and metastatic lymph nodes (12). This result indicates that reactive lymph nodes may show relatively high glucose metabolism compared with normal adjacent structures.

In this study, we investigated the use of an intravenous MR contrast agent to evaluate lymph nodes in the head and neck region. The iron oxide particles which comprise BMS 180549 are small enough to traverse capillaries' network within lymph nodes. Subsequently, the drug is absorbed into the lymphatic vessels from the interstitium and carried to regional lymph nodes. The iron particles are slowly cleared from the circulation by the reticuloendothelial system of liver and spleen, as well as by lymph nodes and bone marrow. This enables the agent to enhance lymph nodes in any other area of body with a single intravenous administration.

A variety of preparations of superparamagnetic iron oxide have been reported, including ferrite particles coated with albumin or hydrophilic material (15, 16), ferromagnetic microspheres (17), superparamagnetic iron oxide crystals (AMI 25, Advanced Magnetics, Cambridge, Mass) (18–21), and ultrasmall superparamagnetic iron oxide (USPIO, Advanced Magnetics) (22, 23). Superparamagnetic iron oxide (AMI 25) was the first clinically used as a reticuloendothelial cell-specific MR contrast agent, which has been used for improved detectability of tumors in liver and spleen. AMI 25 has a relatively large particle size (80 nm in diameter) that makes this agent easily recognized by the mononuclear phagocytic system of the liver and spleen, resulting in very short

blood half-time (6 minutes) (21). Although interstitial injection of AMI 25 was reported to enhance relaxivity of lymph nodes in an animal model, intravenous injection of AMI 25 did not provide lymph node enhancement because of large particle size and short blood half-time (20). USPIO was obtained through size fractionization of AMI 25 and is equivalent to the smallest 10% to 15% of AMI 25. Small particle size (11 nm in diameter) and longer plasma half-time (81 minutes) enables USPIO to cross the capillary wall and provide more widespread tissue distribution than AMI 25, including uptake by the mononuclear phagocytic system of lymph nodes and bone marrow. USPIO was the first reported intravenous MR contrast agent for assessing lymph nodes in animal model (23). To the best of our knowledge, USPIO has not been used for lymph node evaluation of human subjects.

BMS 180549 is dextran-coated superparamagnetic iron oxide (17–21 nm) colloid that provides considerably longer plasma half-life (greater than 200 minutes) than USPIO despite the fact that BMS 180549 has a slightly larger particle size than USPIO. The recognition by macrophages mainly depends on: 1) size of the particles; and 2) surface properties of the particles. Iron oxide itself can be either negatively or positively charged in solution, causing immobilization of water molecules around its surface. This results in gradual enlargement of the particle size during circulation. Dextran is an uncharged coating for the iron oxide particles and effectively stabilizes particle size in the vascular compartment. Thus, dextran-coated particles are not easily trapped by the mononuclear phagocytic system of liver and spleen. BMS 180549 consists of biodegradable particles metabolized in the normal iron catabolic pathway and excreted from the body.

Intravenous MR contrast agents offer several advantages over interstitial injection of contrast agents. Intravenous administration allows the evaluation of any area of the body, whereas multiple interstitial injections would be required to cover the whole head and neck area. Previous surgery or biopsy could change the lymphatic flow and prevent visualization of lymph nodes. Intravenously administered contrast agents can be cleared more rapidly from the injection site than interstitial administration. Therefore, intravenous administration can avoid the potential drawback of delayed washout observed in interstitial injection (23, 24). Additionally, intravenous

administration is usually less painful than multiple interstitial injections.

BMS 180549 seems to have potential as an intravenous contrast agent for assessing lymph nodes by using the phagocytotic function of lymph nodes. Metastatic lymph nodes, either completely or partially filled with tumor cells, have less phagocytic activity and presumably may have little or no uptake of this contrast agent. If this turns out to be true, this could result in unchanged signal intensity in the area of tumor involvement. Conversely, reactive lymph nodes show hyperplasia in all cellular elements, including macrophages, which might result in decreased signal intensity. BMS 180549 has the potential to allow detection of nodal metastases based on signal intensity characteristics rather than currently used insensitive size criteria.

The detection of small nodes or small filling defects in contrast-filled nodes is still limited by the imaging spatial resolution constraints of the MR instrument (section thickness, field of view, etc). Additionally, the signal dropout caused by susceptibility effects of the iron has the potential to mask small filling defects in the node if the appropriate pulse sequence (ie, T2* effects) is not chosen. Clearly, more work needs to be done in this area to define these issues better. Clinical studies in cancer patients with MR-histopathologic correlations are now in progress to investigate the potential of this new contrast agent.

Among several pulse sequences evaluated in this study, multiplanar gradient-echo (T2*-weighted gradient-echo) images and T2-weighted spin-echo images showed significant enhancement of normal lymph nodes. T1-weighted spin-echo did not provide any signal intensity changes even at the maximum dose. An additional finding on postcontrast spoiled gradient-echo images was significant signal of vascular structures, even 24 hours after administration. This may prove helpful in differentiating vascular structure from normal or metastatic lymph nodes. Whereas vascular structures seemed to be hyperintense, normal lymph nodes become hypointense after contrast administration. Presumably the signal intensity of metastatic lymph nodes will remain the same after administration of the drug.

The optimal imaging time for the postcontrast MR examination has not yet been determined. It is possible that the peak enhancement may occur between 4 and 24 hours or after 24 hours; however, sufficient changes were noted at 24 hours. The time-response curve is presumably biphasic

in configuration and influenced by two mechanisms: 1) the uptake by macrophage phagocytosis; and 2) subsequent biodegradation resulting in the loss of superparamagnetic properties. This issue will be resolved in future clinical trials. Binding of this contrast agent to monoclonal antibodies may be an alternative approach for improving tumor specificity. Monoclonal-coated BMS 180549 could provide a method for detection of metastatic tumor deposits in other sites.

Conclusion

This preliminary clinical evaluation of BMS 180549 demonstrates intravenous delivery of an iron-base contrast agent resulting in negative enhancement of normal lymph nodes in human subjects. Future studies, currently in progress, will be required to measure directly the sensitivity, specificity, safety, and effectiveness of this contrast agent for detection of metastatic tumors in cancer patients.

References

1. Mancuso AA, Hanafee WN. *Computed tomography and magnetic resonance imaging of the head and neck*. 2nd ed. Baltimore: Williams and Wilkins, 1984:169-240
2. Mancuso AA, Maceri D, Rice D, Hanafee WN. CT of cervical lymph node cancer. *AJR Am J Roentgenol* 1981;136:381-385
3. Mancuso AA, Harnsberger HR, Muraki AS, Stevens MH. Computed tomography of cervical and retropharyngeal lymph nodes: normal anatomy, variants of normal and applications in staging head and neck cancer. Part I: normal anatomy. *Radiology* 1983;148:709-714
4. Som PM. Lymph nodes of the neck. *Radiology* 1987;165:593-600
5. Som PM. Detection of metastasis in cervical lymph nodes: CT and MR criteria and differential diagnosis. *AJR Am J Roentgenol* 1992;158:961-969
6. Bengel HH, Palmacci S, Rogers J, Jung CW, Crenshaw J, Josephson L. The biodistribution of an ultrasmall superparamagnetic iron oxide colloid, BMS 180549, by different routes of administration. *Magn Reson Imaging* (in press)
7. Lufkin RB, Larsson SG, Hanafee WN. Work in progress: NMR anatomy of the larynx and tongue base. *Radiology* 1983;148:171-175
8. Teresi LM, Lufkin RB, Vinuela F, et al. MR imaging of the nasopharynx and floor of the middle cranial fossa. Part 1. Normal anatomy. *Radiology* 1987;164:811-816
9. Lufkin RB, et al. Tongue and oropharynx: findings on MR imaging. *Radiology* 1986;161:69-75
10. Dooms GC, Hricak H, Crooks LE, et al. Magnetic resonance imaging of the lymph nodes. Comparison with CT. *Radiology* 1984;153:719-728
11. Dooms GC, Hricak H, Moseley MR, Bottles K, Fisher MR, Higgins CB. Characterization of lymphadenopathy by magnetic relaxation times: preliminary results. *Radiology* 1985;155:691-697
12. Jabour BA, Choi Y, Hoh CK, Rege SD, Soong J, Lufkin RB, et al. PET imaging of the extracranial head and neck using 2-(18F)-fluoro-2-deoxy-D-glucose (FDG) with MRI correlation. *Radiology* 1993;186:27-35

13. Bailet JW, Abemayor E, Jabour BA, Hawkins RA, Ho C, Ward P. Positron emission tomography: a new precise imaging modality for detection of primary head and neck tumors and assessment of cervical adenopathy. *Laryngoscope* 1992;102:281-288
14. Hawkins RA, Hoh C, Dahlbom M, Choi Y, et al. PET cancer evaluation with FDG (editorial). *J Nucl Med* 1991;32:1555-1558
15. Saini S, Stark DD, Hahn PF, Wittneberg J, Brady TJ, Ferrucci JT. Ferrile particles: a superparamagnetic MR contrast agent for the reticularendothelial system. *Radiology* 1987;162:211-216
16. Saini S, Stark DD, Hahn PF, et al. Ferrile particles: a superparamagnetic MR contrast agent for enhanced detection of liver carcinoma. *Radiology* 1987;162:217-222
17. Widder DJ, Greif WL, Widder KJ, Edelmann RR, Brady TJ. Magnetic aluminum microspheres: a new MR contrast material. *AJR Am J Roentgenol* 1987;148:399-404
18. Stark DD, Weissleder R, Elizondo CT, et al. Superparamagnetic iron oxide: clinical application as a contrast agent for MR imaging of the liver. *Radiology* 1988;168:297-301
19. Weissleder R, Hahn PF, Stark DD, et al. Superparamagnetic iron oxide: enhanced detection of focal splenic tumors with MR imaging. *Radiology* 1988;169:399-403
20. Weissleder R, Elizondo CT, Josephson L, et al. Experimental lymph nodes metastases: enhanced detection with MR lymphography. *Radiology* 1989;171:835-839
21. Weissleder R, Stark DD, Engelstad B, et al. Superparamagnetic iron oxide: pharmacokinetics and toxicity. *AJR Am J Roentgenol* 1989;152:167-173
22. Weissleder R, Elizondo CT, Wittenberg J, Rabito CA, Bengel HH, Josephson L. Ultrasmall Superparamagnetic iron oxide: Characterization of a new class of contrast agents for MR imaging. *Radiology* 1990;175:489-493
23. Weissleder R, Elizondo CT, Wittenberg J, Lee AS, Josephson L, Brady T. Ultrasmall superparamagnetic iron oxide. An intravenous contrast agent for assessing lymph nodes with MR imaging. *Radiology* 1990;175:494-498
24. Tanoura T, Bernas M, Darkazani A, et al. MR lymphography with iron oxide compound AMI 227: studies in ferrets with filariasis. *AJR Am J Roentgenol* 1992;159:875-881