

Preoperative Spinal Angiography for Lateral Extracavitary Approach to Thoracic and Lumbar Spine

Anna M. Champlin,¹ Jesse Rael,^{2,5} Edward C. Benzel,³ Lee Kesterson,^{3,6} Jerry N. King,^{1,7} William W. Orrison,^{1,4} and Mansour Mirfakhraee²

PURPOSE: To establish the safety, efficacy, and value of preoperative angiography in the surgical management of thoracic and lumbar spine disease, in which it is important to avoid injury to the artery of Adamkiewicz or other vessels that supply the spinal cord. **METHODS:** Sixty-one patients were evaluated primarily using digital subtraction angiography, low-osmolar or nonionic contrast agents, selective catheterization limited to the region of disease, and careful angiographic techniques. **RESULTS:** Two minor (small hematomas of the groin) and no major complications of angiography were encountered. Arterial supply to the spinal cord was identified in 22 patients. In 17 patients (77%), the arterial supply was in the region of planned surgery. In each of these patients the surgical approach was altered, either by dictating the use of a posterior surgical approach (four patients) or by altering the side of the lateral extracavitary approach (13 patients). **CONCLUSION:** Spinal angiography is a safe preoperative examination for thoracic and lumbar spine surgery. It is specifically useful when the lateral extracavitary surgical approach to spinal cord decompression and fusion (which predictably interrupts the terminal end-arterial blood supply to the spinal cord, if present) is planned.

Index terms: Angiography, preoperative; Spine, angiography; Spine, surgery; Spine, blood supply

AJNR Am J Neuroradiol 15:73-77, Jan 1994

The lateral extracavitary surgical approach to the thoracic and lumbar spine was described by Capener in 1954 (1) and reintroduced by Larson et al in 1976 (2), with further refinements subsequently described (3). This surgical technique involves an approach to the spine that allows

ventral decompression of the spinal cord, while simultaneously enabling the placement of dorsal instrumentation constructs through the same incision (2, 3).

During the lateral extracavitary and other ventral surgical approaches to the spine, segmental aortic branches can be unavoidably damaged or sacrificed. This may result in the interruption of blood flow in the terminal radicular branches at the level of the neuroforamina (Fig 1), beyond which collateral arterial connections are sparse. More proximally, however, collateral channels exist (Fig 2). Thus, if anterior or anterolateral surgical approaches are used, a lesser chance of inducing terminal vascular insufficiency exists.

The lateral extracavitary surgical approach to the spine, however, places the spinal cord at ischemic risk, because of terminal radicular arterial interruption. This can be minimized by an appropriately conceived operation. Spinal angiography can assist in this process. In order to demonstrate the utility and safety of spinal angiography as a preoperative diagnostic test, an experience with 61 patients is reported.

Received January 27, 1992; accepted pending revision June 17; final revision received January 15, 1993.

Presented at the Neurosurgical Joint Section on Spine and Peripheral Nerves, Captiva, Fla, 1989. Poster presented at the American Association of Neurological Surgeons, San Francisco, Calif, April 1992.

Departments of ¹Radiology, ³Neurosurgery, and ⁴Neurology, University of New Mexico, School of Medicine, Albuquerque, NM 87131-5336.

²Department of Radiology, Louisiana State University Medical Center, Shreveport, LA 71130.

⁵Current address: 1800 Coffee Road, Suite 110, Modesto, CA 95355.

⁶Current address: Lovelace Medical Center, Department of Radiology, 5400 Gibson Blvd SE, Albuquerque, NM 87108.

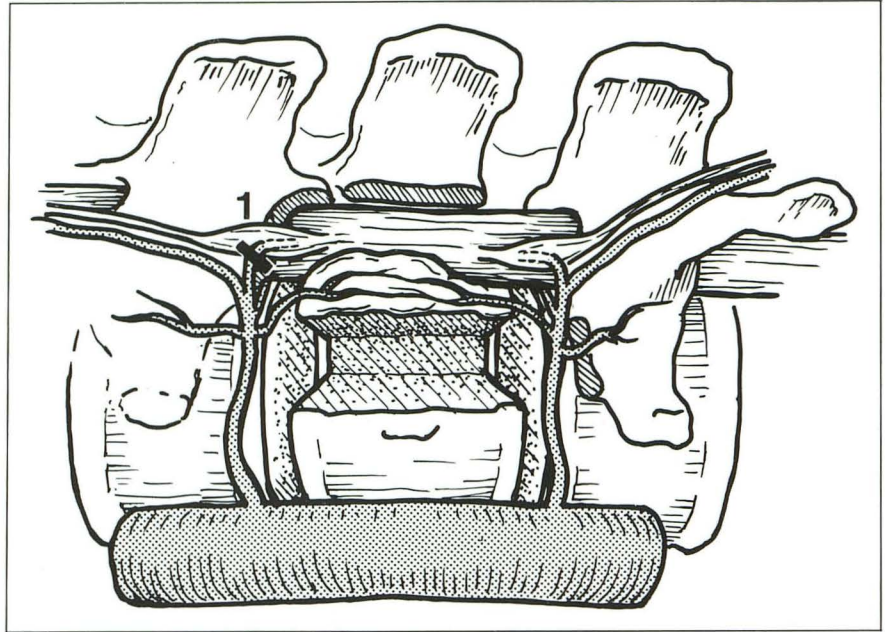
⁷Current address: University of New Mexico, School of Medicine, Department of Radiology, 2211 Lomas Blvd, Albuquerque, NM 87131-5336.

Address reprint requests to Anna Champlin, MD, The University of New Mexico, School of Medicine, Department of Radiology, 2211 Lomas Blvd, Albuquerque, NM 87131-5336.

AJNR 15:73-77, Jan 1994 0195-6108/94/1501-0073

© American Society of Neuroradiology

Fig. 1. Lateral view of the lateral extracavitary approach to the decompression of a thoracolumbar spine fracture. The pedicle of the involved spinal segment has been surgically removed. Note that a trough has been created in the vertebral body of the involved segment, undermining the offending fragment that is impinging on the dural sac. This fragment will subsequently be removed, thus relieving the dural sac compression. Of note is the appearance of the segmental arteries entering the spinal canal immediately above and below the involved segment. Their interruption may result in an ischemic injury to the spinal cord. 1 indicates transection of the terminal branch



Materials and Methods

Sixty-one patients underwent spinal angiography as part of their radiologic evaluation before decompression and fusion using the lateral extracavitary approach for thoracic and lumbar spine disease. These patients were evaluated and treated at Louisiana State University Medical Center-Shreveport between November 1981 and June 1989 and the University of New Mexico Hospital, Albuquerque, between July 1989 and November 1990. There were 43 men and 18 women. Ages ranged from 14 to 61 years with a mean of 31 years. The majority of cases (57 of 61) were fractures and/or subluxations secondary to trauma. The mechanisms of trauma were motor vehicle accidents (44 patients), motorcycle accidents (four patients), and falls (nine patients). Two patients had preoperative evaluations for herniated thoracic disks. One patient had a pathologic fracture due to a vertebral metastasis, and one patient had thoracolumbar scoliosis requiring surgical reconstruction. All patients were neurologically incomplete (some preserved sensory or motor function).

The greatest number of cases involved the region of the thoracolumbar junction with 18 cases involving thoracic vertebra 12 (T-12) and 21 cases involving lumbar vertebra 1 (L-1). The following levels were also involved: T-8 (10 patients); T-11 (seven patients); T-10 (six patients), L-2 (six patients); T-9 (5 patients); T-6 and T-7 (3 patients each); and T-3, T-4, T-5, L-3, and L-4 (one patient each). The total number of levels exceeds 61, because of multiple spinal levels of involvement in several patients. Neurologic deficits ranged from radicular pain and paresthesia to high-grade sensorimotor deficits secondary to dural-sac compression. In all patients arteriograms were performed preoperatively.

The angiographic technique used in this series was a modification of the technique described by Djindjian (4).

The intercostal or lumbar arteries were selectively catheterized bilaterally at the level of the injured vertebra as well as two levels above and two levels below the injury. An extensive search for the artery of Adamkiewicz outside these boundaries was not performed, because only the vascular supply to the spinal cord in the area of intended surgery was of interest. This limited study was, therefore, used to minimize the invasive nature of the procedure. All studies were performed under local anesthesia. Selective 5-F angiographic catheters, including cobra, simmons, and shepards hook (Meditech, Watertown, Mass), were used for the procedures. Early in the study, ionic contrast material was used. However, as low-osmolar (ioxaglate; Mallinckrodt, St Louis, Mo) and nonionic (iopamidol; Bristol Myers-Squibb, Princeton, NJ; and iohexol; Winthrop Pharmaceuticals, New York, NY) contrast agents became available, only these were used. Before the development of digital subtraction angiography, cut film and manual subtraction images were obtained. Subsequently, all cases were performed using the digital subtraction angiography technique (512 matrix at Louisiana State University Medical Center-Shreveport and 1024 matrix at University of New Mexico-Albuquerque). The maximum volume of contrast material used was 4 to 6 cc per injection for cut film and 2 to 3 cc per injection for digital subtraction angiography images. Immediately after the contrast injection, the catheter was removed from the artery. The duration of the study varied considerably depending on the patient's age and degree of atherosclerotic disease. Patients were monitored during the procedure for neurologic, vital sign, or oxygen saturation changes. Evoked-potential monitoring was not used because it could not add to the diagnostic accuracy or safety beyond that achieved by serial neurologic examination of lower extremity function. The latter included both extensive motor (if present) and sensory

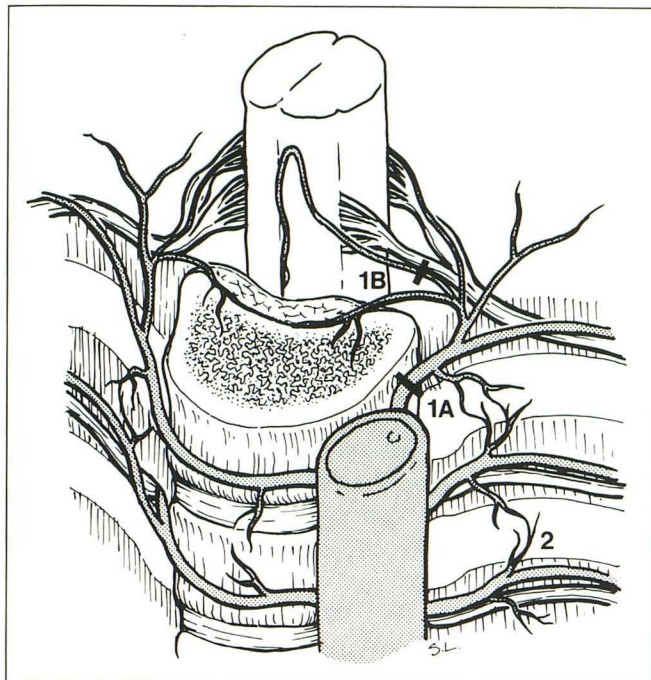


Fig. 2. 1 indicates the level of potential surgical interruption of the artery; A, anterior approach; B, lateral extracavitary approach; and 2, collateral communication.

testing before the angiographic procedure and frequently during the procedure, particularly after each injection of contrast.

Results

The radicular artery of Adamkiewicz with its characteristic hairpin appearance (Fig 3) was located in 20 cases (33%). In eight patients the artery was fed from the right and in 12 from the left. The location of the radicular artery was at the following vertebral levels: T-11 (five patients); T-10 and L-1 (three patients each); T-9, T-12, and L-2 (two patients each); T-6 (one patient); and T9-10 common origin (one patient). In two additional patients the anterior spinal artery was seen through small collateral-radicular arteries, without identification of the artery of Adamkiewicz. This supply was demonstrated at two levels, T-7 and L-1. Spinal cord supply was, therefore, demonstrated in 22 (20 + 2) patients (36%). Of these, 17 (77.3%) were in the immediate area of intended surgery. The surgical procedure was, thus, tailored in each of these cases either by using a posterior (rather than the lateral extracavitary) approach (four patients) or by performing the procedure on the side opposite the radicular artery (13 patients). When a posterior approach was used, retractor ventral bone and disk frag-

ments were surgically reduced via a costotransversectomy approach, followed by posterior fusion and instrumentation placement.

Angiographic complications consisted of two small arterial puncture site hematomas. No neurologic complications were encountered.

Discussion

Spinal angiography is not a commonly performed radiologic procedure, although its use in the workup of spinal arteriovenous malformations (5-10) and tumors (11-14) has been well documented. Less common indications include preoperative evaluation for scoliosis surgery (15) and for resection of thoracic-aortic aneurysm (16). From 1949 to 1967, 84 cases of spinal cord complications related to angiography were re-

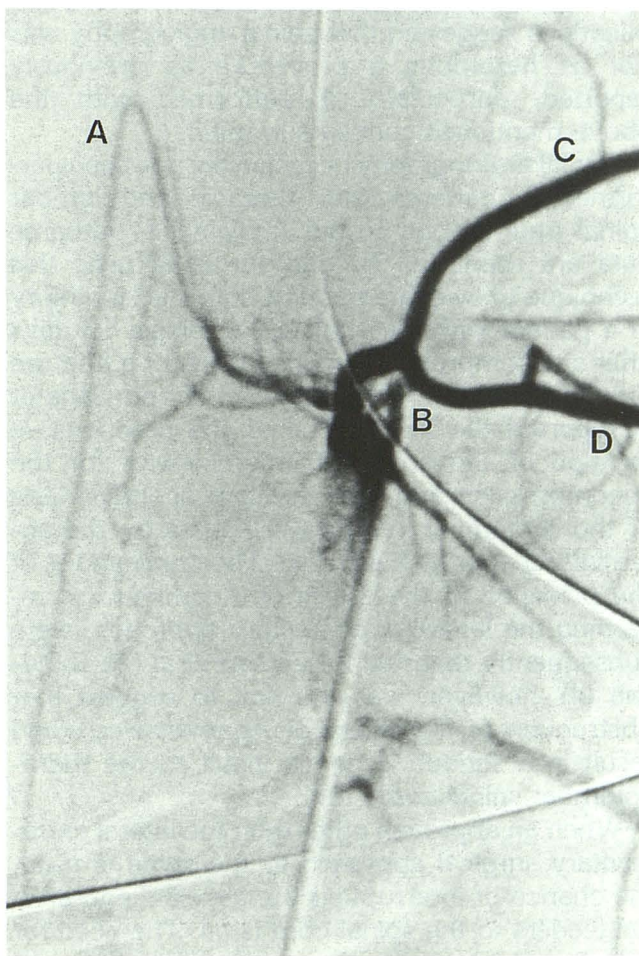


Fig. 3. A magnified digital subtraction angiography image demonstrating the hairpin appearance of the artery of Adamkiewicz (A). This hand injection was made, using ioxaglate at 1 cc/second for 3 seconds with a film rate of four frames per second, on the left side at T-10 (B) with filling of both T-9 (C) and T-10 (D) intercostal arteries from this common trunk.

ported (17, 18). Acetriozone, used in 43 of those cases reported by Killen and Foster (19) and DiChiro (20), is no longer available. Transverse myelitis after selective bronchial arteriography has been reported, but its incidence is not known (18). Kardjiev et al (21) reported neurologic complications in five of 28 patients undergoing selective injection of the right fifth intercostal artery during angiography for lung disease. After modifying their technique by decreasing the amount of contrast and pressure used during injection into intercostal and bronchial arteries, there were no complications in their next 60 patients. Forbes et al (17) reported a prospective study that evaluated the complication rate related to spinal angiography during radiologic workup of arteriovenous malformations and tumors. They concluded that the frequency of neurologic (2.2%), local (8.2%), and systemic nonneurologic (3.7%) complications suggested that spinal angiography was not as hazardous a procedure as previously reported, particularly if performed with the above-mentioned concerns in mind.

Spinal arteriography occasionally has been performed in patients with thoracic and lumbar spinal trauma, but, to our knowledge, outcome data are scant (2, 3). Gargour et al used this technique to evaluate possible spinal artery injury in a patient with incomplete paraplegia 17 days after a decompression laminectomy for a fracture dislocation of L-1 (22). Bussat et al and Gage et al reported the importance of the preoperative location of the artery of Adamkiewicz for the decompression and intervertebral spondylodesis of thoracolumbar vertebral fractures by the anterolateral approach (23, 24). The implications of the presence of the artery of Adamkiewicz, regarding the lateral extracavitary approach, were subsequently reported by Larson et al (2). Djindjian (4), however, was the first to suggest that obstruction of the artery of Adamkiewicz could result in a serious ischemic insult to the thoracolumbar spinal cord.

When an approach other than the lateral extracavitary surgical approach to the spine is used, the chance of interrupting the terminal end-arterial feeders to the spinal cord is nil. The need for spinal angiography in this patient population is, thus, similarly nil. On the other hand, when the lateral extracavitary surgical approach to the spine is used, terminal end-arterial feeders are obligatorily interrupted if present at the level and side of the surgical decompression. In these cases,

spinal angiography may, indeed, predict the potential for catastrophe.

Although the incidence of neurologically significant vascular injuries related to surgical interruption of the artery of Adamkiewicz is not known, the avoidance of the artery appears prudent. The posterior surgical approach avoids injury to radicular vessels, because of their location within the nerve-root sleeve and dural sac in the region exposed by the operation. Because either the right or left side may be approached via the lateral extracavitary technique in cases with relatively symmetrical disease, the side opposite the initially planned side of surgery may be safely approached if supply to the cord is identified by preoperative angiography. The use of selective catheters, digital subtraction angiography, and low-osmolality contrast agents, as shown by Kardjiev, Forbes, and this series, has decreased the morbidity initially associated with this procedure. Consequently, spinal angiography, limited to the region of planned surgery, has been incorporated into the routine radiologic-diagnostic evaluation at our institutions when a lateral extracavitary surgical approach is planned in order to prevent possible ischemic injury to an already damaged spinal cord.

References

1. Capener N. The evolution of lateral rhachotomy. *J Bone Joint Surg [Br]* 1954;36:173-179
2. Larson SJ, Holst RA, Hemmy DC, et al. Lateral extra-cavitary approach to traumatic lesions of the thoracic and lumbar spine. *J Neurosurg* 1976;45:628-637
3. Benzel EC. The lateral extra-cavitary approach utilizing the three-quarter prone position. *J Neurosurg* 1989;71:837-841
4. Djindjian R. Angiography of the spinal cord. *Surg Neurol* 2:1974;179-185
5. DiChiro G, Werner L. Angiography of spinal cord. A review of contemporary techniques and applications. *J Neurosurg* 1973;39:1-29
6. Doppman JL, DiChiro G. Subtraction angiography of spinal cord vascular malformation. *J Neurosurg* 1965;23:440-443
7. Hondart R, Djindjian R, Hurth M, et al. Vascular malformations of the spinal cord. *J Neurosurg* 1966;24:583-594
8. Doppman JL, Krudy AG, Miller DL, et al. Intra-arterial digital subtraction of spinal arteriovenous malformations. *AJNR: Am J Neuroradiol* 1983;4:1081-1085
9. Riche MC, Modenesi-Freitas J, Djindjian M, et al. Arteriovenous malformations of the spinal cord in children. *Neuroradiology* 1982;22:171-180
10. Doppman JL. The nidus concept of spinal cord arteriovenous malformations: a surgical recommendation based upon angiographic observations. *Br J Radiol* 1971;44:758-763
11. Browne TR, Adams RD, Robeson GH, et al. Hemangioblastoma of spinal cord. *Arch Neurol* 1976;33:435-441

12. Djindjian R, Merland JJ, Djindjian M, et al. *Angiography of the spinal column and spinal cord tumors*. New York: Georg Thieme Verlag, 1981:8-11
13. Huk W, Klinger M. The diagnosis of cervical spine angioblastomas. *Neuroradiology* 1973;5:174-177
14. Kamano S, Rukushina T. Angiography demonstration of vertebral osteoid osteoma. *Surg Neurol* 1976;6:167-168
15. Hilal SK, Keim HA. Selective spinal angiography in adolescent scoliosis. *Radiology* 1972;103:349-359
16. Doppman JL, DiChiro G, Morton DL, et al. Arteriographic identification of spinal cord blood supply prior to aortic surgery. *JAMA* 1968;204:174-175
17. Forbes G, Nichols DA, Jack CR Jr, et al. Complications of spinal cord arteriography: prospective assessment of risk for diagnostic procedures. *Radiology* 1988;169:479-484
18. Fergelson HH, Ravin HA. Transverse myelitis following selective bronchial arteriography. *Radiology* 1965;85:663-665
19. Killen DA, Foster JH. Spinal cord injury as a complication of contrast angiography. *Surgery* 1966;59:969-981
20. DiChiro G. Unintentional spinal cord arteriography: a warning. *Radiology* 1974;112:231-233
21. Kardjiev V, Symeonov A, Chankov I, et al. Etiology, pathogenesis and prevention of spinal cord lesions in selective angiography of the bronchial and intercostal arteries. *Neuroradiology* 1974;112:81-83
22. Gargour GW, Wener L, DiChiro G, et al. Selective arteriography of the spinal cord in posttraumatic paraplegia. *Neurology* 1972;22:131-134
23. Bussat P, Rossier AB, Djindjian R, et al. Spinal cord angiography in dorsolumbar vertebral fractures with neurological involvement. *Radiology* 1973;109:617-620
24. Gage EL, Shim NK, Ransohoff J. Anterior approach to acute and chronic thoracolumbar spinal cord decompression. In: *Proceedings of the 17th veterans administration spinal cord injury conference*. Washington, DC: US Government Printing Office, 1971:45-50