

---

# Cerebral Amyloid Angiopathy Presenting as a Brain Mass

Alan K. Osumi, Robert D. Tien, Gary J. Felsberg, and Mark Rosenbloom

**Summary:** The MR images of a patient with cerebral amyloid angiopathy (a localized vascular deposition of amyloid without evidence of systemic amyloidosis) showed an extensive right temporoparietal lobe mass with frontal lobe extension that was slightly hypointense on T1-weighted images and heterogeneously hyperintense on T2-weighted images. No contrast enhancement was identified on MR imaging.

**Index terms:** Amyloidosis; Arteries, cerebral; Arteries, diseases

Primary intracranial deposition of amyloid is usually seen within neuritic plaques and blood vessel walls without the presence of systemic amyloidosis (1, 2). The deposition of amyloid within the cerebral and meningeal blood vessels walls is called *cerebral amyloid angiopathy* or *congophilic angiopathy* (3). The usual neurologic presentation of cerebral amyloid angiopathy is a spontaneous cerebral hemorrhage occurring in an elderly patient with normal blood pressure (4–12). Cerebral amyloid angiopathy presenting as a mass in the brain without the evidence of hemorrhage is unusual (13–16). A case of cerebral amyloid angiopathy is presented with both computed tomographic (CT) and magnetic resonance (MR) findings.

## Case Report

A 59-year-old black woman had a medical history of insulin-dependent diabetes mellitus and hypertension. Twenty-nine months before the current admission, the patient was evaluated for left-sided focal seizures that progressed to generalized seizures. Unenhanced CT and MR of the brain were unremarkable (Fig 1). An electroencephalogram showed focal slowing and no active seizure activity. Phenytoin therapy was instituted.

On her current admission, the patient had subacute onset of weakness and severe headaches on the left side. Admission blood pressure was 210/90 mm Hg. Brain CT showed a large, nonenhancing, nonhemorrhagic, low-attenuation mass involving the right temporal, parietal, and parietofrontal white matter with mass effect and a

1-cm right-to-left midline shift (Fig 2). The patient was immediately started on high-dose steroids. Electroencephalography showed right hemisphere slowing consistent with either a postictal state, a mass, or a vascular insult. A postcontrast MR study of the brain with gadolinium ethylenediaminetetraacetic acid showed a nonenhancing, right hemisphere mass with no apparent regions of infarction or hemorrhage (Fig 3). A diagnosis of a low-grade glioma was considered.

Cerebrospinal fluid electrophoresis showed no evidence of oligoclonal bands, and serum electrophoresis only showed hypoalbuminemia at 2.05 g/dL. The patient underwent a stereotactic biopsy. The biopsy returned reactive gliosis and was considered to be nondiagnostic. The patient then underwent a right temporal craniotomy and subtotal resection of the right temporal lobe.

Histology revealed focal deposits within vessels walls of a Congo red staining substance that produced apple green birefringence when viewed under polarized light. This finding was consistent with amyloid deposition within the vessel walls. Vascular deposition of amyloid was present mostly within the leptomeningeal and cortical vessels. No evidence of focal deposition of amyloid was seen within the white or gray matter. Diffuse gliosis and edema was identified within the white matter; however, no evidence of hemorrhage was seen. These histologic findings were diagnosed as a diffuse form of cerebral amyloid angiopathy.

After surgery, the patient remained somnolent and only followed simple commands. High-dose steroids were continued for 3 months without any change in the patient's mental status. The rectal biopsy, performed to exclude systemic amyloidosis, was normal. No evidence of systemic amyloidosis could be identified. The patient was weaned off steroids, but continued to take phenytoin for seizure activity, which occurred about once a week. The patient's physical and mental status slowly deteriorated over the next few months. She died 5 months after initial presentation.

## Discussion

Amyloid is an eosinophilic, insoluble, extracellular protein that was described by Virchow

---

Received February 1, 1993; accepted after revision November 2.

From the Section of Neuroradiology, Department of Radiology, Duke University Medical Center, Durham, NC (A.K.O., R.D.T., G.J.F.), and Department of Pathology, New York Hospital-Cornell, New York, NY (M.R.).

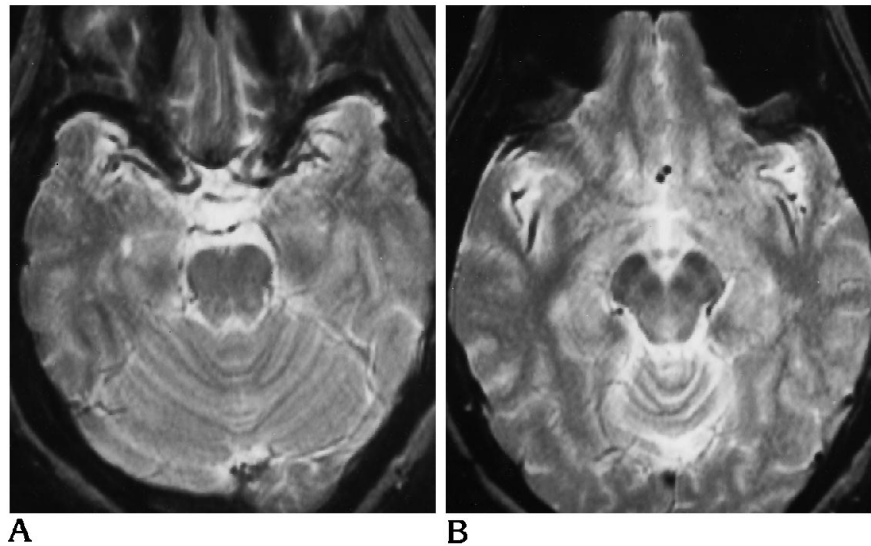
Address reprint requests to Robert D. Tien, MD, Box 3808, Department of Radiology, Duke University Medical Center, Durham, NC 27710.

AJNR 16:911–915, Apr 1995 0195-6108/95/1604–0911 © American Society of Neuroradiology

Fig 1. Axial T2-weighted MR images (2800/80/0.75 [repetition time/echo time/excitations]) obtained at the time of initial presentation with partial complex seizures involving the right temporal lobe.

A, No abnormal signal is identified within the right temporal white matter.

B, Cephalad image shows no abnormal signal in the right temporoparietal white matter.



(17). It stains with Congo red and characteristically produces a pathognomonic apple green birefringence under polarized light (18). Electron microscopy shows that amyloid is composed of nonbranching protein fibrils of indeterminate length, but consistently has a diameter

between 7.5 and 10 nm (19). These fibrils are arranged in crossed beta pleated sheets, as seen in x-ray diffraction (20, 21). Three parameters are used to identify amyloid in a tissue: (a) positive Congo red staining with apple green birefringence under polarized light, (b) distinct fibrillar ultrastructure on electron microscopy, and (c) crossed beta pleated sheets on x-ray diffraction (22).

Amyloid may be present as a focal deposition, or as part of a systemic disease. Systemic amyloid deposition, known as *amyloidosis*, is found in patients with gammopathies or plasma cell dyscrasias. Localized amyloid deposition occurring within the media and intima of the arteries and arterioles of the brain and meninges is known as *cerebral amyloid angiopathy*. Cerebral amyloid angiopathy seems to have slight predilection for the temporal, parietal, and occipital lobes. It principally affects the elderly and tends to increase in prevalence with advancing age (5, 23). There is no significant sex predilection (4, 8, 23). Superficial cortical hemorrhages are the most common finding. The amyloid within the vessel walls presumably leads to either their increased fragility or rupture of microaneurysms.

Cerebral amyloid angiopathy presenting as a focal, nonhemorrhagic mass (13–15) or as multifocal, nonhemorrhagic lesions (16) is rare. It is not part of systemic amyloidosis or of focal intraparenchymal amyloid deposition seen in rare cases of central nervous system amyloid-

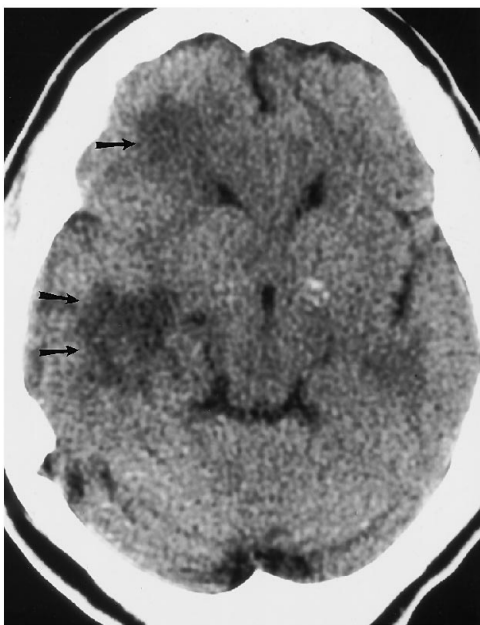


Fig 2. CT scan obtained during the most recent admission for left-sided weakness shows low-attenuation regions within the right temporoparietal and right frontal white matter (arrows). Postcontrast CT showed no enhancement of these regions (not shown).

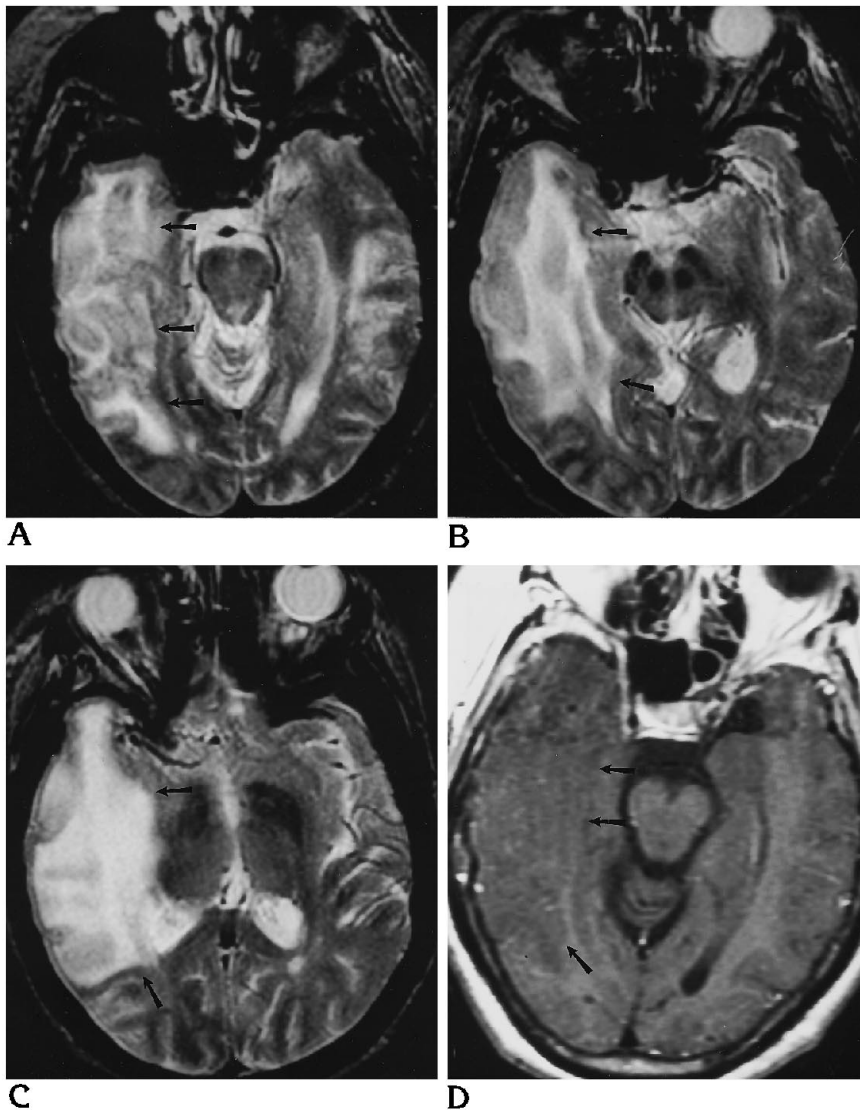


Fig 3. Axial T2-weighted MR images (2100/80) (A–C) and contrast-enhanced T1-weighted image (500/20) (D) obtained at the same time as Figure 2.

A, Abnormal high signal intensity is seen in the right temporoparietal white matter (*arrows*).

B and C, Cephalad images show a large region of involvement in the right temporoparietal lobe (*arrows*). This involvement extended to the right frontal white matter, as was seen on the CT scan (not shown).

D, Abnormal low signal intensity without enhancement is seen in the right temporoparietal white matter (*arrows*). The mass effaces the temporal horn of the right lateral ventricle.

omas (24–29). The limited follow-up in the reported cases of focal, nonhemorrhagic cerebral amyloid angiopathy ranged from 4 months to 13 years and showed no evidence of growth of the lesion or progression of the presenting neurological deficit (13–15). In these cases, the angiopathy behaved in a benign fashion, although the presenting neurologic deficit persisted.

The CT findings in our case and the other reported cases of focal cerebral amyloid angiopathy are similar (Fig 2). They showed a hypodense mass involving white matter. There was no evidence of hemorrhage or contrast enhancement. The locations of most of the

mass lesions of the focal angiopathy were the temporal, temporoparietal, and frontal lobes. A presumed diagnosis of an infiltrating glioma was made in all of the cases of focal cerebral amyloid angiopathy on the basis of CT findings.

MR imaging was performed in our case. The initial conventional T1- and T2-weighted images of the brain were normal when the patient first presented with partial complex seizures (Fig 1). Follow-up T1-weighted MR images 29 months later showed a nonenhancing, slightly hypointense mass involving the right temporoparietal and temporofrontal white matter (Fig 3). The lesion had heterogeneous high sig-

nal intensity on the T2-weighted sequences. No evidence of hemorrhage could be found on the MR images. The MR study, like the CT scan, was compatible with the presumed diagnosis of a low-grade glioma.

The current case in many ways is similar to the previously reported cases, and has two interesting aspects. The first is that the initial MR study showed no demonstrable lesion, even though the patient was symptomatic at that time with partial complex seizures. It can be speculated that the angiopathy developed from an undetected small focus in the right temporal lobe that caused the partial complex seizures into a large mass involving the entire temporoparietal white matter with extension into the frontal white matter during the 29-month period between MR studies.

The second aspect has to do with the histology of the large mass seen on the imaging studies during the latest admission for weakness on the left side. The histology of the resected brain specimen revealed edema and gliosis as the composition of the observed mass. Amyloid depositions within the vascular walls were also identified, but no hemorrhage or amyloid deposition was observed within the white or gray matter. Edema and gliosis of white matter is compatible with the observed MR and CT findings of the mass. Also the fact that no hemorrhage was identified on either CT or MR images is compatible with the observed histologic findings. Loes et al (16) and Gray et al (30) have speculated that the amyloid deposition within the vascular walls may contribute to hypoperfusion to vulnerable areas of white matter. This might account for the high T2 signal abnormality seen on the MR images of this patient and in the patients with cerebral amyloid angiopathy in the study of Loes et al (16).

In conclusion, cerebral amyloid angiopathy is a nonneoplastic, vascular wall deposition of amyloid that usually presents as a focal cortical hemorrhage in the brain, but occasionally presents as a localized mass in the brain without evidence of hemorrhage. Neuroimaging findings are limited to demonstration of a white matter mass. No contrast enhancement or hemorrhage is seen. No single imaging method allows one to distinguish a focal mass of cerebral amyloid angiopathy from other white matter masses of the brain. The differential diagnosis must include primary brain tumors like gliomas. Atypical vascular infarction and inflammatory

causes could also be considered. The clinical history should be helpful in sorting out these entities.

## References

1. Torack RM. The pathogenetic significance of congophilic angiopathy. *Med Hypotheses* 1983;11:269-276
2. Glenner GG. Amyloid deposits and amyloidosis: the beta-fibrilloses. *N Engl J Med* 1980;302:1333-1343
3. Bruni J, Bilbao JM, Pritzker KPH. Vascular amyloid in the aging central nervous system: clinico-pathological study and literature review. *Can J Neurol Sci* 1977;4:239-244
4. Okazaki H, Reagan TJ, Campbell RJ. Clinicopathologic studies of primary cerebral amyloid angiopathy. *Mayo Clin Proc* 1979;54:22-31
5. Tomonaga M. Cerebral amyloid angiopathy in the elderly. *J Am Geriatr Soc* 1981;29:151-157
6. Gilbert JJ, Vinters HV. Cerebral amyloid angiopathy: incidence and complications in the aging brain, I: cerebral hemorrhage. *Stroke* 1983;14:915-923
7. Ishii N, Nishihara Y, Horie A. Amyloid angiopathy and lobar cerebral hemorrhage. *J Neurol Neurosurg Psychiatry* 1984;47:1203-1210
8. Cosgrove GR, Leblanc R, Meagher-Villemure K, Ethier R. Cerebral amyloid angiography. *Neurology* 1985;35:625-631
9. Gilles C, Beucher JM, Khoubesserian P, Vanderhaeghen JJ. Cerebral amyloid angiopathy as a cause of multiple intracerebral hemorrhages. *Neurology* 1984;34:730-735
10. Kalyan-Raman UP, Kalyan-Raman K. Cerebral amyloid angiopathy causing intracranial hemorrhage. *Ann Neurol* 1984;16:321-329
11. Patel DV, Hier DB, Thomas CM, Hemmati M. Intracerebral hemorrhage secondary to cerebral amyloid angiopathy. *Radiology* 1984;151:397-400
12. Wagle Wa, Smith TW, Weiner M. Intracerebral hemorrhage caused by cerebral amyloid angiopathy: radiographic-pathologic correlation. *AJNR Am J Neuroradiol* 1984;5:171-176
13. Murphy MN, Sima AAF. Cerebral amyloid angiopathy associated with giant cell arteritis: a case report. *Stroke* 1985;16:514-517
14. Briceno CE, Resch L, Bernstein M. Cerebral amyloid angiopathy presenting as a mass lesion. *Stroke* 1987;18:234-239
15. Le Coz P, Mikol J, Ferrand J, et al. Granulomatous angitis and cerebral amyloid angiopathy presenting as a mass lesion. *Neuropathol Appl Neurobiol* 1991;17:149-155
16. Loes DJ, Biller J, Yuh WTC, et al. Leukoencephalopathy in cerebral amyloid angiopathy: MR imaging in four cases. *AJNR Am J Neuroradiol* 1990;11:485-488
17. Virchow R. Zur Cellulose-frage. *Virchows Arch A Pathol Anat Histopathol* 1854;8:140-144
18. Waldrop FS, Puchtler H, Valentine LS. Fluorescence microscopy of amyloid: using mixed illumination. *Arch Pathol Lab Med* 1973;95:37-41
19. Cohen AS, Shirahama T. Electron microscopic analysis of isolated amyloid fibrils from patients with primary, secondary and myeloma-associated disease: a study utilizing shadowing and negative staining techniques. *Isr J Med Sci* 1973;9:849-856
20. Eanes ED, Genner GG. X-ray diffraction studies on amyloid filaments. *J Histochem Cytochem* 1968;16:673-677
21. Bonar LC, Cohen AS, Skinner M. Characterization of the amyloid fibril as a cross-beta protein. *Proc Soc Exp Biol Med* 1969;131:1373-1375

22. Cohen AS, Connors LH. The pathogenesis and biochemistry of amyloidosis. *J Pathol* 1987;151:1-10
23. Vinters HV, Gilbert JJ. Cerebral amyloid angiopathy: incidence and complications in the aging brain, II: the distribution of amyloid vascular changes. *Stroke* 1983;14:924-928
24. Saltykow S. Zur frage des lokalen Amyloids der Hirngefasse. *Virchows Arch A Pathol Anat Histopathol* 1935;295:590
25. Spaar FW, Goebel HH, Volles E, Wickboldt J. Tumor-like amyloid formation (amyloidoma) in the brain. *J Neurol* 1981;224:171-182
26. Townsend JJ, Tomiyasu U, MacKay A, Wilson CB. Central nervous system amyloid presenting as a mass lesion. *J Neurosurg* 1982;56:439-442
27. Hori A, Kitamoto T, Tateishi J, Friede RL. Focal intracerebral accumulation of a novel type of amyloid protein. *Acta Neuropathol (Berl)* 1988;76:212-215
28. Cohen M, Lanska D, Roessmann U, et al. Amyloidoma of the CNS, I: clinical and pathologic study. *Neurology* 1992;42:2019-2023
29. Harris JH, Raypost M. Primary cerebral amyloidoma. *J Neuropathol Exp Neurol* 1979;38:318
30. Gray F, Dubas F, Roullet E, Escourolle R. Leukoencephalopathy in diffuse hemorrhagic cerebral amyloid angiopathy. *Ann Neurol* 1985;18:54-59