
Cranial Nerve Enhancement in the Guillain-Barré Syndrome

Robert K. Fulbright, Eren Erdum, Gordon Sze, and Thomas Byrne

Summary: We report a case of Guillain-Barré syndrome with enhancement of multiple cranial nerves seen with postcontrast MR imaging. Clinical symptoms and electrodiagnostic studies reflected abnormalities of some but not all of the enhancing cranial nerves.

Index terms: Nerves, cranial; Spinal cord

The Guillain-Barré syndrome is an acute, demyelinating polyneuropathy of unknown cause (1, 2). Patients present with a progressive motor neuropathy, elevated cerebrospinal fluid protein, and usually diminished motor nerve conduction on electrodiagnostic studies. Clinical involvement of cranial nerves is common, manifested as ophthalmoplegia and weakness of the facial and oropharyngeal musculature. A recent report documented bilateral facial nerve enhancement on magnetic resonance (MR) imaging (3). We report an additional case of Guillain-Barré syndrome with multiple cranial nerve enhancement seen on gadolinium-enhanced MR imaging.

Case Report

A 50-year-old woman presented with paresthesias and unilateral lower extremity weakness 1 week after a mild upper respiratory tract infection. On examination, she was afebrile, with mild right facial and lower extremity weakness. Her deep tendon reflexes were absent. Cerebrospinal fluid examination revealed a normal cell count and a protein concentration of 74 mg/dL; cultures for bacteria and fungi were negative. Chest roentgenograms, antinuclear antibodies, and Lyme titers were normal. Electrodiagnostic studies showed increased peroneal and tibial F-wave latencies and evidence of demyelination of both facial nerves proximal to the styloid-mastoid foramen, worse on the right side.

Three days into her hospital course, dysphagia developed, with progressive weakness of both sides of the face and lower extremities. On MR, enhancement after administration of gadolinium (0.1 mmol/kg) was seen in the

internal auditory canal, geniculate ganglion, and tympanic portions of the right facial nerve (Fig 1A and B); in the cisternal segments of cranial nerves six bilaterally (Fig 1C and D), and in the right cranial nerve X and XI complex within the jugular foramen (Fig 1E and F). The patient underwent plasmapheresis, with near complete resolution of symptoms by 8 weeks. A follow-up MR was not obtained.

Discussion

The Guillain-Barré syndrome is an acute polyneuropathy characterized by limb weakness and mild sensory signs (1, 2, 4, 5). In approximately two thirds of cases, a mild respiratory or gastrointestinal tract infection precedes the onset of symptoms (2). Surgical procedures, lymphoma, and systemic lupus erythematosus are other predisposing factors (2). Cerebro-spinal fluid analysis typically reveals elevated protein concentrations without pleocytosis (1, 2). Clinical involvement of cranial nerves is common (1). Facial nerves are the most frequently affected, in approximately 50% of patients; compromise of the bulbar and oculomotor nerves also can be seen (1, 2). The majority of patients recover within a few weeks to months, with maximal paralysis usually reached by 4 weeks (1, 2). Early plasmapheresis often improves clinical response (4, 5). Intensive-care monitoring allows early treatment of cardiopulmonary complications.

The cause of the Guillain-Barré syndrome is unknown, with both humoral and cellular autoimmune mechanisms implicated (6, 7). In some patients, IgM antibodies to myelin glycolipids or gangliosides have been documented (7); other patients have evidence of T-cell hypersensitivity (2). Pathologically, there is an inflammatory infiltrate of mononuclear cells that surrounds small, endoneurial vessels, and adjacent segmental demyelination (2).

Received May 17, 1993; accepted after revision July 27.

From the Departments of Radiology (R.K.F., E.E., G.S.) and Neurology and Medicine (T.B.), Yale University School of Medicine, New Haven, Conn. Address reprint requests to Robert K. Fulbright, MD, Yale University School of Medicine, 333 Cedar St, Box 3333, New Haven, CT 06510.

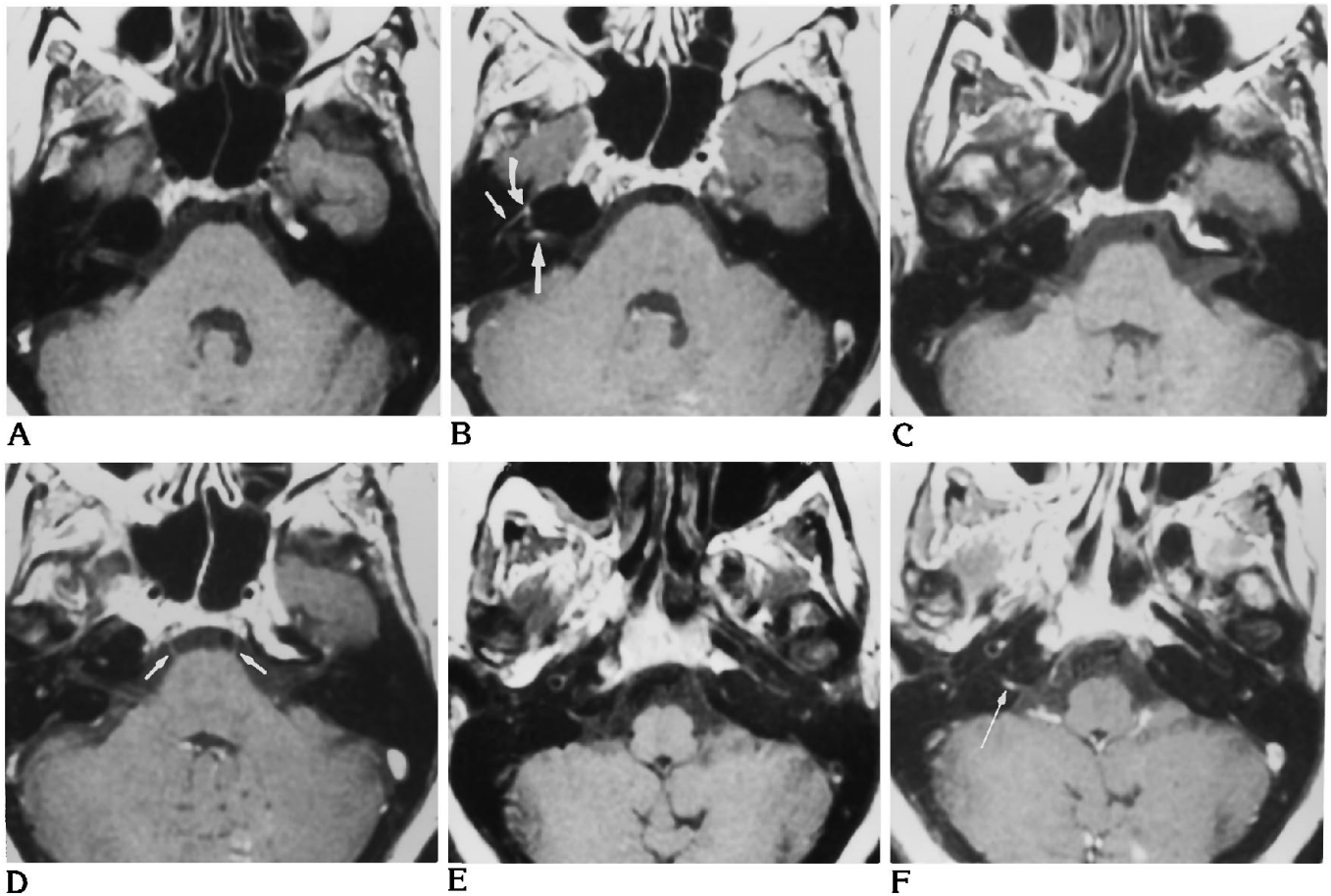


Fig 1. Cranial nerve enhancement in Guillain-Barré syndrome: Axial MR (500/20/2 [repetition time/echo time/excitations]) before (A, C, and E) and after (B, D, and F) single-dose gadolinium (0.1 mmol/kg) administration.

A and B, At level of internal auditory canal. Although enhancement of the proximal, greater superficial petrosal nerve and geniculate ganglion (*curved arrow, B*) and tympanic portions (*short, straight arrow, B*) of the facial nerve can be normal, enhancement within the internal auditory canal (*large, straight arrow, B*) indicates disease.

C and D, At level of pons. *Straight arrows* in D demonstrate enhancement of the cisternal portion of both cranial nerves 6.

E and F, At level of jugular fossa. After gadolinium administration, the cranial nerve X-XI complex enhances on the right (*arrow, F*).

The mechanism of abnormal enhancement of the cranial nerves in patients with Guillain-Barré syndrome is not entirely understood. There is evidence of a blood-peripheral nerve barrier as shown by failure of Trypan blue, a marker of an intact blood-brain barrier, to stain peripheral cranial nerves (8). Disruption of this blood-nerve barrier by the inflammatory infiltrate, analogous to enhancement in brain parenchyma after breakdown of the blood-brain barrier, therefore may cause enhancement. Alternatively, perineural structures, such as a vascular plexus enlarged from surrounding inflammation, could produce a local increase in gadolinium, and thus result in enhancement (9).

In this patient, enhancement of right cranial nerve VII and the cranial nerve X-XI complex on the right correlated with clinical findings of right

facial and oropharyngeal musculature weakness and electrodiagnostic evidence of demyelination. Electrodiagnostic studies also indicated evidence of demyelination of cranial nerve VII on the left; however, we did not see enhancement. Conversely, both sixth cranial nerves enhanced, but no clinical evidence of demyelination was found. A larger number of patients must be studied—comparing gadolinium-enhanced MR, clinical exam, and electrodiagnostic studies—to determine how accurately gadolinium enhancement indicates cranial nerve involvement in the Guillain-Barré syndrome.

In conclusion, the Guillain-Barré syndrome should be considered in the differential diagnosis of cranial nerve enhancement, which includes infections (10–16), neoplasms (primary

or secondary) (15–22), granulomatous diseases (15, 17, 23), multiple sclerosis (24), vasculitic neuropathies such as diabetes mellitus (25), and unknown causes (26).

References

- Asbury AK, Arnason BG, Karp HR, et al. Criteria for diagnosis of Guillain-Barré syndrome. *Ann Neurol* 1978;3:565–567
- Arnason BGW. Acute inflammatory demyelinating polyradiculoneuropathies. In Dyck PJ, Thomas PK, Lambert EH, et al, eds. *Peripheral Neuropathy*. Philadelphia: WB Saunders; 1984:2050–2100
- Ramsey KL, Kaseff LG. The role of MR imaging in the diagnosis of bilateral facial paralysis. *Am J Otol* (in press)
- McKhann GM. Guillain-Barré syndrome: clinical and therapeutic observations. *Ann Neurol* 1990;27(suppl):s13
- Guillain-Barré Syndrome Study Group. Plasmapheresis and acute Guillain-Barré syndrome. *Neurology* 1985;35:1096–1104
- McFarlin DE. Immunological parameters in Guillain-Barré syndrome. *Ann Neurol* 1990;27(suppl):s25–s29
- Koski CL, Chou DKH, Jungalwala FB. Anti-peripheral nerve myelin antibodies in Guillain-Barré syndrome bind a neutral glycolipid of peripheral nerve myelin and cross-react with Forssman antigen. *J Clin Invest* 1989;84:280–287
- Bradbury MWB. *The Concept of the Blood-Brain Barrier*. New York: Wiley and Sons, 1979:127–136
- Gebarski SS, Telian SA, Niparko JK. Enhancement along the normal facial nerve in the facial canal: MR imaging and anatomic correlation. *Radiology* 1992;183:391–394
- Chang KH, Han MH, Roh JK, Kim IO, Han MC, Kim C-W. Gd-DTPA-enhanced MR imaging of the brain in patients with meningitis: comparison with CT. *AJNR Am J Neuroradiol* 1990;11:69–76
- Tien RD, Dillon WP. Herpes trigeminal neuritis and rhombencephalitis on Gd-DTPA-enhanced MR imaging. *AJNR Am J Neuroradiol* 1990;11:413–414
- Rafto SE, Milton WJ, Galetta SL, Grossman RI. Biopsy-confirmed CNS Lyme disease: MR appearance at 1.5 T. *AJNR Am J Neuroradiol* 1990;11:482–484
- Seltzer S, Mark AS. Contrast enhancement of the labyrinth on MR scans in patients with sudden hearing loss and vertigo: evidence of labyrinthine disease. *AJNR Am J Neuroradiol* 1991;12:13–16
- Tien RD, Gean-Marton AD, Mark AS. Neurosyphilis in HIV carriers: MR finding in six patients. *AJR Am J Roentgenol* 1992;158:1325–1328
- Phillips ME, Ryals TJ, Kambhu SA, Yuh WTC. Neoplastic vs inflammatory meningeal enhancement with Gd-DTPA. *J Comput Assist Tomogr* 1990;14(4):536–541
- Tien R, Dillon WP, Jackler RK. Contrast-enhanced MR imaging of the facial nerve in 11 patients with Bell's palsy. *AJNR Am J Neuroradiol* 1990;11:735–741
- Sze G, Soletsky S, Bronen R, Krol G. MR imaging of the cranial meninges with emphasis on contrast enhancement and meningeal carcinomatosis. *AJNR Am J Neuroradiol* 1989;10:765–975
- Yousem DM, Patrone PM, Grossman RI. Leptomeningeal metastases: MR evaluation. *J Comput Assist Tomogr* 1990;14(2):255–261
- Rippe DJ, Boyko OB, Friedman HS, et al. Gd-DTPA-enhanced MR imaging of leptomeningeal spread of primary intracranial CNS tumor in children. *AJNR Am J Neuroradiol* 1990;11:329–332
- Hendrix LE, Kneeland JB, Haughton VM, et al. MR imaging of optic nerve lesions: value of gadopentetate dimeglumine and fat-suppression technique. *AJNR Am J Neuroradiol* 1990;11:749–754
- Hudgins PA, Davis PC, Hoffman, Jr JC. Gadopentetate dimeglumine-enhanced MR imaging in children following surgery for brain tumor: spectrum of meningeal findings. *AJNR Am J Neuroradiol* 1991;12:301–307
- Yuh WTC, Mayr-Yuh NA, Koci TM, et al. Metastatic lesions involving the cerebellopontine angle. *AJNR Am J Neuroradiol* 1993;14:99–106
- Sherman JL, Stern BJ. Sarcoidosis of the CNS: comparison of unenhanced and enhanced MR images. *AJNR Am J Neuroradiol* 1990;11:915–923
- Merandi SF, Kudryk BT, Murtagh FR, Arrington JA. Contrast-enhanced MR imaging of optic nerve lesions in patients with acute optic neuritis. *AJNR Am J Neuroradiol* 1991;12:923–926
- Depper MH, Truwit CL, Dreisbach JN, Kelly WM. Isolated abducens nerve palsy: MR imaging findings. *AJR Am J Roentgenol* 1993;160:837–841
- Martin N, Masson C, Henin D, Mompoin D, Marsault C, Nahum H. Hypertrophic cranial pachymeningitis: assessment with CT and MR imaging. *AJNR Am J Neuroradiol* 1989;10:477–484