

Metastatic Hypernephroma to the Head and Neck

Peter M. Som^{1,2}
 Karen I. Norton¹
 Joel M. A. Shugar²
 Deborah L. Reede³
 Larry Norton⁴
 Hugh F. Biller²
 Max L. Som²

Eight cases of metastatic hypernephroma to the head and neck are presented with CT documentation. Hypernephroma is the third most common infraclavicular tumor to metastasize to the head and neck. Such metastases occur in about 15% of patients with this neoplasm, and nearly 8% of patients with this tumor present with disease in the head and neck region. These metastases are usually vascular and may either clinically precede the diagnosis of the renal primary tumor or may occur many years after apparently successful surgery of the primary tumor. These unusual patterns of behavior are reviewed.

One of the cases presented here is the first reported incidence of cervical lymph node metastasis with hemorrhage to be documented by CT, thus adding this entity to the list of imaging differential diagnoses of cystic-appearing neck masses.

Of all the primary tumors that arise below the level of the clavicles, hypernephromas, overall, are the third most common neoplasm to metastasize to the head and neck region [1-3]. In this regard, only breast and lung carcinomas are more common. Hypernephromas are the tumors most likely to metastasize to the paranasal sinuses, nasal cavity, larynx, and skin; the second most common neoplasm to metastasize to the jaws and temporal bones, and the third most common tumor to metastasize to the parotid and thyroid glands [1-3]. By comparison to these prevalent areas, only three cases of metastatic hypernephroma to cervical lymph nodes have been previously reported in the English radiologic literature [4, 5].

This paper presents eight cases of pathologically proved metastatic hypernephromas to the head and neck and discusses the CT appearance and unusual clinical behavior of this tumor.

Materials and Methods

The charts were reviewed of all patients seen at our hospital who had a diagnosis of hypernephroma with biopsy proved and CT documented metastases to the head and neck region. Since 1975, eight such patients were found.

Because of the 11-year period covered in this paper, the CT scans were performed on several different-generation CT units, including Delta 50, Pfizer S200, GE 8800, and GE 9800 scanners. All patients were studied in the inferior-orbital-meatal plane with 5-mm thick, contiguous scans. The sinus studies extended from the top of the frontal sinuses to the maxillary teeth. Coronal scans were performed as needed. The neck examinations were performed from the level of the external auditory canal to the level of the manubrium. IV contrast was given as a drip of Conray (600 mg/ml, 150 ml) occasionally preceded by a 20-ml bolus injection of Hypaque 50.

Results

Of the eight patients studied, four had only one site of metastatic disease;

Received March 24, 1987; accepted after revision June 15, 1987.

¹ Department of Radiology, The Mount Sinai Hospital, One Gustave Levy Place, New York, NY 10029. Address reprint requests to P. M. Som.

² Department of Otolaryngology, The Mount Sinai Hospital, New York, NY 10029.

³ Department of Radiology, New York University Medical School, New York, NY 10016.

⁴ Department of Neoplastic Diseases, The Mount Sinai Medical Hospital, New York, NY 10029.

AJNR 8:1103-1106, November/December 1987
 0195-6108/87/0806-1103

© American Society of Neuroradiology

namely, scalp (1), cervical lymph node (1), and maxillary sinus (2). Three patients had two adjacent sites of metastases; namely, frontal and ethmoid sinuses (1), and central skull base and sphenoid sinuses (2). One patient had three separate sites of metastases; namely, maxillary sinus, parotid gland, and thyroid gland. No pulmonary metastases were found in any of these patients. The temporal relationship of these metastases to the diagnosis of the primary renal tumor, the sites of metastases, the treatment, and the present patient status are summarized in Table 1.

The unifying CT appearance in all these cases was the presence of an enhancing, soft-tissue mass on postcontrast studies. In the paranasal sinuses, the mass appeared bulky and partially expansile [6, 7] (Figs. 1 and 2). When angiography was performed (three patients), a highly vascular lesion

was demonstrated (Fig. 2B). The central skull-base lesions were highly destructive while any extension into the nasal vault or paranasal sinuses also exhibited an expansile quality (Fig. 3). The forehead metastases consisted of an enhancing subcutaneous nodule with localized subjacent erosion of the outer frontal bone cortex.

The scan of the case of the metastasis to the thyroid is from an older-generation CT scanner and was a noncontrast study because of the patient's allergy to iodinated contrast agents. This scan revealed a nonspecific, diffuse enlargement of the left lobe of the thyroid gland with a loss of the normal thyroid iodine content in the involved region (Fig. 4). The lymph-node metastasis appeared as a thick, irregularly walled cystic mass with a minimally enhancing or dense surrounding reaction that effaced the adjacent tissue planes (Fig. 5).

TABLE 1: Eight Hypernephroma Patients in Study

Patient No.	Age at Diagnosis of Renal Tumor	Time of Appearance of Metastasis Relative to Renal Tumor	Location of Metastasis	Treatment	Present Clinical Status
1	42	-11 years +10 years +11 years	Parotid Maxillary sinus Thyroid	Surgery Surgery Surgery	DOD
2	60	+6 years	Maxillary sinus	Surgery	Alive; NED
3	65	+5 years	Skull base Sphenoid sinus	Radiation therapy	DOD
4	70	+4 years	Skull base Sphenoid sinus	Radiation therapy	DOD
5	57	+8 years	Scalp	Surgery	Alive; NED
6	46	+12 years	Frontal and ethmoid sinuses	Surgery	Alive; NED
7	49	+10 years	Cervical lymph node	Surgery	Alive with disease
8	41	Presenting finding of renal tumor	Maxillary sinus	Surgery	Alive; NED

Note.—DOD = died of disease; NED = no evidence of disease.

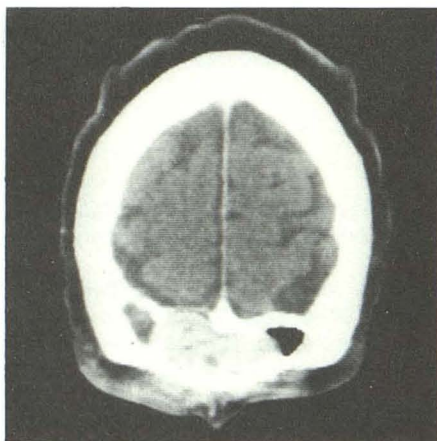
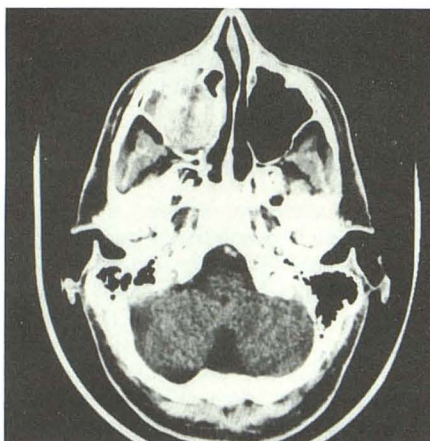
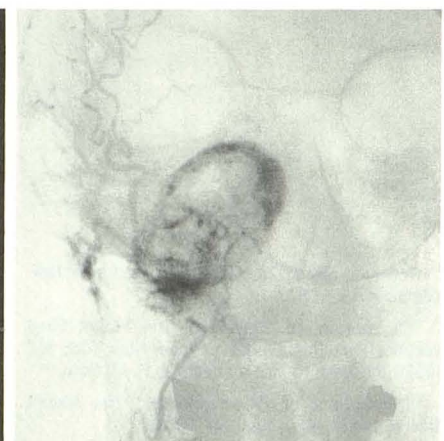
Fig. 1.—Patient 6. Coronal postcontrast CT scan shows enhancing, partially expansile and partially destructive frontal sinus mass.



A



B

Fig. 2.—Patient 2.
A, Axial postcontrast CT scan reveals enhancing expansile right antral mass.
B, Frontal subtraction angiogram reveals vascular nature of right antral mass.

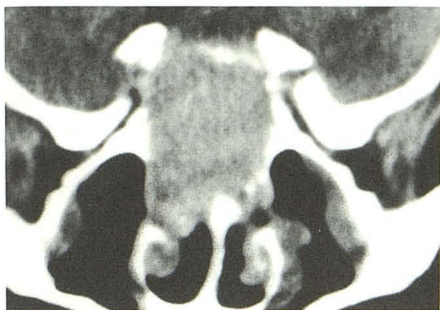

Fig. 3.—Patient 3. Coronal postcontrast CT scan shows enhancing destructive lesion of central skull base, sphenoid sinus, and posterior nasal vault. This is a representative scan of the cases of central skull-base metastasis. The enhancement can be appreciated by comparison to the attenuation of the brain.

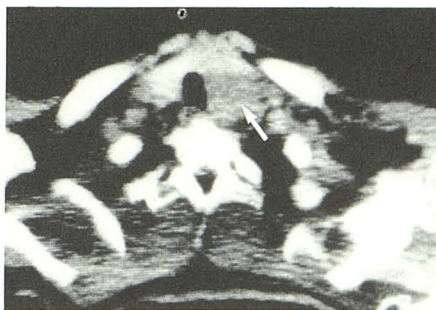

Fig. 4.—Patient 1. Axial noncontrast CT scan shows left thyroid lobe and a portion of the isthmus to be enlarged (arrow) with decreased attenuation compared with normal-appearing right thyroid lobe. There is no invasion of the trachea, and surrounding tissue planes are well maintained.

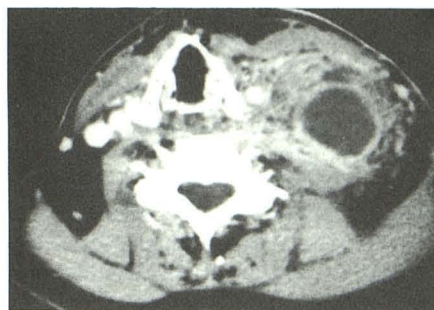


Fig. 5.—Patient 7. Axial postcontrast CT scan shows thick-walled cystic mass in left neck. Surrounding soft-tissue planes are partially effaced but not infiltrated in the dense manner associated with most tumor spread. Overlying skin and subcutaneous tissues are normal.

Discussion

Only the statistically more prevalent carcinomas of the breast and lung can vie with hypernephroma in the number of metastases that occur to the head and neck region. It is estimated that between 14–16% of patients with hypernephroma have such metastases above the clavicles, and in almost 8% of patients the presenting clinical manifestation of the tumor is disease in the head and neck [4, 5].

The explanation for this apparent propensity for metastasis to this region remains somewhat unclear. It has been previously noted that the clinical behavior of hypernephroma is often unpredictable in its rate of growth, in the timing of metastases, and in the variability of the patterns of metastatic spread [1–5, 8]. Some hypernephromas have been reported to regress spontaneously while others demonstrate metastasis many years after a “curative” resection of the renal lesion [1–5]. Apparently, some of these tumors have the ability to bypass the pulmonary capillary filtration mechanism and metastasize directly to the head and neck. The most reasonable explanation for this phenomenon appears to be tumor embolization via Batson’s plexus of extensive anastomoses between the avascular vertebral and epidural venous systems [4]. Once tumor emboli reach the head and neck they can anastomose with the great veins of the head and spread to the sinonasal cavities, cutaneous sites, and thyroid gland. Possibly because of these venous routes, hypernephroma is the third most common primary tumor to metastasize to the thyroid gland, but the thyroid is the most common site of metastasis for this tumor in the head and neck [5]. No explanation appears in the literature as to why some tumors preferentially metastasize via Batson’s plexus while other lesions extend primarily into the renal vein and inferior vena cava.

The vascular stroma of these metastases accounts for the fact that the most common symptom of these sinonasal lesions is epistaxis (70%) [2]. The extensive hemorrhage in the metastasis to the cervical lymph node and the enhancement of most of these metastases on postcontrast CT scans

are also attributable to this vascularity. However, the vascular nature of these metastases is not always clinically evident, and in these instances it is usually the history of a prior renal tumor that suggests the true origin of the head and neck mass.

In general, the diagnosis of a metastatic renal tumor is not prospectively established in the absence of a second lesion. It is usually the pathology that initially suggests the possibility of a metastasis, although in some cases, the pathology can be in error and misleading. In fact, if the possibility of metastasis is not suggested to the pathologist, confusion with primary tumors may occur. This is nowhere more evident than in the parotid gland, where confusion with oncocytomas, acinous cell carcinomas, and clear-cell neoplasms has been reported [9]. Differentiation of a true clear-cell carcinoma and a metastatic hypernephroma must ultimately depend on the clinical exclusion of a primary renal tumor. Histochemical and electron microscopic differences have failed to provide conclusive criteria [9]. This confusion was demonstrated in patient 1, whose initial metastatic parotid lesion was misinterpreted as an acinous carcinoma of the parotid gland.

Three patients require special comment. The first is patient 1, who had serial metastases over a 22-year period starting with a parotid lesion that appeared 11 years before the diagnosis of the renal primary, then metastases to the paranasal sinuses and thyroid gland. Each of these metastases was surgically extirpated, a therapeutic approach consistent with the observation that surgical removal of such metastases is often associated with good clinical results [1, 4]. The second case to note is patient 7, who had renal cell carcinoma metastasis to a cervical lymph node. This case represents only the fourth recorded incidence of cervical nodal spread and the first CT-documented case to have hemorrhage within this node as the cause of an enlarging neck mass. The third case is patient 8, who presented with epistaxis and no history or clinical or laboratory evidence of a primary renal tumor. The nasal mass bled profusely on biopsy. This led to an angiogram, which revealed a highly vascular antral lesion.

While the patient was on the angiography table, the upper abdomen was intentionally examined under fluoroscopy and found to contain a vascular renal mass.

In general, the CT appearance is nonspecific and the imager can only suggest the diagnosis in a list of differential diagnoses. The renal metastases to the sinonasal cavities have a similar CT appearance to that of melanomas, extramedullary plasmacytomas, esthesioneuroblastomas, meningiomas, other vascular metastases (i.e., thyroid, adrenal), lymphomas, and large tumors that spread to involve the sinuses (i.e., nasopharyngeal carcinomas, glomus jugulare tumors, and chordomas). Of these, the melanomas, extramedullary plasmacytomas, meningiomas, glomus tumors, and other vascular metastases will all be highly vascular on angiography. The final diagnosis usually depends on the pathology and not just the CT and angiographic appearances. The enhancement, destruction, and lack of tumoral calcification should at least suggest metastatic hypernephroma as part of this differential diagnosis. The soft-tissue forehead lesion was nonspecific in appearance. Similar CT findings have been observed with lymphoma and granulomatous diseases. The nodal mass had the nonspecific CT appearance of a slightly irregularly walled cystic mass, which suggested a malignancy. The minimally enhancing or dense reaction incited in the surrounding soft tissues, in the absence of the CT changes of cellulitis in the overlying subcutaneous tissues, is unusual for infection and abscess and supports the contention that the malignant process has extended from the central cystic mass. However, the normal infiltrative appearance of extranodal disease was not present in this case and thus an

unusual nodal and extranodal malignant process should be diagnosed.

Hypernephroma metastases most often go to the lungs, bones, liver, and adrenal glands [5]. However, they can metastasize directly to the head and neck region and produce masses that may simulate primary tumors. If the possibility of such metastases is not even considered, the true nature of these lesions may go undiagnosed. This reflects the fact that these metastases to the head and neck may precede the clinical detection of the primary renal tumor.

REFERENCES

1. Batsakis JG. *Tumors of the head and neck: Clinical and pathological considerations*, 2nd ed. Baltimore: Williams & Wilkins, 1979:240-251
2. Bernstein JM, Montgomery WW, Balogh K Jr. Metastatic tumors to the maxilla, nose, and paranasal sinuses. *Laryngoscope* 1986;76:621-650
3. Nahum AM, Bailey BJ. Malignant tumors metastatic to the paranasal sinuses: Case report and review of the literature. *Laryngoscope* 1963;73:942-953
4. Boles R, Cerny J. Head and neck metastases from renal carcinomas. *Mich Med* 1971;70:616-618
5. Miyamoto R, Helmus C. Hypernephroma metastatic to the head and neck. *Laryngoscope* 1973;83:898-905
6. Hayes E, Weber AL, Davis KR, Arrigg FG Jr. Metastatic renal cell carcinoma manifesting as a nasal mass: CT findings. *J Computer Assist Tomogr* 1985;9:387-389
7. Som PM. The paranasal sinuses. In: Bergeron RT, Osborn AG, Som PM, eds. *Head and neck imaging excluding the brain*. St. Louis: Mosby, 1984:1-142
8. Schantz JC, Miller SH, Graham WP III. Metastatic hypernephroma to the head and neck. *J Surg Oncol* 1976;8:183-190
9. Connor DH, Taylor HB, Helwig EB. Cutaneous metastasis of renal cell carcinoma. *Arch Pathol* 1963;76:339-346