

# Color-Flow Doppler Sonography in the Identification of Ulcerative Plaques in Patients with High-Grade Carotid Artery Stenosis

Heinrich Fürst,<sup>1,3</sup> Wolfgang H. Hartl,<sup>1</sup> Ingrid Jansen,<sup>1</sup> Dieter Liepsch,<sup>2</sup> Lutz Lauterjung,<sup>1</sup> and Friedrich W. Schildberg,<sup>1</sup>

**PURPOSE:** To assess the ability of color-flow Doppler sonography (CFDS) to detect plaque ulcerations in patients who had high-grade to thread-like carotid artery stenosis and who underwent carotid endarterectomy. **METHODS:** CFDS is a noninvasive diagnostic technique that allows, in addition to spatial visualization of blood flow, the identification of abnormal blood flow patterns such as vortex formation. There is evidence that pathologic anatomic changes in the vascular wall (such as ulcerations) may result in characteristic hemodynamic alterations. Therefore, solely hemodynamic criteria (detection of vortices) were used to diagnose ulceration. The results of preoperative examinations were compared to the intraoperative findings in 89 patients in a prospective and blinded way. **RESULTS:** CFDS proved highly sensitive (95.3%), specific (93.5%), and accurate (94.0%) for demonstrating ulcerative plaques. **CONCLUSION:** CFDS may be of significant advantage for examining plaque morphology in patients who have high-grade internal carotid artery stenosis, and in whom accurate, noninvasive diagnosis of plaque ulceration was previously difficult, if not impossible.

**Index terms:** Ultrasound, Doppler; Arteries, stenosis and occlusion; Arteries, carotid; Arteries, ultrasound

AJNR 13:1581-1587, Nov/Dec 1992

In contrast to symptomatic patients, there is an ongoing controversy regarding the proper treatment of patients who present with carotid artery stenosis, but who are asymptomatic at the time of diagnosis, even if the stenosis is high-grade or threadlike (1–3). In theory, the patients who will profit from treatment are those at risk either for thromboembolic stroke or for cerebral ischemia of hemodynamic cause (4). A major problem lies in the correct identification of patients who bear specific risk factors. Hemodynamically significant carotid artery stenosis may now be detected in patients by examination of intracerebral hemodynamics (5), whereas there

are no techniques available to identify, with certainty, patients who are at risk for thromboembolic stroke. Several factors contribute to the latter dilemma. Thus far, the natural course of atheromatous carotid plaque is unknown, and the reasons plaque becomes symptomatic are multifactorial and not well defined, due to the lack of controlled prospective studies in symptomatic and asymptomatic patients (6). There is conflicting evidence concerning the role of intraplaque hemorrhage, as well as of plaque ulceration in the pathogenesis of carotid artery stroke (6–8).

Until recently, morphologic changes in the carotid artery wall could not be detected with acceptable accuracy. However, the refinement of Duplex sonography now allows reliable, noninvasive detection of intraplaque hemorrhage (9, 10). Still, in terms of morphologic criteria, neither sonography nor arteriography is currently sensitive enough to properly identify plaque ulceration, especially in patients with high-grade carotid artery stenosis (11, 12).

The recent introduction of a far more advanced sonographic technology—color flow Doppler sonography (CFDS)—may offer new possibilities in the noninvasive diagnosis of atheromatous ca-

---

Received August 12, 1991; accepted and revision requested October 30; revision received March 12, 1992.

Previously published in abstract form as preliminary report: Color flow imaging of the internal carotid artery. *Circulation* 1989;8(suppl II):564.

<sup>1</sup> Department of Surgery, Klinikum Grosshadern, Ludwig-Maximilians University School of Medicine, Munich, Germany.

<sup>2</sup> Laboratory of Fluid Mechanics, Fachhochschule Munich, Germany.

<sup>3</sup> Address reprint requests to Heinrich Fürst, MD, Department of Surgery, Klinikum Grosshadern, Marchioninstr. 15, D 8000 Munich 70, FR Germany.

AJNR 13:1581–1587, Nov/Dec 1992 0195-6108/92/1305-1581

© American Society of Neuroradiology



rotid artery plaques. Besides allowing spatial imaging of flow velocities, this technology provides sophisticated analysis of intravascular hemodynamics, such as the identification of disturbed flow (13). Thus, we used the finding that gross anatomic changes in the vascular wall result in characteristic hemodynamic alterations (14) to investigate, in the current study, the value of CFDS in identifying plaque ulceration by hemodynamic criteria only.

## Materials and Methods

From July 1989 to July 1990, 89 patients (age  $63 \pm 5$  years (mean  $\pm$  SEM)) with symptomatic or asymptomatic, unilateral or bilateral high-grade or threadlike stenosis (80%–99%) of the internal carotid artery (ICA) were studied before carotid endarterectomy. Patients who present with this degree of carotid artery disease are currently considered for surgical treatment in our institution; ICA stenosis was preoperatively diagnosed by conventional continuous-wave Doppler sonography. The latter procedure has a 95% sensitivity for diagnosis of ICA stenosis in our institution (15). Simultaneously, our patients underwent CFDS examination of the stenosed ICA. Although the majority of patients underwent angiography, we did not analyze angiograms for the presence of an ulceration in a standardized and reproducible way, since several previous studies documented the insensitivity of angiography in detecting ulceration (11, 12). This fact was just confirmed by the NASCET study (2). At surgery, the endarterectomy specimen was examined by independent surgeons, to allow description of the plaque's gross morphologic characteristics. The intraoperative findings were then compared to the preoperative diagnosis.

Thirty-seven patients were asymptomatic and 52 patients were symptomatic relative to the ipsilateral hemisphere, and they were suffering from various degrees of neurologic deficits, which ranged from reversible to mild permanent symptoms (minor stroke). None of the study subjects had a severe, permanent neurologic deficit (major stroke).

### *Theory of CFDS*

All examinations were performed with a 7.5 or 5.0 MHz annular array transducer and a CFDS device (Vingmed CFM 700, Trondheim, Norway). This device allows one to do almost simultaneous conventional Doppler measurements and imaging by the missing signal estimator technique (13). Thereby, information about flow velocity, spatial distribution, and behavior of flow in the studied vessel can be obtained simultaneously. Usually, during imaging, targets moving toward the transducer are assigned a red color, and targets moving away from it, a blue color. However, if the speed of the targets surmounts a certain value (which corresponds to the frequency reaching the Nyquist limit), then coloration of the targets will change

from red to blue or vice versa, depending on color definition of the baseline flow (aliasing phenomenon). Nyquist limit indicates the maximum frequency that can be measured accurately by CFDS, and it depends on the selected insonation depth and, therefore, on the maximum pulse repetition frequency. Precisely, the Nyquist limit is defined as half of the maximum pulse repetition frequency. No correction factor for different insonation angles was applied when frequency was calculated. However, during all examinations, the frequency of the probe and the resulting insonation depth was selected in a way that the Nyquist limit always corresponded to a velocity of 0.5 m/sec; also, gain and color scales were kept constant during all examinations.

Furthermore, imaging allows estimation of disturbed flow, which appears green/white in the image, and is identified by digital analysis of mean frequency, bandwidth, and intensity of Doppler signals returning from a defined range cell. The range cell represents a constant sample volume whose size is determined transversely by the width of the beam and radially by the pulse length. Disturbed flow is characterized by a fairly high intensity of Doppler signals (indicating a high density of red cells in the examined range cell) and by a wide bandwidth signal (indicating a large difference between maximum and minimum flow velocity in the range cell). In this situation, the mean frequency in the range cell fluctuates around zero in areas with disturbed flow. Disturbed flow is either caused by high velocity turbulent flow or by the formation of vortices in the blood stream. Range cells exhibiting a narrow bandwidth signal (indicating only small variations in flow velocity) and a mean frequency approaching zero represent areas in which the blood flow is multidirectional and random, and appear black in the image.

### *Technique of CFDS Examination*

All CFDS examinations were performed by two of the authors. One examiner evaluated 50 patients, the other 39. Since the expertise of the examiner is a primary determinant for accuracy of Doppler tests (16), over 500 patients were studied by CFDS before the prospective evaluation was begun.

At the beginning of the examination, degree, localization, and length of the stenosis were identified by conventional continuous-wave Doppler sonography. Then the stenosis was examined by CFDS to identify stenosis-associated, disturbed flow. Each examination consisted of longitudinal views of the common carotid artery, the carotid bifurcation, and the internal and external carotid artery. Special care was applied during examination of the stenosis. Views from the prestenotic, stenotic, and post-stenotic regions were obtained from a variety of directions, ranging from anterior to posterolateral. The stenosis was identified, using CFDS, by observation of the jet phenomenon (sudden changes of color), which indicates intra- and post-stenotic flow acceleration (flow velocity surmounting the Nyquist limit). Then the stenosis was carefully screened for regions with green/white coloration (disturbed flow) and with black



coloration. Special attention was paid to the presence or absence of these colored regions at systole and diastole. Only longitudinal views were performed since they are by far more sensitive with regard to the recognition of specific flow phenomena. Since longitudinal views allow the examination of the stenosed vessel over its whole length in one image (and in the direction of flow), it is much easier to detect specific spatial flow phenomena, such as the characteristic concentric arrangement of laminar, disturbed, and irregular flow. Such an arrangement is typical for a vortex (see below). In transverse images, a clear spatial resolution of different flow qualities is rarely seen. This fact results mainly from the relatively smaller area of regions with different coloration. These smaller areas make it difficult to visualize and to analyze coherent color phenomena.

All examinations were stored off line on a personal computer (Macintosh II, Apple, Munich, Germany). Subsequently, the stored digital images were reviewed on the computer using a special software package (Echobase, Vingmed, Norway). The latter allows visualization of the examination frame by frame and simultaneous analysis, in a defined area, of flow velocities (frequencies) that were obtained by conventional Doppler measurements. Since analysis of disturbed flow and regular Doppler measurements are done both simultaneously and independently, one can identify disturbed flow by the optical appearance in the image (green color) and by the analysis of velocity profiles in adjacent areas.

The identification of vortices in the blood stream was based on their hemodynamic characteristics at systole (maximum blood flow velocity). In their peripheral parts, vortices show a zone of disturbed flow that is combined with an area of high velocity laminar flow and a zone of irregular flow in the center. In the latter zone, flow velocities demonstrate a narrow bandwidth and a random variation with reference to temporal and spatial coordinates, thereby leading to a mean flow velocity of zero. All these hemodynamic changes can be recognized by CFDS.

Consequently, plaque ulceration was diagnosed when, at systole, a circular band of high-velocity blood flow in association with a black coloration in the center was found. High-velocity blood flow usually presented as a mixture of laminar flow (blue or red coloration) and disturbed flow (green/white coloration). This typical spatial arrangement of different colors allowed the identification of vortices. At lower blood flow velocities (diastolic flow) the typical spatial arrangement of the colors usually disappeared. If an ulceration had been identified, special attention was then paid to the location of the ulcer. Whether the ulceration was localized at the internal carotid artery or at the bifurcation was recorded. Furthermore, we estimated the approximate distance of the ulceration to the carotid bifurcation, if an ulceration was found in the internal carotid artery.

#### *Intraoperative Examination*

All patients were operated on either by the chief resident or by the attending of the vascular surgery service. Intra-

operative evaluation of the stenosis was performed in an independent, blinded fashion by the operating surgeon. At the beginning of the procedure, the region of the stenosis was incised longitudinally. Then, the surgeon carefully examined the stenosis over its whole length. The gross morphologic characteristics of the stenosing plaque were examined in situ immediately after arteriotomy and before further surgical manipulation, as recommended (8). Ulceration was defined as a grossly observable disruption of the intima (more than 2 mm in diameter), thereby exposing the subjacent atheromatous plaque or media. This disruption was distinguished from plaques with macroscopic pitting and with shallow surface depression of the intima. By using the definition of ulcer size, the surgeon could accurately identify the ulcer, even if the plaque was transected accidentally at the site of an ulcer. Every plaque was classified as either having an ulceration of, or above, the described size or not. In case of an ulceration the surgeon had to state the location of the ulceration with regard to its position on the plaque and to its distance to the bifurcation.

#### *Statistical Analysis*

Sensitivity, specificity, and accuracy were calculated as previously described (17).

## **Results**

In all 89 patients, intraoperative findings confirmed the degree of the stenosis (high-grade to threadlike) found preoperatively by conventional Doppler sonography. During surgery, 43 patients were found to have ulcerations in combination with ICA stenosis. All ulcerations were located at the site of maximum blood flow velocity, which means in the stenotic or post-stenotic part of the plaque. Forty-six patients had either simple plaques covered with smooth fibroatheromatous tissue or plaques with macroscopic pitting without gross ulcerations. CFDS correctly identified 41 of 43 ulcerations (a sensitivity rate of 95.3%). In three patients, the preoperative diagnosis of a significant ulceration at the site of ICA stenosis could not be confirmed intraoperatively (specificity: 93.5%). False positive results were found in gross irregularities of the plaque surface, such as longitudinal steps without intimal disruptions or in depressions between adjacent plaques. CFDS was 94% accurate in identifying ulcerations associated with high-grade or threadlike ICA stenosis. No difference in accuracy was found between the two examiners.

Representative CFDS findings are given in Figures 1 to 7. Figure 1 shows a "normal" high grade stenosis with systolic high flow velocity and dis-



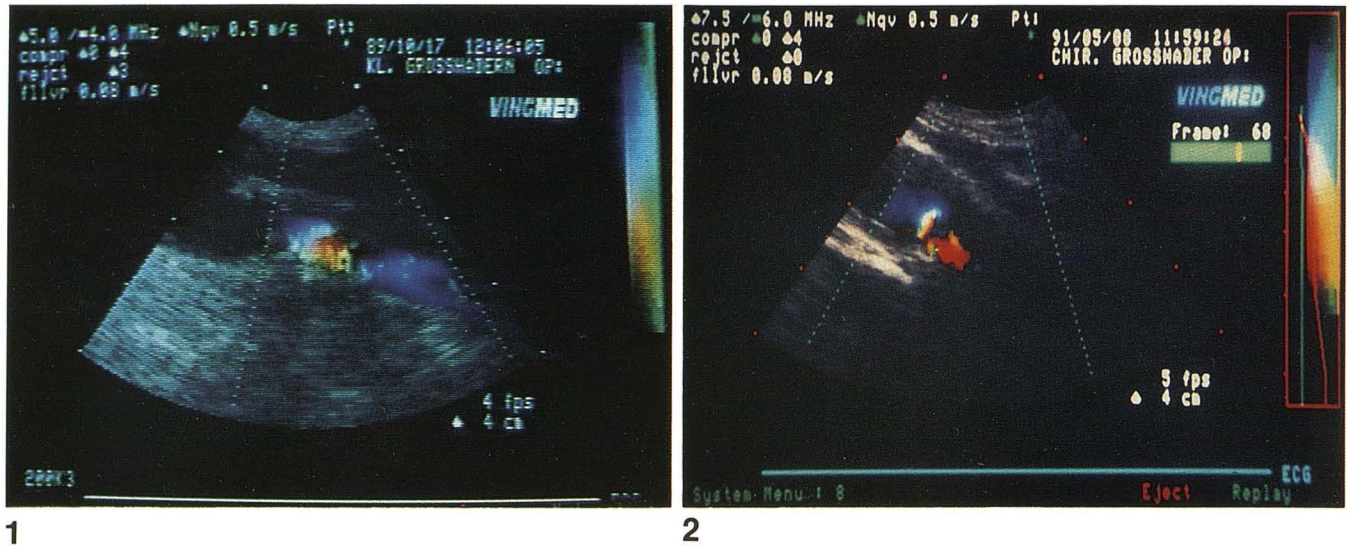


Fig. 1. High-grade ICA stenosis with intra- and post-stenotic arterial jet flow (red) and high-velocity turbulent flow (green/white).  
 Fig. 2. High-grade ICA stenosis at peak systole with vortex formation due to plaque ulceration.

turbulent flow (high-velocity turbulent flow = green/white coloration) at the origin of the ICA. Figures 2 to 7 show high-grade ICA stenosis with intrastenotic vortex formation at maximum systolic flow. The anatomical position of the Doppler probe is identical in Figures 2, 5, and 6. Vortex formation can be diagnosed and differentiated from high-velocity turbulent flow by the typical spatial arrangement of areas of high-velocity flow (disturbed = green/white; laminar = red or blue) and of areas with reduced multidirectional flow (narrow bandwidth and mean flow velocity of zero = black). Thus, vortices cause typical alterations of blood flow in their immediate neighborhood (circular disturbed and laminar flow) and demonstrate a continuous reduction and heterogeneity of flow velocity towards their center. Figures 2 and 3 (schematic explanation of Fig. 2) show the typical spatial arrangement of different colors at peak systole due to ulceration. Figure 4 presents, also as a scheme, the lateral two-dimensional view of the same stenosis at peak systole. Note that the vortex is located in the examination plane of the Doppler probe. Figure 5 shows the same stenosis at late systolic flow (the picture was taken 200 msec after the one in Fig. 2). Due to the deceleration of flow, the area of reduced multidirectional flow (black) has disappeared. The circular area of high velocity flow (green/white) and the aliasing phenomenon (red) can still be seen. Figure 6 presents the same stenosis now at diastolic flow (the picture was taken 800 msec after the one in Fig. 2). Flow velocity has further decreased allowing now an

almost laminar flow above the ulcer. Disturbed flow (green/white) as well as intrastenotic aliasing is markedly reduced and the typical circular spatial arrangement has also disappeared. A scheme of the situation at diastole (lateral view) is shown in Figure 7. The examination plane is still in the same anatomical position above the ulcer which, however, no longer causes the formation of a significant vortex because of the diastolic deceleration of blood flow velocity. Compared to Figure 4, the area of disturbed flow is markedly diminished and its maximum is now located underneath the examination plane.

## Discussion

Sonographic examination of the ICA has gained its firm place in the noninvasive evaluation of patients with cerebrovascular disease. Duplex sonography and continuous-wave Doppler sonography have been found to be accurate in identifying and quantifying ICA stenosis. Also detection and description of atherosclerotic plaques are possible and intraplaque hemorrhage can be determined precisely (9, 10, 15, 18). On the other hand, there is considerable controversy about the use of Duplex sonography in detecting plaque ulceration. Thus, sensitivities for high-resolution Duplex scanning to correctly identify ulcerations vary between 0 and 93% (10, 19). Furthermore, in those studies in which the highest sensitivities were reported (89% and 93%, respectively (18, 20)), most patients had simultaneous luminal narrowing of the ICA of less than



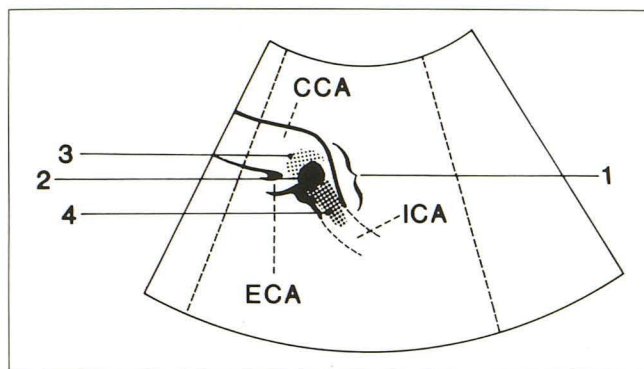
50%. However, it is now evident that, with a more severe degree of stenosis, significant limitations of Duplex sonography are encountered (12). Thus, Duplex sonography is often considered not feasible for identifying patients with concomitant plaque ulceration and high-grade carotid artery stenosis (12, 21–23). Our findings show that CFDS may close this gap in diagnosing patients with ICA disease, especially in those who present with a high-grade or threadlike ICA stenosis.

Identification of atheromatous ulcers in patients with significant ICA stenosis appears possible by analysis of hemodynamic changes alone

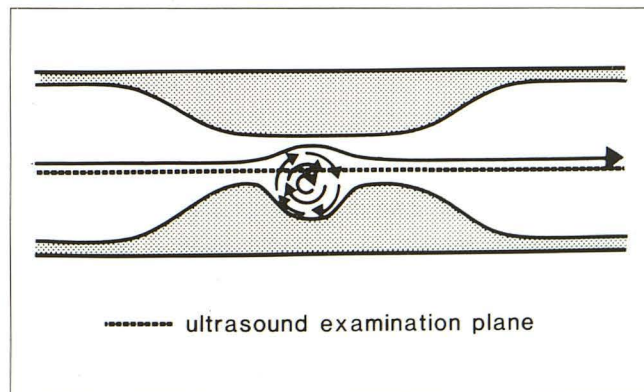
and does not require information about morphology. Experimental studies have shown that morphologic changes in the vascular wall may have distinctive effects on hemodynamics in the affected region. Thus, recent experiments demonstrated with precision the impact of lateral aneurysms on flow conditions in elastic vessel models with pulsatile perfusion of non-Newtonian blood-like fluids (14). Flow in the aneurysmatic region could be shown to be multidirectional and associated with variable flow velocities, but also to depend strictly on the phase of the pulse wave. Flow velocities in the center of the aneurysm ranged between 10%–15% of the axial velocity in the parent vessel. However, intraaneurysmatic flow irregularities (low frequency flow fluctuations) were found that were superimposed on the pulse cycle and represented early transitions to vortex formation.

Intraaneurysmatic flow velocity is known to be directly proportional to the flow velocity in the parent vessel (14) and indirectly proportional to the square of the maximum fundus diameter (24). Therefore, a higher flow velocity with a reduced pulse wave in the parent vessel and a reduction in the aneurysm size will markedly increase the intraaneurysmatic flow velocity, thereby leading to greater chance of vortex formation. An extreme situation is found at systole in small stenosed vessels with lateral plaque ulcerations: flow velocity in the stenosis is high and associated with almost nonpulsatile flow, and in comparison to the flow velocity in the parent vessel, the diameter of the ulcer (which, as a simplification, can be regarded as a lateral aneurysm-like wall change from the hemodynamic point of view) is very low. Therefore, we have hypothesized that, at systole, a high percentage of ulcerated plaques in patients with ICA stenosis is associated with vortex formation at the site of the ulcer and should, consequently, be detectable by sonographic imaging with simultaneous analysis of flow irregularities. Furthermore, due to the deceleration of flow, vortex formation should be diminished or even be absent at diastole.

A vortex represents in the central part an area of extremely irregular flow in which velocities in a defined range cell are low (resulting in a narrow bandwidth) and show a random variation with reference to temporal and spatial coordinates. This phenomenon indicates that, in the examined area, Doppler frequencies are random and multidirectional. This phenomenon results in a very low mean frequency and will appear black in the



3

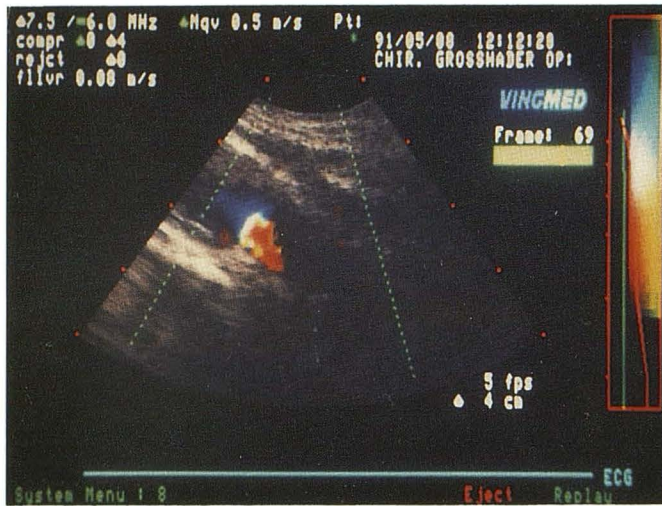

4

Fig. 3. Explanatory scheme of the coloration and of the anatomical situation of the stenosis presented in Figure 2. CCA, common carotid artery; ICA, internal carotid artery; ECA, external carotid artery; 1, region of vessel narrowing (stenosis); 2, area of reduced multidirectional flow (black); 3, area of circular disturbed and laminar flow (continuous transition between red, green, and white). 2 and 3 indicate the vortex which is provoked by an ulcer; 4, flow acceleration at the terminal part of the stenosis (red, aliasing phenomenon).

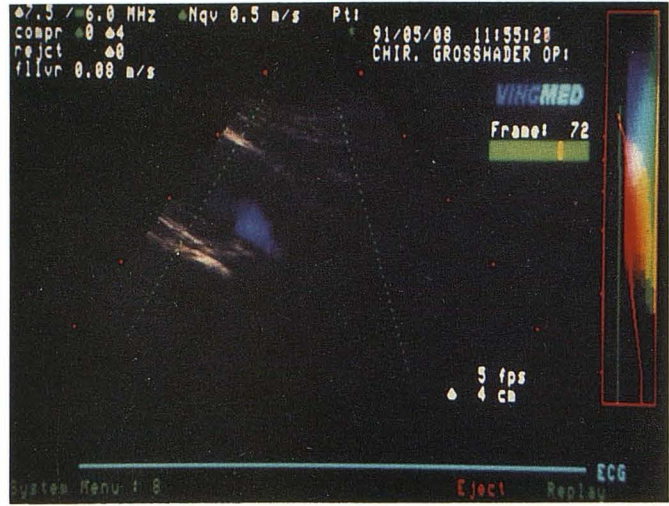
Fig. 4. Schematic lateral view of the stenosis and of the vortex at peak systole presented in Figures 2 and 3. Note the spatial relationship of the examination plane to the vortex and to the ulceration. The vortex is directly located in the examination plane.





5

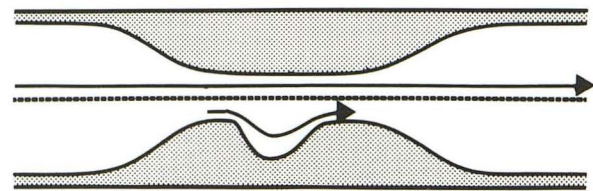
Fig. 5. ICA stenosis of Figure 2, 200 msec after peak systole. The position of the examination plane is unchanged. Compared to Figure 2, the area of reduced multidirectional flow (black) has disappeared due to the deceleration of flow. The circular area of high-velocity flow (green/white) and the aliasing phenomenon (red) can still be seen.



6

Fig. 6. ICA stenosis from Figures 2 and 5 at diastole. The position of the examination plane is unchanged. Compared to Figure 5, flow velocity has further decreased, leading now to an almost laminar flow (blue) above the ulcer. Disturbed flow (green/white) as well as intrastenotic aliasing is markedly reduced and the typical circular spatial arrangement has also disappeared.

Fig. 7. Schematic lateral view of the stenosis at diastole presented in Figure 6. The spatial relationship of the examination plane to the ulceration is the same as in Figure 4. Compared to Figure 4, the area of disturbed flow is markedly diminished and its maximum is now located underneath the examination plane.



----- ultrasound examination plane

7

image (25). In the peripheral parts of the vortex, flow velocity will increase and become more directional, or may show a random variation with respect to its direction, if the peripheral flow in the vortex mixes with the unidirectional high velocity flow in the stenosis. Range cells in these areas will exhibit multidirectional Doppler frequencies with a wide bandwidth. If the bandwidth of these frequencies is higher than twice the Nyquist limit, digital analysis of flow velocities in the range cell will then indicate disturbed flow, which appears green/white in the image. This phenomenon explains why, in the case of vortex formation in the image, a central black area may be surrounded by areas of green/white coloration. The circular band of green/white coloration is always combined with range cells of a high-velocity laminar flow (red or blue) in areas in which mixing of blood flow from the vortex and parent vessel does not occur, or in which blood flow from the vortex and parent vessel show the

same direction. It should be noted that the flow velocities which are measured by Doppler sonography in lateral aneurysms or ulcerations (and in associated vortices) may be falsely high. For example, in a lateral aneurysm, the angle between the insonation beam and the moving targets, which in this case change their direction in relationship to the parent vessel, will usually decrease during conventional Doppler examinations. This decrease will result in an overestimation of flow velocities compared to flow velocities in the parent vessel. However, such an overestimation will even further emphasize the hemodynamic changes associated with plaque ulceration.

Our results seem to confirm the above mentioned hypothesis. In more than 90% of the cases, ulcerations were found by CFDS to cause a region of vortex formation at systole in the stenosis. In all cases, vortex formation decreased at diastole. Because of CFDS's high sensitivity (95.3%), specificity (93.5%), and accuracy (94%) for di-



agnosis of ulceration in patients with ICA stenosis, it may offer a significant advantage for the non-invasive screening of patients with carotid artery disease. The possibility that CFDS may allow the identification of ulceration in patients with carotid artery disease was reported earlier (26). However, thus far, no detailed study, in which noninvasive diagnosis of ulcerative plaques was made solely on the basis of hemodynamic changes, has been published.

Complete, noninvasive diagnosis of luminal narrowing and of plaque morphology, including ulceration, will, on the one hand, help us to plan better the surgical procedure (eg, to select the best site of arterial cross clamping) and may, on the other hand, allow us to describe accurately the degree of carotid artery disease and to identify better the patient's risk for stroke in future prospective studies. From the present study, we cannot draw definite conclusions about the relative importance of ulcerated plaques for causing future cerebral symptoms in patients with high-grade to threadlike ICA stenosis. At the moment, the degree of luminal narrowing and the presence or absence of clinical symptoms represent the major criteria on which the indication for surgery is based (2, 3). Nevertheless, the use of CFDS may allow us to design prospective studies, eg, in asymptomatic patients in whom treatment is currently still controversial. Thus, one might compare the natural course or the effect of conservative treatment to the effect of carotid endarterectomy in patients with different specific presentations of carotid artery disease (such as ulcerations). These studies may eventually help to clarify whether there are subgroups of patients who bear a particular high risk for stroke and who will ultimately benefit from treatment.

## References

- Winslow CM, Solomon DH, Chassin MR, Kosecoff J, Merrick NJ, Brook RH. The appropriateness of carotid endarterectomy. *N Engl J Med* 1988;318:721-727
- NASCET Collaborators. Beneficial effect of carotid endarterectomy in symptomatic patients with high-grade carotid stenosis. *N Engl J Med* 1991;325:445-453
- European Carotid Surgery Trialists Collaborative Group. MRC European Carotid Surgery Trial: interim results for symptomatic patients with severe (70-99%) or with mild (0-29%) carotid stenosis. *Lancet* 1991;337:1236-1243
- Wilson SE, Mayberg MR, Yatsu FM. Defining the indications for carotid endarterectomy. *Surgery* 1988;104:932-936
- Fürst H, Hartl WH, Jansen I, Sutter T, Lauterjung L, Schildberg FW. Relevance of cerebral vasomotor reactivity to prospects for successful endarterectomy. *Lancet* 1990;335:166-167
- Bornstein NM, Norris JW. The unstable carotid plaque. *Stroke* 1989;20:1104-1106
- Dixon S, Pais O, Raviola C, et al. Natural history of nonstenotic, asymptomatic ulcerative lesions of the carotid artery. *Arch Surg* 1982;117:1493-1498
- Imparato AM, Riles TS, Mintzer R, Baumann FG. The importance of hemorrhage in the relationship between gross morphologic characteristics and cerebral symptoms in 376 carotid artery plaques. *Ann Surg* 1983;197:195-203
- Acker JD, Cole CA, Mauney KA, Joly DM, Machin JE. Duplex carotid ultrasound. *Neuroradiology* 1986;28:608-617
- Roussel L, Steyaert L. Duplex sonography of the cervical carotid artery. I. Physical principles and technique: normal and pathological findings. *J Belge Radiol* 1988;71:577-588
- Grant EG, Tessler FN, Perrella RR. Clinical Doppler imaging. *AJR: Am J Roentgenol* 1989;152:701-717
- Comerota AJ, Katz ML, White JV, Grosh JD. The preoperative diagnosis of the ulcerated carotid atheroma. *J Vasc Surg* 1990;11:505-510
- Angelsen BAJ, Kristoffersen K, Torp HG, Linker DT, Skjærpe T. Color flow mapping with an annular array. In: Nabda NC, ed. *Textbook of Color Doppler echocardiography*. Philadelphia: Lea and Febiger, 1989:56-63
- Liepsch DW, Steiger HJ, Poll A, Reulen HJ. Hemodynamic stress in lateral saccular aneurysms. *Biorheology* 1987;24:689-710
- Fürst H, Sutter T, Lauterjung L, Schildberg FW. The value of cw-Doppler ultrasonography and DSA in the diagnosis of extra- and intracranial stenosis: a comparison with intraoperative findings. *Thorac Cardiovasc Surg* 1989;37:243-245
- Kerstein MD. Improving predictive value of complementary tests in carotid artery disease. *Surgery* 1983;93:54-57
- Macheers SK, Kerstein MD. Ultrasonic imaging in the diagnosis of carotid vascular disease with attention to operated upon nonangiographic lesions. *Am J Surg* 1986;52:532-536
- Reilly LM, Lusby RJ, Hughes L, Ferrell LD, Stoney RJ, Ehrenfeld WK. Carotid plaque histology using real-time ultrasonography. *Am J Surg* 1983;146:188-193
- Rubin JR, Bondi JA, Rhodes RS. Duplex scanning versus conventional arteriography for the evaluation of carotid artery plaque morphology. *Surgery* 1987;102:749-755
- O'Donnell TF, Erdoes L, Mackey WC, et al. Correlation of B-Mode ultrasound imaging and arteriography with pathologic finding at carotid endarterectomy. *Arch Surg* 1985;120:443-449
- Bluth EL, McVay LV, Merritt CRB, Sullivan MA. The identification of ulcerative plaque with high resolution Duplex carotid scanning. *J Ultrasound Med* 1988;7:73-76
- Sterpetti AV, Schultz RD, Feldhaus RJ, et al. Ultrasonic features of carotid plaque and the risk of subsequent neurologic deficits. *Surgery* 1988;104:652-660
- Leahy AL, McCollum PT, Feeley TM, et al. Duplex ultrasonography and selection of patients for carotid endarterectomy: plaque morphology or luminal narrowing. *J Vasc Surg* 1988;8:558-562
- Hashimoto T. Dynamic measurement of pressure and flow velocities in glass and silastic model berry aneurysms. *Neurol Res* 1984;6:22-28
- Liepsch D. Flow in tubes and arteries: a comparison. *Biorheology* 1986;23:395-433
- Middleton WD, Foley WD, Lawson TL. Color-flow Doppler imaging of carotid artery abnormalities. *AJR: Am J Roentgenol* 1988;150:419-425