

White Matter Changes in Patients with Breast Cancer Treated with High-Dose Chemotherapy and Autologous Bone Marrow Support

Salomon M. Stemmer, John C. Stears, Bradford S. Burton, Roy B. Jones, and Jack H. Simon

PURPOSE: To study MR changes in the white matter of the brain in patients with breast cancer treated with a widely used protocol of high-dose chemotherapy and autologous bone marrow support. **METHODS:** Thirteen patients with high-risk stage II or stage IV breast cancer treated with high-dose cyclophosphamide, cisplatin, carmustine, and bone marrow support underwent post-transplant MR examination of the brain. Serial posttransplant MR examinations were performed in 5 of the 13 patients and single MR examinations in 8. The severity of the white matter change was evaluated by two neuroradiologists and rated mild, moderate, or severe. **RESULTS:** In 9 of the 13 patients, central and peripheral cerebral white matter changes were observed. Four patients had severe changes, extending from the ependyma of the lateral ventricles to the gyri. An additional 4 patients had moderate white matter change at the last observation. One had mild change, and 4 had no white matter change. In all patients, there was sparing of inferior frontal, posterior inferior occipital, and anterior temporal lobes, and of the centrosylvian brain. **CONCLUSIONS:** White matter change occurred in patients treated with a high-dose chemotherapy and bone marrow support protocol. Most of the changes, and the more severe ones, occurred 5 or more months after the transplants. There was no apparent relationship between these changes and central nervous system function. Because of the increased longevity with this treatment, it is important to appreciate these white matter changes, recognizing however that their expression may be subclinical.

Index terms: White matter, abnormalities and anomalies; Bones, marrow; Chemotherapy; Brain, effects of drugs on; Brain, magnetic resonance

AJNR Am J Neuroradiol 15:1267-1273, Aug 1994

White matter abnormalities have been recognized in patients treated with intrathecal, intravenous, or intraarterial chemotherapy and/or irradiation therapy to the brain, most frequently when intrathecal chemotherapy and irradiation are combined (1-16). In recent years, high-dose intravenous chemotherapy with autologous hematopoietic progenitor stem cell support (AHPSCS) is being intensively studied for the treatment of high-risk and advanced-stage breast cancer. The patients reported in this study had either high-

risk stage II breast cancer at protocol entry (defined as patients with multinode positive breast cancer after breast surgery) or stage IV breast cancer (defined as metastases after initial therapy). The results of this treatment are encouraging (17, 18). In the stage II group, with median follow-up of 4 years (maximum, 7 years), the actuarially projected disease-free survival is 72%; a similar population of stage II patients had 30% disease-free survival with conventional adjuvant chemotherapy (19). Comparable figures for stage IV breast cancer are 25% and 1% (20).

The major clinically observed toxicity attributed to this protocol is pulmonary, which results in a treatment-related morbidity of 30% to 50%, usually reversible, and a mortality of less than 2% presently (21).

Because of the effectiveness of this therapy, it is important to monitor patients for potentially related delayed toxicity.

Received October 18, 1993; accepted after revision April 13, 1994.

From the Department of Radiology, Section of Neuroradiology (J.C.S., B.S.B., J.H.S.), and the Bone Marrow Transplant Program (S.M.S., R.B.J.), University of Colorado School of Medicine, Denver.

Address reprint requests to John C. Stears, MD, Department of Radiology, Section of Neuroradiology, University of Colorado School of Medicine, 4200 E Ninth Ave, Campus Box A-034, Denver, CO 80262.

AJNR 15:1267-1273, Aug 1994 0195-6108/94/1507-1267

© American Society of Neuroradiology

TABLE 1: Clinical data before bone marrow transplant

Patient	Age, y	Date of Diagnosis	Stage at Diagnosis	Adjuvant Chemotherapy	Stage before Transplant	Induction Chemotherapy	Date of Bone Marrow Transplant
1	36	5/90	4 bone	...	4	DFM × 4	6/91
2	58	9/88	2	CDF × 6	4	F	10/91
3	49	3/87	2	None	4	DFM × 4	1/92
4	33	5/91	2	...	2	DFM × 4	9/91
5	40	6/87	2	CMF Tam	4	DFM × 4	10/90
6	38	4/91	2	...	2	DFM × 4	8/91
7	49	7/89	1	Tam	4	DFM × 4	12/91
8	47	6/78	2	CMF × 12	4	DFM × 4	11/91
9	50	4/90	1	CMF × 6	4	DFM × 4	10/92
10	43	2/87	3	CDF × 9	4	None	7/91
11	52	5/80	2	Melp, F Tam	4	DFM × 4	9/91
12	39	8/90	2	CDFM × 4	4	DFM × 2	7/91
13	37	8/91	4	DFM × 4	4	DFM × 4	12/91

Note.—M indicates methotrexate; Tam, tamoxifen citrate; Melp, melphalan; F, fluorouracil; C, cyclophosphamide; and D, doxorubicin hydrochloride.

In this report we describe brain white matter changes, predominantly cerebral, identified on T2-weighted magnetic resonance (MR) acquisitions of the brain in patients treated with high-dose chemotherapy and bone marrow support without intrathecal chemotherapy or brain irradiation.

Materials and Methods

From October 1990 to November 1992, 69 patients with stage II or stage IV breast cancer were treated with a phase II protocol of high-dose cyclophosphamide/cisplatin/carmustine and AHPSCS at the University Bone Marrow Transplant Program. The 13 patients included in this report had posttransplant MR examinations of the brain.

Nine of the 13 patients received adjuvant chemotherapy, defined as standard chemotherapy after breast surgery, before enrollment for bone marrow support. The variability of this adjuvant chemotherapy is noted in Table 1.

Induction chemotherapy was given to 12 of the 13 patients. This typically began 3 months before the transplant and consisted of doxorubicin hydrochloride (Adriamycin), fluorouracil (5-fluorouracil), and methotrexate given in 5-day treatment periods every 3 weeks for two to four administrations (22) (Table 1). The doxorubicin hydrochloride/fluorouracil/methotrexate protocol is given to reduce the volume of tumor rapidly to a low level before bone marrow support treatment.

All the patients received the bone marrow support chemotherapy, a widely used protocol (17). This consists of cyclophosphamide (1875 mg/m² per day as a 1-hour intravenous infusion, given on days -6, -5, and -4); cisplatin (55 mg/m² per day as a continuous intravenous

infusion for 72 hours, begun on day -6); and carmustine (600 mg/m² as a 2-hour intravenous infusion on day -2). Bone marrow reinfusion was performed on day 0.

A pretransplant MR or computed tomographic examination of the brain (MR, 5 patients; computed tomography, 8 patients) was performed in all 13 patients to evaluate metastatic disease. Thirteen patients had posttransplant MR examinations of the brain. This MR examination consisted of T1- and T2-weighted axial sections and T1-weighted sagittal sections, as a minimum. Ten of the MR examinations were not enhanced; 20 had both preenhancement and postenhancement (gadopentetate dimeglumine) sequences (Table 2). The MR examinations were serial in 5 patients and single in 8 patients. The posttransplant MR examinations were retrospectively evaluated for white matter change.

Table 1 defines patient demographics and clinical course before bone marrow support. Table 2 defines the course beginning with the bone marrow support and the related toxicities. The white matter change, described by both severity and interval of the MR examination after transplant, is noted in Table 2. The number of MR examinations performed after transplant are summarized by time periods in Figure 1.

The reasons for performing the posttransplant MR examinations are noted in Table 2 and include visual toxicity in one patient (a syndrome of abnormal visual fields and decreased visual acuity, compatible with optic nerve injury). Two patients had both visual toxicity and transient ischemic attacks (Table 2). The visual symptoms were almost totally reversed within 4 to 6 weeks in two patients but were irreversible and severe at more than 1 year in one patient (Stemmer SM et al, unpublished data). Three had transient ischemic attacks, in which symptoms persisted from a few seconds to minutes, with complete resolution in

TABLE 2: Clinical and MR data after bone marrow transplant

Patient	Acute Visceral Toxicities	Neurologic Toxicities	Steroids after Bone Marrow Transplant	Latest Tumor Status	MR Changes (Months after Bone Marrow Transplant)			
					None	Mild	Moderate	Severe
1	Lung (+4 mo)	TIA (+9 mo)	Yes (lung)	NE			*6	*11, *16, 21
2	Lung (+5 mo)	Psychosis (+8 mo) TIA (+10 mo)	Yes (lung)	Relapse (+17 mo)	*Pre			*9, 11, 16
3	None	TIA (+2 mo) Vision (+3 mo)	Yes (eye)	NE		*2, *3	4, 14	
4	Lung (+5 mo)	None	Yes (lung)	NED	*Pre			*5
5	None	Vision (+3 mo)	No	Relapse (+6 mo) (dead)	*1		*4	
6	RF, CHF, Lung (+4 mo), Asper Pneumonectomy	TIA (+20 mo)	Yes (lung)	NED		*9, *20	*12, 19	
7	None	Post-zoster Neuralgia (+6 mo)	Intrathecal (Neuralgia)	Relapse (+15 mo)	Pre			15
8	Lung (+4 mo)	Vision (+3 mo) TIA (+9 mo)	Yes (lung)	NE		*2		
9	None	None	No	NED	*Pre		6	
10	Lung (+6 mo)	None	Yes (lung)	NE	*Pre, *15			
11	None	None	No	Relapse (+8 mo) (dead)	*2			
12	Lung (+4 mo)	None	Yes (lung)	NED	21			
13	None	None	No	NE	*1			

Note.—TIA indicates transient ischemic attack; *, MR before and after enhancement; NED, no evidence of disease; NE, not evaluable; + mo, months after bone marrow transplant that toxicity occurred; RF, renal failure; CHF, congestive heart failure; Asper, aspergillus infection; and Pre, before bone marrow transplant.

less than 24 hours without any specific treatment, and were single or recurrent up to three times. Both of these symptoms usually began within the first 6 months after the transplant. There were no specific abnormalities on MR examinations observed in the patients with the visual and transient ischemic attack symptoms. More sensitive MR sequences for the visual system were performed in one patient. One patient had herpes zoster in the buttock of

several weeks' duration. Six patients had no recognized ophthalmologic or neurologic complications, and the MR examinations were performed for subtle clinical suspicion of change in brain function.

In seven of the 13 patients posttransplant carmustine-associated lung toxicity developed (21) 3 to 6 months after the transplant; it was treated with steroids, usually successfully (Table 2).

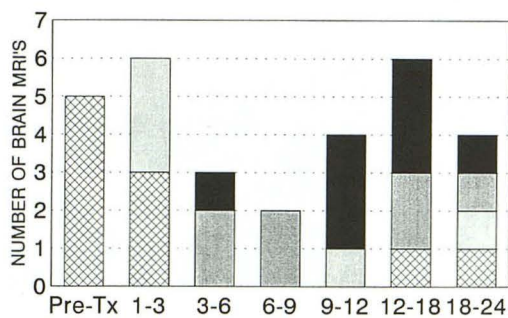


Fig 1. White matter change, months after transplant (Tx).

SEVERE			1		3	3	1
MODERATE			2	2		2	1
MILD		3			1		1
NORMAL	5	3				1	1

MONTHS POST-TRANSPLANT

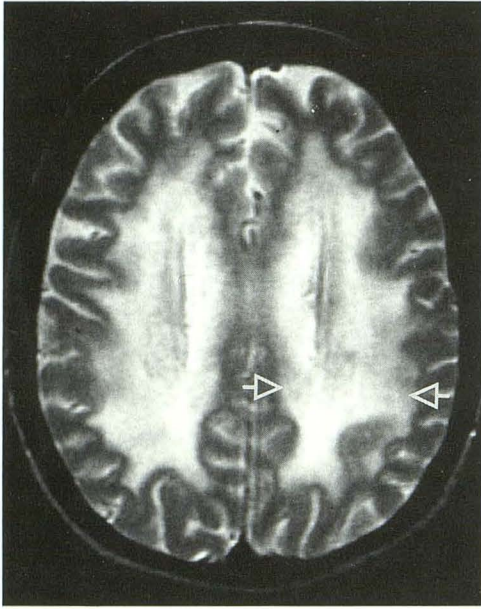


Fig 2. Patient 2, severe white matter change. Axial T2-weighted acquisitions (2000/80 [repetition time/echo time]) at the level of the roof of the lateral ventricles 11 months after bone marrow support. Note the diffuse, symmetric hyperintensity involving periventricular, central, and subcortical white matter (*open arrows*). This degree of severity was seen in four of the nine patients.

The severity of the white matter change was based on a consensus opinion from concurrent review by two neuro-radiologists. Mild changes were defined as small, focal hyperintensities on T2 weighting, which were usually multiple. Severe changes were defined as near-total white matter hyperintensity on T2 weighting in the susceptible areas of the cerebrum. Moderate changes fell between these two categories.

Results

Cerebral white matter changes were present on MR examinations in 9 of the 13 patients (Table 2).

The white matter abnormality is described as hyperintensity on the T2-weighted MR acquisition. In all of the nine patients, the central and peripheral supraventricular cerebral white matter was involved. In the severe form (patients 1, 2, 4, and 7), the process extended from the ependyma of the lateral ventricles (especially the bodies) to the base of gyri and into the gyral white matter (Fig 2). In one patient (patient 3), there was a suggestion that the process began in the immediate subcortical gyral region and spread centripetally toward the ependyma (Fig 3). In all patients there was sparing of inferior frontal, posterior and inferior occipital, and anterior temporal lobes. We observed no change in the centrosylvian brain. There was suspected mild involvement of the body of the corpus cal-

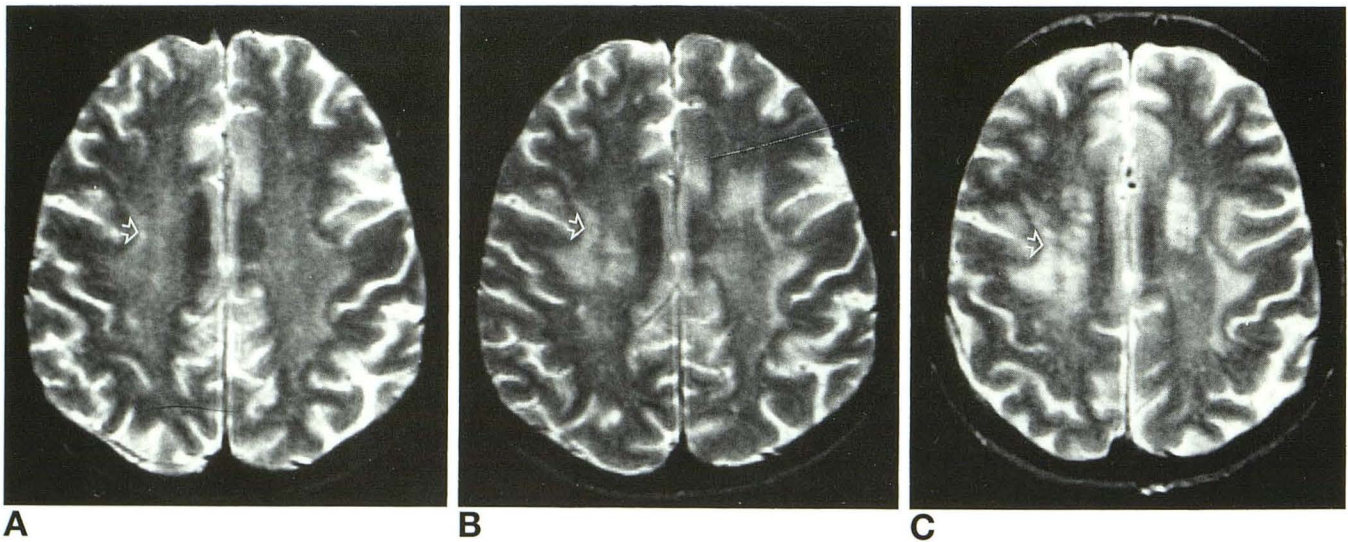


Fig 3. Patient 3, centripetal progression. Axial T2-weighted acquisitions (2000/80) at the level of the centrum semiovale.
 A, Two months after bone marrow support. Mild, bilateral hyperintensity preferentially involving the subcortical white matter.
 B, Four months after bone marrow support. Increased subcortical hyperintensity moving centripetally to central and periventricular white matter, bilaterally, moderate degree.
 C, Fourteen months after bone marrow support. Further increase in central and periventricular white matter change, moderate degree. *Open arrows* compare one area of the white matter change.

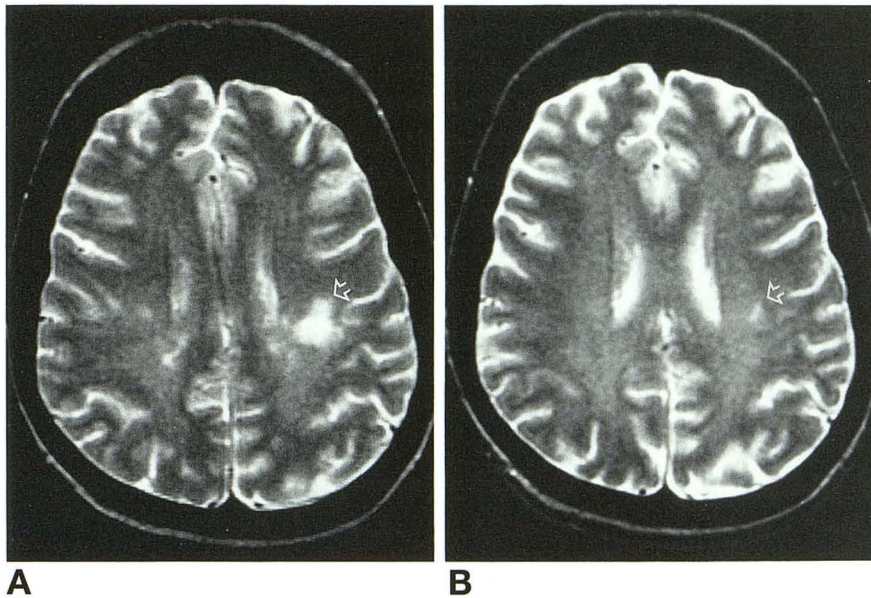


Fig 4. Patient 6, regression of white matter change. Axial T2-weighted acquisitions (2100/90) at and just above the lateral ventricles. At 9 months after bone marrow support, the white matter was normal.

A, Twelve months after bone marrow support. Note patchy, bilateral, white matter hyperintensity greater on the left, mild degree.

B, Twenty months after bone marrow support. Spontaneous improvement in white matter change (open arrows).

losum in five patients on axial sections, not verified because T2-weighted coronal or sagittal sections were not performed. These five patients had moderate or severe cerebral hemisphere white matter changes.

Duropathy was seen in one patient at 1 month after transplant but disappeared at 4 months (patient 5). The 3-mm-thick suprasylvian bilateral dura was diffusely hyperintense on T2-weighted acquisition and similarly enhanced with gadopentetate dimeglumine.

In one patient (patient 6) we noted spontaneous reversal of the process. In this patient the white matter change reached a moderate level of intensity at 12 and 19 months but at 20 months had regressed to mild change (Fig 4). An unusual appearance of the white matter change was the presence of symmetrical peridentate cerebellar white matter hyperintensity on T2-weighted acquisition (Fig 5, A and B). This was seen in two of the nine patients (patients 2 and 3) who also had, respectively, severe and moderate cerebral white matter changes. Patient 2 had progressive pontine hyperintensity on T2-weighted acquisition (Fig 5, A and C).

In the 4 patients (of the 13) who had normal posttransplant MR examinations, 2 had their only MR examinations 1 and 2 months after transplant, and 2 were performed at 15 and 21 months, respectively.

The white matter change was not (or was vaguely) seen on T1-weighted acquisitions, and

no enhancement was seen with conventional doses of gadopentetate dimeglumine.

Metastatic neoplasm was not observed.

Discussion

The neurotoxicity of several chemotherapeutic and irradiation regimens, either singly or in combination, has been recognized by clinical manifestations and especially by MR examination of the brain (1-16). These have been most commonly reported with carmustine given in high intravenous doses (more than 1200 mg/m²) (8) or by intracarotid infusion alone or with cisplatin. Other alkylating agents such as chlorambucil (9), ifosfamide (10), mechlorethamine hydrochloride (nitrogen mustard) (11), or thiotepa (12), when given systemically in intensive doses, also have been implicated. Fluorouracil with levamisole hydrochloride has been reported to cause inflammatory leukoencephalopathy that reversed rapidly after cessation of therapy (13, 14).

The appearance of chemotherapy-induced white matter abnormality is bilateral hyperintensity on T2-weighted MR acquisitions, which may be focal or, in later stages, confluent and symmetrical. The changes are poorly or not seen on T1-weighted acquisitions. There was no enhancement with conventional doses of gadopentetate dimeglumine.

The nature of the white matter pathologic process is not known. There were no brain bi-

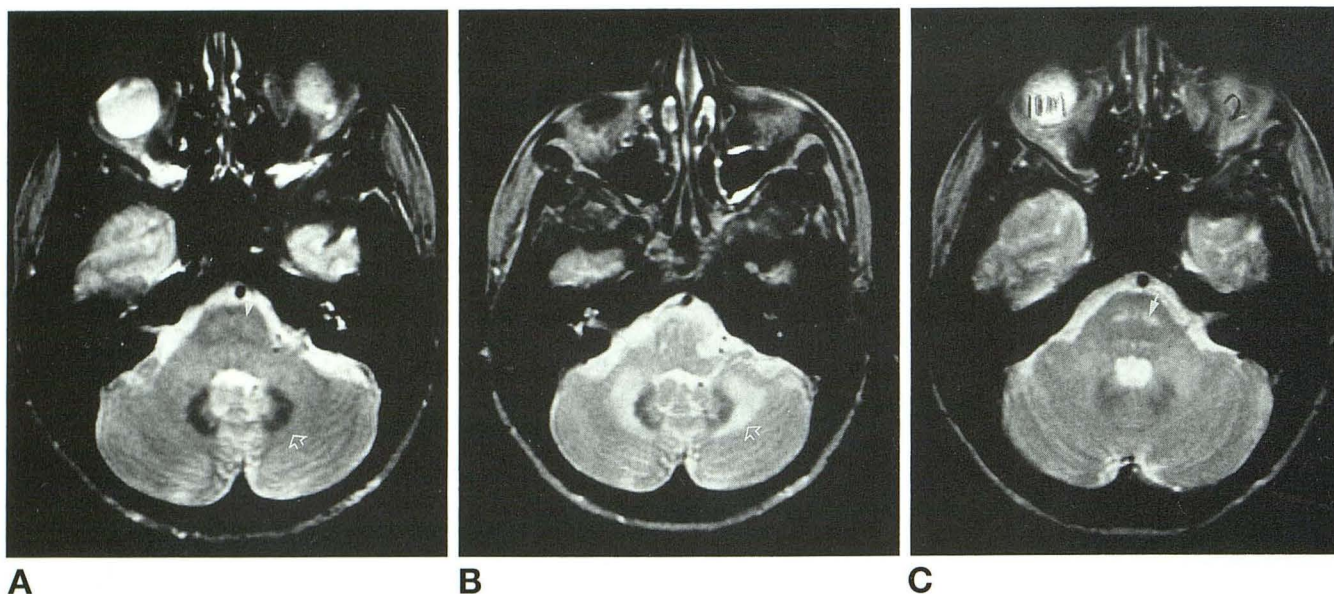


Fig 5. Patient 2, peridentate and pontine change. Axial T2-weighted acquisitions (2000/80) at the level of the middle cerebellar peduncles.

A, Before bone marrow support. Normal peridentate area (*open arrow*) and two foci of subtle increased signal in the midpons (*closed arrow*).

B and C, Eleven months after bone marrow support. Note thick symmetric rim of increased signal around the dentate nuclei (*open arrow*, B) and progressive bilateral central pontine hyperintensity (*closed arrow*, C). The peridentate change was seen in two of the nine patients. The pontine change was seen in this one patient.

opsies or autopsies performed in the nine patients reported in this paper.

Changes attributed to brain irradiation also have been recognized (4, 15, 16). Findings in our patients resemble those attributed to irradiation, in the centrum semiovale, and are probably indistinguishable. However, the sparing of the centrosylvian brain and the presence of peridentate lesions may be unique to this chemotherapy regimen (cyclophosphamide/cisplatin/carmustine), because we have not observed these findings in irradiated patients.

The common features noted in the group of patients with breast cancer reported in this paper are numerous. All patients were treated with intravenous chemotherapy alone. None of the patients received brain irradiation therapy or intrathecal chemotherapy. Immunosuppressive treatment (such as cyclosporine) was not used in any of the patients. Steroid therapy for lung or eye toxicity was always given in the first 6 months after transplant.

In the nine patients there was no obvious correlation between neurologic symptoms and the observed degree of white matter change. The white matter change seems to be progressive, with the severe changes being most common at 5 or more months after the bone marrow

support. In one patient (patient 6, Table 2, Fig 4), the process seemed to reverse without therapy.

Five patients had pretransplant MR examinations, and there were no white matter changes. In patient 8 (Table 2) there was mild white matter change on the posttransplant MR examination at 2 months, not observed on pretransplant computed tomography. The MR pattern suggested chemotherapy-related white matter change; there was no clinical basis for other causes.

The prevalence and incidence of the white matter changes in our larger transplanted population is unknown. Based on this retrospective review, the minimal incidence is 15% (9 of 69). The true incidence (and other features) are currently being determined through a prospective serial study.

The specific offending agent or agents causing the white matter change in this group cannot be determined from this study.

The common use of the doxorubicin hydrochloride/fluorouracil/methotrexate induction chemotherapy has not been associated with reported white matter change (22). It is likely therefore that the white matter change is related to the bone marrow support chemotherapy pro-

tolol, as used nationally and as reported in this paper.

The prolonged survival accruing from the effectiveness of this therapy requires the monitoring of patients for delayed toxicity. The white matter changes reported here are subclinical in some or all of these patients. A prospective study is under way to define more accurately the clinical significance of the white matter change. The findings may be important in the planning and monitoring of future chemotherapy regimens.

References

- Asato R, Akiyama Y, Ito M, et al. Nuclear magnetic resonance abnormalities of the cerebral white matter in children with acute lymphoblastic leukemia and malignant lymphoma during and after central nervous system prophylactic treatment with intrathecal methotrexate. *Cancer* 1992;70:1997-2004
- Hazuka MB, Kinzie JJ, Davis KA, DeBoise DA. Treatment related central nervous system toxicity: MR imaging evaluation with CT and clinical correlation. *Magn Reson Imaging* 1989;7:669-676
- Frytak S, Earnest F, O'Neill BP, Lee RE, Creagan ET, Trautmann JC. Magnetic resonance imaging for neurotoxicity in long term survivors of carcinoma. *Mayo Clin Proc* 1985;60:803-812
- Tsuruda JS, Kortman KE, Bradley WG, et al. Radiation effects on cerebral white matter: MR evaluation. *AJNR Am J Neuroradiol* 1987;8:431-437
- Ebner F, Ranner G, Slavc I, et al. MR findings in methotrexate-induced CNS abnormalities. *AJNR Am J Neuroradiol* 1989;10:959-964
- Lien HH, Blomlie V, Saeter G, et al. Osteogenic sarcoma: MR signal abnormalities of the brain in asymptomatic patients treated with high-dose methotrexate¹. *Radiology* 1991;179:547-550
- Truwit CL, Denaro CP, Lake JR, DeMarco T. MR imaging of reversible cyclosporin A-induced neurotoxicity. *AJNR Am J Neuroradiol* 1991;12:651-659
- Burger PC, Kamenar E, Schold C, et al. Encephalomyelopathy following high-dose BCNU therapy. *Cancer* 1981;48:1318-1327
- Ciobanu N, Runowicz C, Gucalp R, et al. Reversible central nervous toxicity associated with high dose chlorambucil autologous bone marrow transplantation for ovarian carcinoma. *Cancer Treat Rep* 1987;71:1324-1325
- Merimsky O, Reider-Groswasser I, Wigler N, Chaitchik S. Encephalopathy in ifosfamide treated patients. *Acta Neurol Scand* 1992;86:521-525
- Sullivan KM, Storb R, Shulman HM, et al. Immediate and delayed neurotoxicity after mechlorethamine preparation for bone marrow transplantation. *Ann Intern Med* 1982;97:182-189
- Lazarus HM, Reed MD, Spitzer TR, Rabaa MS, Blumer JL. High dose IV thiotepa and cryopreserved autologous bone marrow transplantation for therapy of refractory cancer. *Cancer Treat Rep* 1987;71:689-695
- Hook CC, Kimmel DW, Kvols LK, et al. Multifocal inflammatory leukoencephalopathy with 5-fluorouracil and levamisole. *Ann Neurol* 1992;31:262-267
- Kimmel DW, Schutt AJ. Multifocal leukoencephalopathy: occurrence during 5-fluorouracil and levamisole therapy and resolution after discontinuation of chemotherapy. *Mayo Clin Proc* 1993;68:363-365
- Stylopoulos LA, George AE, de Leon MJ, et al. Longitudinal CT study of parenchymal brain changes in glioma survivors. *AJNR Am J Neuroradiol* 1988;9:517-522
- Silber JH, Radcliffe J, Peckham V, et al. Whole-brain irradiation and decline in intelligence: the influence of dose and age on IQ score. *J Clin Oncol* 1992;10:1390-1396
- Peters WP, Ross M, Vredenburgh JJ, et al. High-dose chemotherapy and autologous bone marrow support as consolidation after standard-dose adjuvant therapy for high-risk primary breast cancer. *J Clin Oncol* 1993;11:1132-1143
- Eder JP, Antman K, Peters WP, et al. High dose combination alkylating agent chemotherapy with autologous bone marrow support for metastatic breast cancer. *J Clin Oncol* 1986;4:1592-1597
- Jones SE, Moon TE, Bonadonna G, et al. Comparison of different trials of adjuvant chemotherapy in St. II breast cancer using a natural history data base. *Am J Clin Oncol* 1987;10:387-395
- Decker DA, Ahmann DL, Bisel HF, Edmonson JH. Complete responders to chemotherapy in metastatic breast cancer. *JAMA* 1979;242:2075-2079
- Jones RB, Matthes S, Shpall EJ, et al. Acute lung injury following high-dose cyclophosphamide, cisplatin and carmustine with autologous bone marrow support: pharmacodynamic evaluation of carmustine. *J Natl Cancer Inst* 1993;11:640-647
- Jones RB, Shpall EJ, Shogan J, et al. The Duke AFM program: intensive induction chemotherapy for metastatic breast cancer. *Cancer* 1990;66:431-436