

Balloon Test Occlusion of the Internal Carotid Artery with Stable Xenon/CT Cerebral Blood Flow Imaging

S. M. Erba¹
 J. A. Horton¹
 R. E. Latchaw¹
 H. Yonas²
 L. Sekhar²
 V. Schramm³
 S. Pentheny¹

We describe a technique to predict preoperatively the safety of permanently occluding an internal carotid artery. The method was performed by imaging stable xenon cerebral blood flow (CBF) with the internal carotid artery both open and temporarily occluded with a nondetachable balloon on a double lumen Swan-Ganz catheter. Patients were those in whom we planned to sacrifice the internal carotid artery (those with giant or inaccessible aneurysms) or those in whom such a sacrifice was at least likely (those with skull base tumors). Patients were divided into three groups on the basis of a comparison of occluded and nonoccluded CBF values. Group-I patients had no significant change in CBF with internal carotid artery occlusion; group-II patients showed a symmetric decrease in CBF; and group-III patients had an asymmetric decrease in CBF, always greater on the occluded side. A fourth group clinically failed to tolerate even brief carotid occlusion. The internal carotid artery in one patient from group III was sacrificed at surgery: the size and shape of his postoperative infarct corresponded almost exactly to the area of asymmetrically decreased CBF on his occluded study.

The data suggest that if surgery is likely to result in permanent occlusion of the internal carotid artery, then patients who are at risk for delayed neurologic injury due to a compromised cerebral blood flow should have arterial bypass grafts before such surgery is performed.

Treatment of patients with tumors of the skull base or aneurysms of the internal carotid artery (ICA) often includes permanent occlusion of the ICA. Studies to assess whether a patient will tolerate this occlusion usually involve neurologic evaluation and measurement of the pressure in the distal ICA (stump pressure) during a trial ICA occlusion. An inflatable balloon is commonly used to occlude the ICA for a period of up to 15 min.

We have used xenon/CT CBF imaging to measure blood flow alterations that may occur during trial occlusion of the ICA in a series of patients who were candidates for permanent occlusion of this artery. CBF information was obtained to identify individuals potentially at risk for delayed infarction with ICA occlusion because they have poor CBF reserves. The technique was developed as a result of our experience with a patient who tolerated test occlusion clinically but later had a stroke after the tested artery was sacrificed.

Materials and Methods

During a 2-year period, a test occlusion of the ICA was made in 23 patients who were about to undergo either (1) skull base surgery in which the carotid artery was considered to be at risk or (2) carotid occlusion for the treatment of an inoperable aneurysm.

The technique for balloon occlusion involves shaping a 5-French Swan-Ganz double lumen catheter* over steam and then exchanging all the air within the balloon with a 15% Conray solution. The system is then passed into the femoral artery through a 6- or 7-French Hemaquet introducer sheath.[†] The catheter tip is advanced to the origin of the carotid artery and 5000 units of Heparin are administered intravenously to assure anticoagulation during the test. The

Received June 29, 1987; accepted after revision November 16, 1987.

¹ Department of Radiology, University Health Centers of Pittsburgh, 230 Lothrop St., Pittsburgh, PA 15213. Address reprint requests to J. A. Horton.

² Department of Neurosurgery, University Health Centers of Pittsburgh, Pittsburgh, PA 15213.

³ Department of Otolaryngology, University Health Centers of Pittsburgh, Pittsburgh, PA 15213.

AJNR 9:533-538, May/June 1988

0195-6108/88/0903-0533

© American Society of Neuroradiology

* Swan-Ganz, Edwards Laboratories, Inc., Annasco, PR 00610.

† C. R. Bard, Inc., 129 Concord Rd., Box 566, Billerica, MA 01821.

balloon is then alternately inflated and deflated while it is advanced into the ICA; blood flow carries the balloon to the desired level. After the balloon reaches the level of C1 or C2, it is deflated and the pressure is recorded from the distal catheter orifice via a transducer.

The balloon is inflated until arterial occlusion is achieved. Complete occlusion is confirmed when the balloon changes from a spherical to an incipiently tubular shape. The volume needed to achieve arterial occlusion varies among patients and is a function of the diameter of their carotid artery. Next, contrast material can be injected through the distal catheter lumen under fluoroscopic control to verify the cessation of antegrade flow. If this is done, the balloon should be deflated to allow for washout of contrast material from the artery: 15 min of pure contrast material in an artery will probably damage the intimal surface. The third check of adequate balloon inflation is the damping of the arterial pressure wave recorded from the distal catheter lumen.

Before prolonged trial ICA occlusion is begun, a baseline neurologic examination is performed with a battery of tests to examine both hemispheres for motor, sensory, and higher cortical functions. The distal ICA pressure is again recorded before and after ICA occlusion. With the ICA occluded, the patient is then examined. If any alteration of neurologic function is detected, the balloon is immediately deflated and the procedure terminated. If, instead, the patient tolerates the test occlusion for 15 min, the balloon is deflated but the catheter is left in place and the pressure is again recorded.

After the trial occlusion, the patient is transported to a GE/9800 CT scanner equipped with a stable xenon/CT CBF package. Adequate staff must accompany the patient so that the angiographer can devote his full attention to immobilizing the head and neck. After the patient is positioned within the scanner an initial xenon/CT CBF study is obtained with the balloon inflated. After the 7 minutes required to obtain the CBF examination, the balloon is deflated and the Swan-Ganz catheter is removed. The patient next undergoes a flow study, which begins 20 min after the initial study; this allows adequate time for the xenon to wash out. Because some individuals do not tolerate the prolonged period of relative restraint required to obtain a double study, we perform the more essential occlusion study first. At the conclusion of the entire examination, the patient is slowly given IV protamine sulfate to reverse the effects of heparin, and the Hemaquet sheath is removed.

Blood flow examinations in this setting involve imaging three 10-mm thick levels of the brain spaced 20 mm apart. This spacing was chosen so that we could survey representative areas of the brain, and 20-mm intervals allowed us to sample the basal ganglia, the brain

at the level of the body of the lateral ventricles, and the centrum semiovale. To measure CBF, two baseline images are obtained at each of the desired levels while the patient continues to breathe room air. During the 4 1/2-min period of xenon inhalation that follows, four CT scans are obtained at each of the three CT levels. While the sequential CT scans record the movement of stable xenon into the brain, the arterial buildup curve is obtained from the end-tidal measurements of xenon. A thermistor detects the end-tidal xenon concentration, and it is assumed that the partial pressure of xenon (pXe) in the end-tidal gas is equal to pXe in arterial blood. CBF is then calculated for each CT voxel ($1 \times 1 \times 10 \text{ mm}^3$) by using the Kety-Schmidt equation. This algorithm assumes a single compartment for each voxel and requires an iterative mathematical approach. The methodology has been described elsewhere [1, 2].

Quantitative flow information is then displayed on the CT scanner console. We have found it convenient to use a gray scale with a window width of 100 and a level of 50. In this way, flow values that are dangerously low tend to appear very dark. Standardizing the display has helped to reduce interobserver error.

To compare accurately CBF maps obtained with and without balloon occlusion, the respiratory rate and partial pressure of carbon dioxide (pCO₂) are kept as constant as possible by coaching the patient. The respiratory rate, end tidal pCO₂ (recorded by a capnograph), and blood pressure were recorded every 3 min throughout the procedure. If pCO₂ values varied more than 3 mm Hg between studies, then an adjustment of the value was made by assuming a 3% alteration of CBF for each mm of Hg alteration of pCO₂.

CBF values were obtained from multiple regions of interest 2 cm in diameter placed so as to cover all major vascular territories within each hemisphere. Corresponding left and right cortical areas were compared to check for symmetry of blood flow. To measure the change, the postocclusion blood flow values were subtracted from their anatomic counterparts in the study without occlusion, and differences for each patient were averaged.

Results

Six of our 23 patients did not complete the CBF studies either because they were unable to tolerate both studies (balloon inflated and deflated) or because of equipment malfunction. Patients showing no decrease in CBF with balloon occlusion defined group I (Fig. 1). Group II comprised patients

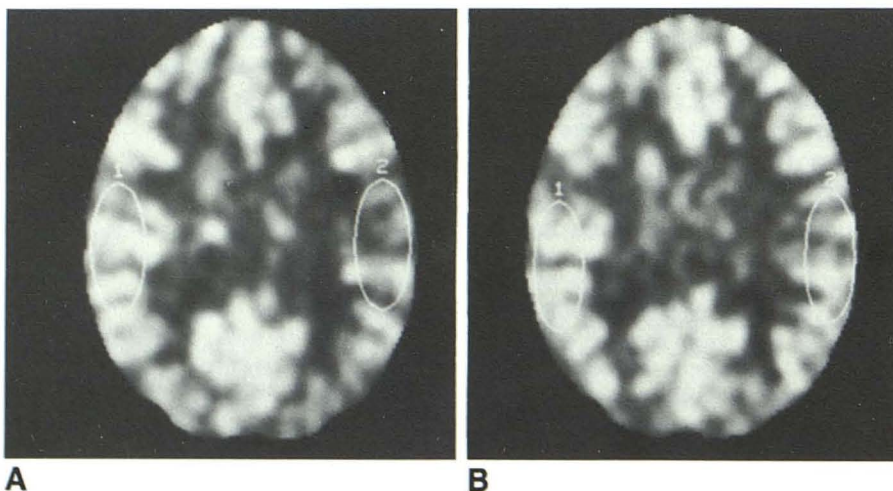


Fig. 1.—Group I. Unoccluded (A) and left occluded (B) studies. Although there is an apparent mild decrease in flow on the left, the overall impression of the image is that of constant cerebral blood flow. The cursors in this and in the other figures are shown just to demonstrate how specific blood flow measurements are made.

with symmetric decreases in CBF between hemispheres (Fig. 2). Patients with an asymmetric drop in blood flow constituted group III (Fig. 3); and the one patient who became confused and hemiparetic with ICA occlusion made up group IV.

Stump pressures after ICA occlusion were not significantly different within groups I, II, and III (Table 1).

Table 1 shows the extent of blood flow changes for groups I, II, and III. The six patients in group I had no change in global CBF with ICA occlusion. The three individuals in group II demonstrated a moderate reduction of blood flow in all territories with CBF reductions ranging from 2.8 to 10.5 ml/100

g/min. Group III, which included seven individuals and was the largest group in this series, had a significant reduction of global blood flow with greater flow reduction on the side of ICA occlusion. In these patients, flow values fell by 11.8 to 27.9 ml/100 g/min. No clinically significant complication occurred as a result of the procedure. One patient sustained a small asymptomatic dissection of the test-occluded ICA. This was observed at surgery.

Of the patients who had asymmetric blood flow decrease during ICA occlusion (group III) one sustained a right middle cerebral artery infarction on the first postoperative day after

Fig. 2.—Group II. Unoccluded (A) and right occluded (B) studies. Note mild symmetric decrease in cerebral blood flow. This indicates that intracranial collateral pathways are adequate, but that mass of blood flow into head is slightly decreased. The degree of change in this group was always less than that in group III.

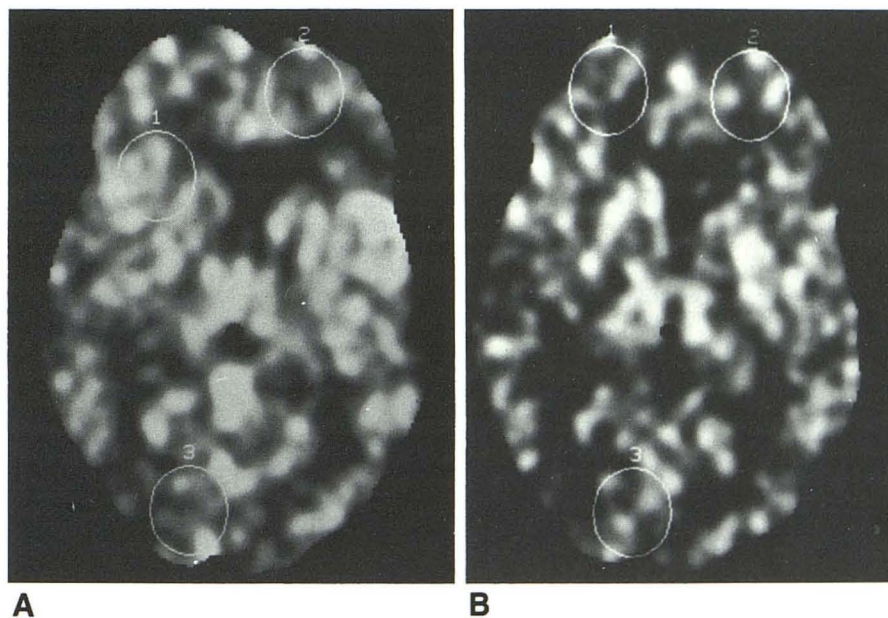


Fig. 3.—Group III. Unoccluded (A) and left occluded (B) studies. Note marked decrease of left hemisphere cerebral blood flow. This indicates inadequate intracranial collateral pathways and therefore high risk to the patient should even minimal hypotension develop during or after ICA occlusion.

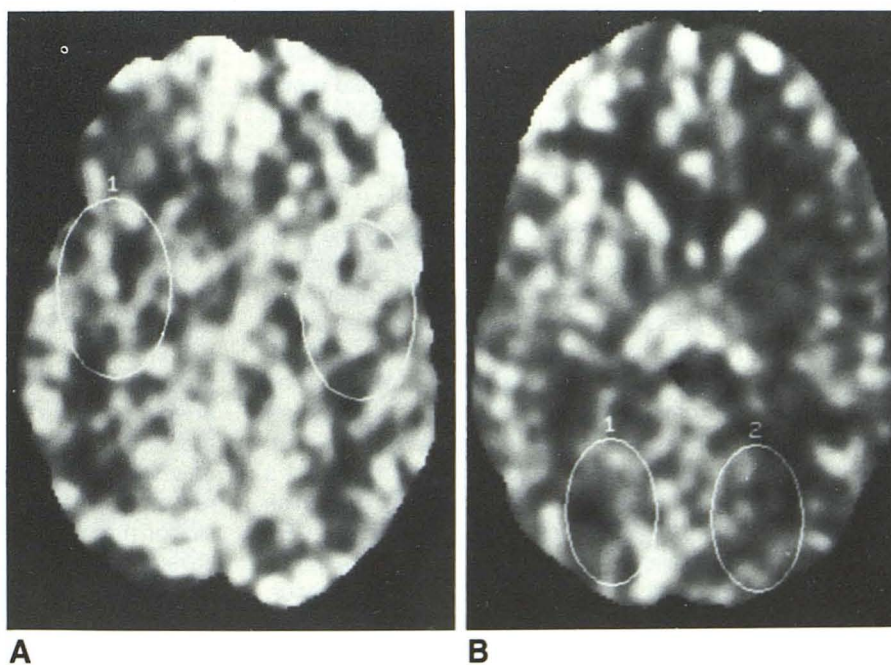


TABLE 1: Clinical Observations with Preliminary ICA Test Occlusion

Group	Balloon Occlusion, Clinical	Blood Flow Decrease (ml/100 g/min)	Postocclusion Stump Pressure (mm/HG)	Mean Stump Pressure Decrease (mm/HG)	CBF in MCA Distribution (ml/100 g/min)	Stroke Risk
I (n = 6)	Tolerated	0	35-100	0-35	40	Very minimal
II (n = 3)	Tolerated	2.8-10.5	28-60	38-46	30-40	Minimal
III (n = 7)	Tolerated	11.8-27.9	31-90	20-56	15-30	Moderate to high
IV (n = 1)	Not tolerated	Not done	—	30	Not done	Very high

TABLE 2: Diagnosis, Surgery, and Outcome

Patient No.	Group	Age	Diagnosis	Carotid Sacrificed	Outcome
1	I	56	Meningioma	No	—
2	I	50	Meningioma	At skull base	No deficit
3	I	34	Postfossa neuroma	No	—
4	I	63	Cavernous aneurysm	At C1	No deficit
5	I	66	Glomus tumor	No	—
6	I	34	Adenoid cystic cancer	No	—
7	II	55	Supraclinoid aneurysm	At C3	No deficit
8	II	63	Petrous bone arachnoid cyst	No	—
9	II	67	Ameloblastoma	No	—
10	III	51	Meningioma	No	—
11	III	53	Squamous cell cancer	No	—
12	III	58	Squamous cell cancer	At skull base	Stroke (see Fig. 4)
13	III	48	Fifth nerve neuroma	No	—
14	III	37	Glomus tumor	No, but clamped 10 min.	No deficit
15	III	45	Adenoid cystic cancer	No	—
16	III	48	Cholesteatoma of petrous apex	No	—

acute surgical occlusion of the artery (Fig. 4). This patient had had a severe compromise of MCA flow with test occlusion. Although initially intact after surgery, the patient was found the following morning to be hemiplegic. He subsequently developed a region of low attenuation on the CT scan that corresponded exactly to the previously demonstrated region of decreased flow during testing. Table 2 summarizes the series.

Discussion

In the past, the accepted method of assessing the adequacy of collateral flow with trial ICA occlusion has involved the measurement of stump pressure and careful neurologic monitoring. Stump pressure measurements have proved to be inaccurate in predicting subsequent neurologic compromise [3]. Detailed neurologic evaluations, especially involving testing of the nondominant hemisphere, can be extremely difficult to accomplish in 15 min in an angiographic suite. But, most important, a detailed examination that fails to detect a neurologic deficit cannot warn a physician of a borderline hemodynamic state that could jeopardize the patient if CBF were further compromised. With severely compromised flow reserves, a transient loss of function or infarction may occur, depending on the duration and depth of the ischemic challenge [4, 5].

Despite testing, there are two ways in which patients may still sustain cerebral infarction hours or days after vessel occlusion. First, emboli to the intracranial circulation can arise from a thrombus within the distal ICA. The risk of this occurring is believed to be minimized by shortening the length of the distal stump by occluding the ICA as cephalad as possible and by administering anticoagulants immediately before and for a period after the occlusion. A second cause for delayed neurologic deterioration is reduced cerebral perfusion after arterial occlusion, even despite normal preliminary neurologic testing with the artery occluded.

Normally, the cerebral circulation maintains a stable blood flow in the range of 55 ml/100 g/min over a broad range of pressure variations. Autoregulation of CBF is lost when arterial pressure is severely compromised [4, 6]. Below a critical pressure, tissue perfusion becomes directly dependent on arterial pressure. CBF then falls as the arterial pressure is reduced, but there is no disturbance of neuronal function until flow values fall to 20 ml/100 g/min and below [5]. For this reason, while an individual undergoing temporary carotid occlusion may remain asymptomatic, he could theoretically have severely compromised blood flow reserves with flow values near 20 ml/100 g/min, and therefore be vulnerable to an ischemic injury if arterial pressure, and therefore CBF, were further compromised [6].

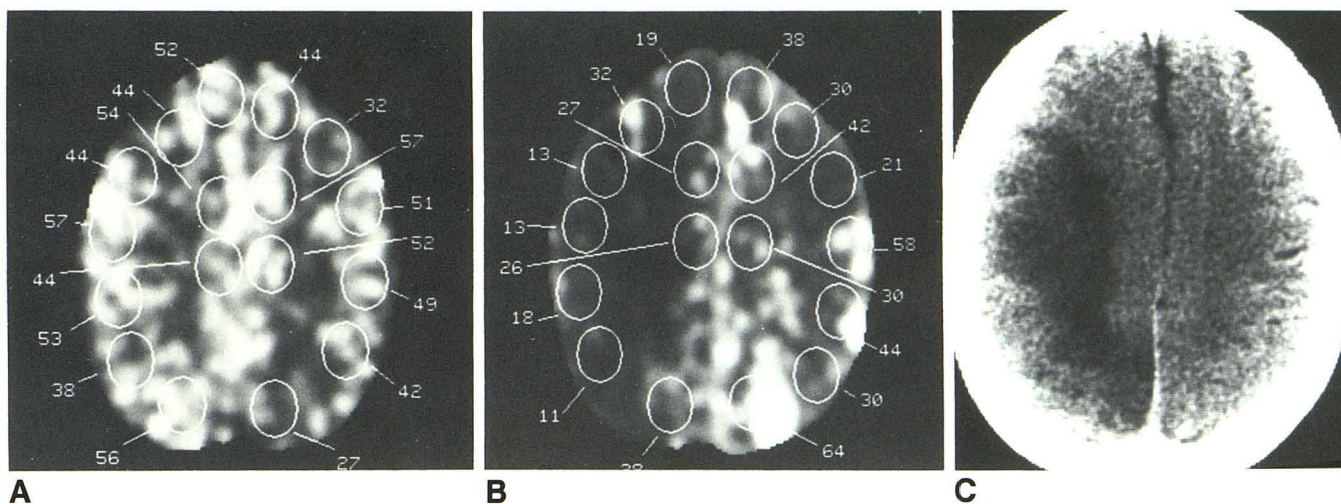


Fig. 4.—Group III—worst-case outcome.
A, Unoccluded study with CBF values shown.
B, Occluded study. Note significant decrease in right hemisphere cerebral blood flow. Patient was grossly intact at this time. During surgery it became necessary to occlude the ICA. A bypass graft was not constructed before occlusion.
C, Postoperative CT scan shows large right hemisphere infarct. Extent and shape of infarct are similar to area of decreased cerebral blood flow.

Ideally, information about CBF, blood volume, oxygen extraction, and metabolism would be assessed with a PET scan in patients undergoing trial ICA occlusion [7–9]. A complete set of all these measurements is not readily available in most institutions. CBF information is probably the single most useful measurement because it is directly coupled to brain function and viability, and it is readily available to the clinician [5]. We and others [10–13] have had extensive clinical experience with xenon/CT CBF imaging and have found it to be a clinically useful method for studying a broad spectrum of neurologic disorders. Although other CBF methodologies should be able to provide this information [14], the data provided by the xenon/CT method lend themselves to more graphic display and analysis of individual vascular compromise. This is indicated by the moderately high-resolution blood flow information coupled with direct anatomic reference provided by the baseline CT image.

Cerebral blood flow information heightens our awareness of those individuals who would be placed in a precarious hemodynamic state if the ICA were acutely sacrificed. Patients classified as group I had normal CBF despite ICA occlusion and apparently had an abundant collateral supply. It was presumed they would tolerate ICA occlusion without incident even if some degree of hypotension were to have occurred. Group-II patients appeared to have satisfactory collaterals, although perhaps less so than those in group I, and remained neurologically intact even with permanent occlusion, assuming no significant lowering of systemic blood pressure. Group-III patients had a severe compromise of vascular reserves on at least the side of the arterial occlusion and apparently had minimal collateral potential. We believed these patients were at maximum risk for delayed neurologic injury after ICA occlusion because of a compromised hemodynamic state that would not tolerate even mild hypotension. Vascular reconstruction might be necessary in such patients.

Cerebral blood flow information obtained by the xenon/CT CBF method has proved to be a useful means of studying the response of the cerebral circulation to large-vessel compromise. While alteration of the neurologic examination does provide a rough indication of severely compromised CBF with test occlusion, it offers no information about the status of CBF reserves. We currently use the clinical examination as a means of identifying those patients with adequate collateral capacity to tolerate ICA occlusion long enough to undergo a xenon/CT CBF examination. We believe that the CBF study described here helps identify the high-risk patients and, by increasing our awareness of their precarious state, reduces their risk of stroke from surgical ICA occlusion.

REFERENCES

1. Gur D, Wolfson SK, Yonas H, et al. Progress in cerebral vascular disease: LCBF by xenon-enhanced CT. *Stroke* **1982**;13:750–758
2. Gur D, Good WF, Wolfson SK Jr, Yonas H, Shabason L. *In vivo* mapping of local cerebral blood flow by xenon enhanced computed tomography. *Science* **1982**;5:1267–1268
3. Kelly JJ, Collow TF, McBride K, et al. Failure of carotid stump pressures. *Arch Surg* **1979**;114:1361–1366
4. Vorstrup S, Paulson OB, Lassen NA. How to identify hemodynamic cases. In: Spetzler RS, ed. *Cerebral revascularization for stroke*. New York: Thieme, **1984**:120–126
5. Jones TH, Morawetz RB, Crowell RM, et al. Thresholds of focal cerebral ischemia in awake monkeys. *J Neurosurg* **1981**;54:773–782
6. Halsey JH Jr, Morawetz RB, Blauenstein UW. The hemodynamic effect of STA-MCA bypass. *Stroke* **1982**;13:163–167
7. Gibbs J, Wise R, Leenders K, et al. The relationship of regional cerebral blood flow, blood volume, and oxygen metabolism in patients with carotid occlusion: evaluation of perfusion reserve. *J Cereb Blood Flow Metab* **1983**;3:S590–S591
8. Lenzi GL, Frackowiak RS, Jones T. Cerebral oxygen metabolism and blood flow in human cerebral ischemic infarction. *J Cereb Blood Flow Metab* **1982**;2:321–335
9. Baron JC, Bousser MG, Rey A, et al. Reversal of focal "misery-perfusion syndrome" by extra-intracranial arterial bypass in hemodynamic cerebral

- ischemia. A case study with ^{18}O positron emission tomography. *Stroke* **1981**;12:454-459
10. Yonas H, Good WF, Gur D, et al. Mapping cerebral blood flow by xenon enhanced computed tomography: clinical experience. *Radiology* **1984**;152:425-442
 11. Yonas H, Steed DL, Latchaw RE, Gur D, Peitzman AB, Webster MW. Relief of non-hemispheric symptoms in low flow states by anterior circulation with vascularization: physiological approach. *J Vasc Surg* **1987**;5(2):289-297
 12. Yonas H, Wolfson SK Jr, Gur D, et al. Clinical experience with the use of xenon-enhanced CT blood flow mapping and cerebral vascular disease. *Stroke* **1984**;15:443-449
 13. Meyer JS, Nakajima S, Dkabe E, et al. Redistribution of cerebral blood flow following STA/MCA bypass in patients with hemispheric ischemia. *Stroke* **1982**;13:774-784
 14. Schmiedek P, Gratzl O, Spetzler R, et al. Selection of patients for extra-intracranial bypass surgery based on rCBF measurements. *J Neurosurg* **1976**;44:303-312