

CT and MR Studies of Methylmalonic Acidemia

Cosma Felice Andreula,¹ Roberto De Blasi, and Aristide Carella

Methylmalonic acidemia (MMA) is a disorder of organic acid metabolism. It consists of a group of biochemically and genetically distinct disorders that produces a block in the conversion of methylmalonyl-CoA to succinyl-CoA, with consequent accumulation of methylmalonate in the blood and urine, secondary hyperammonemia, and often severe ketoacidosis [1].

Methylmalonic acid is part of the organic and amino acid oxidative process, in which the methylmalonyl-CoA is converted to succinyl-CoA by methylmalonylmutase, an enzyme whose cofactor is a cobalamin coenzyme (5'-deoxyadenosyl cobalamin). MMA is caused by absence or mutation of methylmalonylmutase or by defective synthesis of the coenzyme, and is transmitted in an autosomal recessive inheritance pattern [1]. Rarely, MMA can be produced by a deficit of the racemase that converts D-methylmalonyl-CoA to L-methylmalonyl-CoA [2]. In the affected patients, an increase of methylmalonic acid in blood produces marked ketoacidosis, lethargy, and coma [1, 3-5]. The long-lasting metabolic disorder produces physical and mental delay.

Aicardi [3] has reviewed the clinical and neuroradiologic features of MMA. CT demonstrates, even in the acute phase, areas of hypodensity affecting the pallidal nuclei bilaterally, which do not enhance after infusion of iodinated contrast medium, although enhancement can occur in the subacute phase [5]. In our case, immediately after the onset of the disease, MR showed the cytotoxic edema affecting the pallidal nuclei bilaterally, characterized by low signal intensity on T1-weighted images and high signal intensity on T2-weighted images. The neuroradiologic follow-up showed the progressive changes of necrosis in these lesions.

Case Report

A baby girl, whose parents were cousins, was born after a full-term uncomplicated gestation. Her weight at birth was 3.2 kg. An older sister had died soon after birth from respiratory distress. At birth, the patient suffered generalized seizures without hypoxia. Psychomotor development was normal until the age of 24 months, when she was hospitalized with fever and generalized atonic seizures. Neurologic examination showed lethargy, diffuse muscular hypotonia, and a right pyramidal hemisyndrome.

CT examination (CE 12000, CGR, Paris, France) during the acute phase revealed diffuse hypodensity of the pallidal nuclei and posterior limbs of the internal capsules, more evident on the left than on the right (Fig. 1A). MR studies were performed on a 0.5-T superconducting magnet (MAX Plus, GE, Milwaukee, WI). Sagittal T1-weighted images, 500/25/2 (TR/TE/excitations), were acquired with a 25-cm field of view, 5-mm slice thickness with 1-mm interslice gap, and 256 × 256 acquisition matrix. T1-weighted IR transaxial images (1250/400,25/2) and intermediate and T2-weighted transaxial images (2000/25,100/2) were acquired by using a 5-mm slice thickness with 1-mm interslice gap, 25-mm field of view, and 256 × 256 acquisition matrix. The MR studies confirmed the cytotoxic edema involving the globi pallidi and the internal capsule. The signal of the lesions appeared mildly hypointense on the T1-weighted images, iso- to hyperintense on the proton-density images, and hyperintense on the T2-weighted images (Fig. 1B).

Four days later, after the appearance of hepatomegaly, there was hyperammonemia (110 mg/dl; normal range, 30-70 mg/dl) and very high levels of blood pyruvate (55 mg/dl; normal range, 5.7-22) and lactate (1.0 mg/dl; normal range, 0.36-0.59), which reached their maximum values almost 20 days after the onset of symptoms (74 mg/dl and 1.57 mg/dl, respectively). Serum glycine also markedly increased, with a peak on the 14th day (1268 μmol/l; normal range, 158-302).

The second CT examination (9800, GE, Milwaukee, WI), performed 20 days after the onset of the disease, revealed dilatation of the ventricular system and subarachnoid spaces. At this time the presence of methylmalonate was discovered in the urine (514 mmol/d creatinine; upper limit of normal, 4.0 mmol/d). The patient was given a low protein diet. Therapy with vitamin B₁₂ was begun, which quickly improved the mental status and muscular hypotonia. Motor deficit and dysphasia showed slower improvement.

An MR examination at age 2 years 6 months revealed necrosis of the pallidal nuclei with normal CSF spaces. The lesions appeared hypointense on T1-weighted images and hyperintense on T2-weighted images. Clinical examinations at 8, 15, and 22 months, respectively, from the onset of the disease demonstrated only slight right hemiparesis. The last MR examination at age 3 years 9 months confirmed the bilateral pallidal necrosis and normal CSF spaces (Figs. 1C and 1D).

Discussion

MMA is a disease of organic acids, genetically transmitted via a recessive autosomal mode of inheritance. The appear-

Received July 10, 1990; revision requested August 31, 1990; revision received December 11, 1990; accepted December 12, 1990.

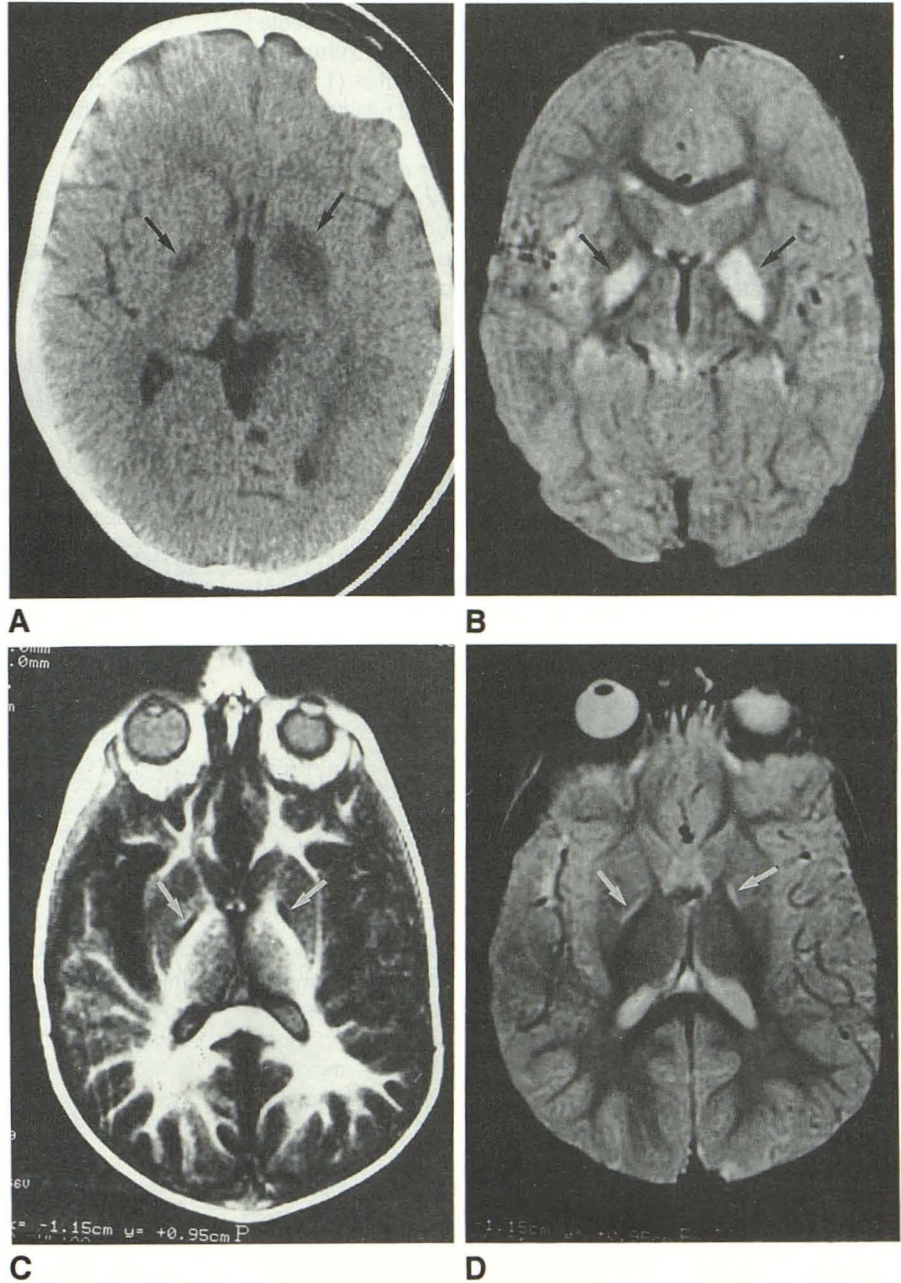
¹ All authors: Department of Neuroradiology, University of Bari, Piazza Giulio Cesare, 11, 70124 Bari, Italy. Address reprint requests to C. F. Andreula.

Fig. 1.—CT and MR studies in young girl with methylmalonic acidemia.

A, CT scan obtained at onset of symptoms shows diffuse hypodensity of globi pallidi (arrows), more evident on the left.

B, T2-weighted MR image (1500/100/2) obtained during same period confirmed edema of pallidal nuclei (arrows).

C and D, Third MR examination, performed 22 months after onset of symptoms. T1-weighted IR image (1500/400/25) (C) and T2-weighted SE image (2000/100) (D) show continued pallidal necrosis (arrows) and normal CSF spaces.



ance of ketoacidosis in the neonate or in the first year of life should suggest deranged organic acid metabolism, such as methylmalonic aciduria, especially in the presence of acute or subacute encephalopathy. The presence of ketoacidosis in MMA allows differentiation from nonketotic hyperglycinemia, which has a similar clinical onset of vomiting and lethargy in early infancy and a similar high level of glycine in blood and urine, but an absence of ketoacidosis [6, 7].

The bilateral pallidal necrosis, revealed by neuroimaging techniques, is probably due to acute respiratory acidosis with cell necrosis. These events likely result from intracellular increase of methylmalonate that, with the block of mitochondrial respiration, progressively alters cellular respiratory dy-

namics. The inability of cells to compensate for hyperacidosis due to an intercurrent disease could cause breakdown of cellular energy production and subsequent cellular necrosis. The pallidal involvement is probably due to the high energy level in that location in the first year of life, with rich vascularization, elevated metabolism, and consequent high energy demands. With increasing age, this high energy role of the pallidal nuclei is progressively lost.

The CT and MR findings of MMA, even considering the few cases reported, allow us to suppose that the involvement of a specific structure is related to the elevated metabolic level and the high energy demands in a particular time of life. Of the nine cases of MMA studied by CT that have been reported

[1, 3-5, 8], seven of them (older than 8 months) revealed bilateral hypodensity of the pallidum while the other two showed diffuse low density of the white matter (1 and 4 months, respectively). Our patient had bilateral pallidal necrosis at the age of 24 months.

MMA can be differentiated from the other disorders associated with bilateral necrosis of the basal ganglia that have an acute or subacute course in infancy. In subacute sclerosing panencephalitis, or Leigh disease, the basal ganglia are mainly involved (preferentially the putamina), but CT hypodensity may be seen in any part of the central gray matter, cerebellum, or hemispherical white matter. MR shows lesions of decreased intensity on T1-weighted images and of increased intensity on T2-weighted images in the putamen, white matter of the cerebral and cerebellar hemispheres, and even the brainstem [9].

Another rare disease to differentiate is idiopathic bilateral infantile striatal necrosis, a disease of unknown or possibly infectious origin [3], which appears after mumps or influenza. CT shows signs similar to those observed in MMA [3]. Bilateral pallidal necrosis has been described in carbon monoxide and cyanide poisoning [3, 4, 10], methanol poisoning [3-8], and glutaric [3, 8, 11] and propionic acidemia [1-8]. Nevertheless, in carbon monoxide, cyanide, and methanol poisoning the pertinent history should lead to the diagnosis; in propionic acidemia, analysis of the urine, plasma, and CSF organic acids will confirm the metabolic pathogenesis of the lesions. In glutaric aminoacidemia type 1, the laboratory investigations and the elective localization in the neostriatum may differentiate it from MMA.

Because of the CT and MR similarities of so many diseases with pallidal necrosis, MMA can only be biochemically distinguished from other disorders. However, CT and MR are important factors in detection of this disease.

REFERENCES

1. Gebarski SS, Gabrielsen TO, Knake JE, Latack JT. Cerebral CT findings in methylmalonic and propionic acidemias. *AJNR* 1983;4:955-957
2. Kang ES, Snodgrass PJ, Gerald PS. Methylmalonic coenzyme A racemase defect. Another cause of methylmalonic aciduria. *Am J Med* 1970;48:390-391
3. Aicardi J. Some disorders of the central grey matter in children: clinical and radiological diagnosis. In: *Clinical and experimental neurology*. Sydney: Tyrer & Eadie, 1985:1-25
4. Korf B, Wallman JK, Levy HL. Bilateral lucency of the globus pallidus complicating methylmalonic acidemia. *Ann Neurol* 1986;20:364-366
5. Heidenreich R, Natowicz M, Hainline BE, et al. Acute extrapyramidal syndrome in methylmalonic acidemia: metabolic stroke involving the globus pallidus. *J Pediatr* 1988;113:1022-1027
6. Press GA, Barshop BA, Haas RH, Nyhan WL, Glass RF, Hesselink JR. Abnormalities of the brain in nonketotic hyperglycinemia: MR manifestations. *AJNR* 1989;10:315-321
7. Shuman RM, Leech RW, Scott CR. The neuropathology of the nonketotic and ketotic hyperglycinemias: three cases. *Neurology* 1978;28:139-146
8. Roodhooft AM, Baumgartner ER, Martin JJ, Blom W, Van Acker KJ. Symmetrical necrosis of the basal ganglia in methylmalonic acidemia. *Eur J Pediatr* 1990;149:582-584
9. Tsuchiya K, Yamauchi T, Furui S, Suda Y, Takenaka E. MR imaging vs CT in subacute sclerosing panencephalitis. *AJNR* 1988;9:943-946
10. Horowitz AL, Kaplan R, Sarpel G. Carbon monoxide toxicity: MR imaging in the brain. *Radiology* 1987;162:787-788
11. Lipkin PH, Roe CR, Goodman SI, Batshaw ML. A case of glutaric acidemia type I: effect of riboflavin and carnitine. *J Pediatr* 1988;112:62-65

The reader's attention is directed to the commentary on this article, which appears on the following pages.