

MR Imaging in an Experimental Model of Brain Tumor Immunotherapy

Francis Blankenberg¹
 Frances K. Conley^{2,3}
 Jim Sayre¹
 Dieter Enzmann¹

A murine model of implanted CNS neoplasia was used to study a new form of brain tumor immunotherapy with intralesional *Corynebacterium parvum* (*C. parvum*). Assessment of treatment protocols has been limited by the inability to assess, noninvasively, tumor burden and/or the inflammatory reaction induced in the murine brain by treatment with *C. parvum*. This study demonstrates that contrast-enhanced MR imaging can monitor in vivo tumor burden and the immune response to intracerebral *C. parvum*. KHT murine sarcoma was stereotaxically implanted into the right frontal lobe of C3H/HeN mice at doses of 10,000 and 50,000 tumor cells. The KHT sarcoma is 100% fatal in untreated mice. Therapy consisted of an intraperitoneal injection of 350 μ g of killed *C. parvum* 1 day after tumor implantation followed by 70 μ g of *C. parvum* stereotaxically injected into the tumor 5 days after implantation. MR imaging was performed on mice injected with saline only, *C. parvum* only, tumor only, and tumor treated with *C. parvum*. *C. parvum* alone elicited an intense transitory mononuclear cell inflammatory reaction in the meninges, ependyma, and to a variable degree at the injection site. The inflammatory response reached a peak 2 weeks after intracerebral injection.

Contrast-enhanced MR imaging was able to detect the presence and severity of *C. parvum*-induced inflammation, which decreased 3 weeks after intracerebral injection. The transitory nature of this type of inflammation should allow its differentiation from tumor in subjects undergoing serial scanning following intracerebral injection of *C. parvum* as a form of brain tumor immunotherapy.

AJNR 12:543-548, May/June 1991

Despite rapid development of sophisticated imaging for early tumor detection and advances in chemotherapy and radiotherapy, the survival rate following treatment of high-grade primary or metastatic tumors in the brain remains limited [1]. Recently, considerable interest has focused on the possibility that immunomodulation alone or in conjunction with traditional therapy might be efficacious against neoplasia of the CNS. Conley and Remington [2] and Conley [3, 4] demonstrated that mice chronically infected with *Toxoplasma gondii*, an obligate intracellular organism, developed a mononuclear cell infiltrate in the brain in response to infection, and acquired the ability to resist growth of both implanted and metastatic tumor of the CNS. These data suggested that resistance to tumor growth was secondary to nonspecific inflammatory cellular responses induced by the infecting organism.

Further work to develop immunotherapy free from the obvious limitations imposed by use of live organisms employed a killed suspension of *Corynebacterium parvum* (*C. parvum*), which is known to be a strong stimulator of nonspecific cellular immune responses and has demonstrated antitumor activity against a variety of animal [5-9] and human [10-12] neoplasms. Mice that receive a systemic priming dose of killed *C. parvum* suspension followed by direct intracerebral injection of killed *C. parvum* suspension into the tumor bed develop an intense mononuclear cell inflammatory response in the brain and have the ability to resist the growth of both implanted and metastatic tumor [13].

Received July 5, 1990; revision requested August 28, 1990; revision received December 3, 1990; accepted December 3, 1990.

This work was supported by funds from the Research Committee of the Department of Radiology and Nuclear Medicine, Stanford University, and by the Veterans Administration.

¹ Department of Radiology, #S072, Stanford University School of Medicine, Stanford, CA 94305. Address reprint requests to D. Enzmann.

² Department of Surgery, Division of Neurosurgery, Stanford University School of Medicine, Stanford, CA 94305.

³ Department of Neurosurgery, Veterans Administration Medical Center, Palo Alto, CA 95304.

0195-6108/91/1203-0543
 © American Society of Neuroradiology

As clinical immunotherapeutic trials using intracerebral *C. parvum* begin with glioma patients (FK Conley, unpublished data), it will be necessary to study the imaging characteristics of this therapy by using animal models. The present study used MR imaging to visualize implanted tumor in the brains of mice and to explore the imaging characteristics of the inflammatory response induced in the brain by *C. parvum* immunotherapy in a previously described immunotherapeutic model [13].

Materials and Methods

Mice

C3H/HeN/MTV-negative female mice were obtained from Simonson Laboratories, Gilroy, CA, and were 3–5 months old when tumors were implanted. For each experiment, mice were age-matched and were housed under AAALAC animal laboratory conditions.

Tumors

Cell lines of KHT sarcoma, a nonimmunogenic syngeneic tumor that arose spontaneously in a C3H mouse, were maintained in vitro under conditions described previously [13]. All animal inoculations were done with cell populations in the exponential growth phase and had viability of greater than 90% as determined by trypan blue exclusion. The method of stereotaxic intracerebral inoculation into the right frontal lobe has been described [2] and was performed under continuous methoxyfluorane anesthesia. The tumor dose was 50,000 or 10,000 cells/mouse brain in a total volume of 10 μ l. Control mice received intracerebral injections of saline.

Immunomodulation

A suspension of killed *C. parvum* (7 mg/ml dry wt) was purchased from Wellcome Research Laboratories, Beckenham, Kent, England. One day after tumor cell inoculations mice received an intraperitoneal injection of 350 μ g of *C. parvum* in a volume of 0.2 cm³. Five days after tumor implantation mice received an intracerebral dose of 70 μ g of *C. parvum* stereotaxically into the right frontal lobe in the same vicinity as the tumor. Prior exposure to *C. parvum* antigen with intraperitoneal injections of *C. parvum* was needed to promote the intracerebral tumoricidal inflammation of intracerebral *C. parvum*, as per Kennedy and Conley [13]. Tumor-bearing control mice received saline injections. One group of mice was imaged after receiving only *C. parvum* treatment in the absence of tumor.

Imaging

A 4-in. magnetically coupled single-turn solenoid coil was used with a 1.5-T Signa system (GE). For sedation prior to imaging, mice received intraperitoneal injections of ketamine (50 mg/kg) plus xylazine (5 mg/kg). Sagittal and coronal T1-weighted spin-echo images, 800/20/4 (TR/TE/excitations), with a 256 \times 256 matrix and 8-cm field of view, were obtained before and after IV injection of 0.5 mmol/kg of gadopentetate dimeglumine. To reduce mortality and improve access to the tail vein, injections of gadopentetate dimeglumine were given prior to anesthesia. Mice were imaged an average of 20–30 min after IV administration of gadopentetate dimeglumine. By using a Styrofoam platform with plastic head restraints it was possible to image two mice simultaneously. A slice thickness of 3 mm and skip of 0.5 mm were used for both sagittal and coronal images. One slice for both sagittal and coronal images was placed through the center of the right orbit and both orbits, respectively, in order to standardize the observed anatomy.

In our pilot studies we investigated this tumor by using T2-weighted images with flow compensation and the following parameters: TR = 2500, TE = 30, 80; excitations = 2; matrix = 256 \times 256; field of view = 8 cm; slice thickness = 3 mm with a 0.5-mm skip. These images were time-consuming, of limited signal-to-noise ratio, and did not provide information different from the higher signal-to-noise ratio on the T1-weighted images when compared with neuropathologic findings. The tumor and inflammatory changes were all well delineated by contrast-enhanced T1-weighted images. In addition, T2-weighted images suffered from low-signal magnetic susceptibility effects caused by intratumoral hemorrhage seen in this model. This hindered tumor investigation. For these reasons T2-weighted images were not included in this protocol.

Histologic Examination of the Brains

After imaging, mice were sacrificed with an overdose of methoxyfluorane. Brains were removed from the cranium and placed in formalin, acetic, alcohol solution. Coronal sections were cut at 2-mm intervals from each brain, with one section passing through the center of the tumor/*C. parvum* injection site and prepared for routine light microscopy. Sections were cut at 5 μ m and stained with H and E.

Results

Saline-Injected Mice

Two non-tumor-bearing sham controls injected stereotaxically in the right frontal lobe with normal saline were imaged and sacrificed on the seventh day after injection. The saline controls did not show any abnormal contrast enhancement or other abnormality at day 7. There was no significant inflammation or hemorrhage at the injection site as seen histologically.

Mice Injected with *C. parvum* Only

A total of 17 non-tumor-bearing mice were stereotaxically injected in the right frontal lobe with 70 μ g of *C. parvum* 4 days after systemic intraperitoneal injection of 350 μ g of *C. parvum*. The mice were imaged and sacrificed on day 5 ($n = 5$), day 6 ($n = 3$), day 13 ($n = 6$), and day 19 ($n = 3$) after intracerebral injections (Table 1).

On days 5 and 6 after intracerebral injection of *C. parvum*, variable patchy contrast enhancement over the lateral convexity of the right frontal lobe and the interhemispheric fissure was detected in all animals. Three animals demonstrated moderate ependymal enhancement in both lateral ventricles. By day 13, five of six animals showed moderate to marked enhancement of the ependyma. Diffuse, symmetric leptomeningeal enhancement was seen in the same animals that demonstrated ependymal enhancement (Fig. 1). The injection site itself demonstrated variable enhancement, which at times (in two of six animals) was sufficiently intense so as to mimic a tumor-bearing mouse. At day 19 the meningeal, ependymal, and injection site enhancement, although still detectable, was less intense than on day 13. At no time was abnormal signal intensity noted on the precontrast T1-weighted images of the *C. parvum* control mice.

Histologic sections revealed a dense mononuclear cell infiltrate in the meninges, ependyma, cerebral parenchyma, and occasionally in the choroid plexus (Fig. 2). These regions

TABLE 1.

| | No. of Days After Intracerebral Injection | No. of Animals Imaged and Sacrificed | Enhancement ^a |
|---|---|--------------------------------------|---|
| Saline (controls) | 7 | 2 | None |
| <i>C. parvum</i> (controls) | 5–6 | 8 ^b | +1 interhemispheric fissure enhancement in all animals. Variable +1 patchy enhancement of lateral convexity (R) frontal lobe. Three animals with +1 ependymal enhancement of both lateral ventricles. |
| | 13 | 6 ^c | 5 of 6 animals +2 ependymal and diffuse symmetric leptomeningeal enhancement. 2 of 6 animals +2 enhancement of injection site. |
| | 19 | 3 ^d | Remainder of animals (none to +1) injection site enhancement. +1 leptomeningeal, ependymal, and injection site enhancement of all animals. |
| 5 × 10 ⁴ cells of KHT sarcoma (controls) D _T = 1.1 days ^e | 2 | 3 | None. |
| | 7 | 6 | None. |
| | 8 | 1 | +2 homogeneous enhancement of tumor ≈ 1.2 mm diameter (R) frontal lobe. |
| | 13 | 3 | +2 homogeneous enhancement of tumor ≈ 3.3 mm diameter (R) frontal lobe. |
| 1 × 10 ⁴ cells of KHT sarcoma (controls) | 16 | 3 | +2 homogeneous enhancement of tumor ≈ 5.0–6.0 mm diameter (R) frontal lobe. |
| | 10 | 5 | None. |
| | 16 | 4 | +2 homogeneous enhancement of tumor ≈ 3.0–4.0 mm diameter (R) frontal lobe. |
| | 17 | 1 | +2 homogeneous enhancement of tumor ≈ 3.0 mm diameter (R) frontal lobe. |

^a +1 = mild to moderate enhancement, +2 = marked enhancement.

^b First histologic evidence of the mononuclear infiltrate of the leptomeninges and ependyma.

^c Dense infiltration of the leptomeninges and ependyma with mononuclear cells. In addition, there was hyperplasia of the ependymal lining and choroid plexi, which normally are one-cell thick.

^d Decrease in the mononuclear infiltrates compared with day 13.

^e D_T = Average doubling time of tumor using the average tumor volumes from days 8, 13, and 16.

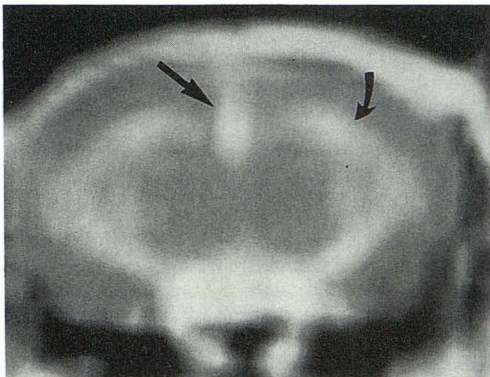


Fig. 1.—Postcontrast coronal T1-weighted image (800/20) through ventricles 13 days after intracerebral injection of *C. parvum*. Note increased signal of interhemispheric fissure (straight arrow) and bilateral ependymal enhancement of lateral ventricles (curved arrow).

corresponded to the areas of contrast enhancement seen on the T1-weighted MR scans. The inflammatory changes were detectable histologically at day 7, peaked at day 14, and decreased significantly by 21 days after intracerebral injection of *C. parvum*.

Mice Injected with 50,000 KHT Tumor Cells

A total of 16 mice were stereotaxically injected, imaged, and sacrificed on day 2 ($n = 3$), day 7 ($n = 6$), day 8 ($n = 1$), day 13 ($n = 3$), and day 16 ($n = 3$) (Table 1).

Tumor could not be imaged in any mouse on days 2 or 7. When the tumor reached a diameter of 1.0 mm or greater it could be imaged consistently with gadopentetate dimeglu-

mine (Fig. 3A). In all animals in which tumor was detected by MR, tumor was also confirmed by histological examination (Fig. 3B). Smaller tumors could not be imaged, although microscopic deposits less than 0.1 mm in diameter could be found histologically as early as day 2. The KHT sarcoma, as expected, was a rapidly growing tumor with a doubling time as measured by MR of approximately 1 day. By day 16 after implantation of 50,000 KHT sarcoma cells, a tumor mass 5–6 mm in diameter was produced. This was a nearly lethal tumor burden given the average anteroposterior and coronal dimensions of a murine brain of 1–1.2 cm (Fig. 4), and that the mean survival time of untreated animals was 22 days after intracerebral injection of 50,000 KHT sarcoma cells in the model detailed in Kennedy and Conley [13].

The tumors were of the same signal intensity as normal murine cerebral tissue on noncontrast T1-weighted scans. Tumors exhibited intense homogeneous enhancement after administration of gadopentetate dimeglumine. Hemorrhage on noncontrast T1-weighted scans was seen only in large 5–6 mm masses as heterogeneous areas of slightly decreased signal intensity, which at histology consisted of microscopic collections of necrotic debris and red blood cells (Figs. 4A and 4C). Focal bleeding into the tumor, however, was seen histologically in most animals by day 13. The KHT sarcoma could spread to the contralateral hemisphere if the injections leaked into the ventricle (Figs. 4B and 4C).

Mice Injected with 10,000 KHT Tumor Cells

A total of 10 mice were stereotaxically injected with the lower dose of 10,000 cells, imaged, and sacrificed on day 10 ($n = 5$), day 16 ($n = 4$), and day 17 ($n = 1$). Results of tumor

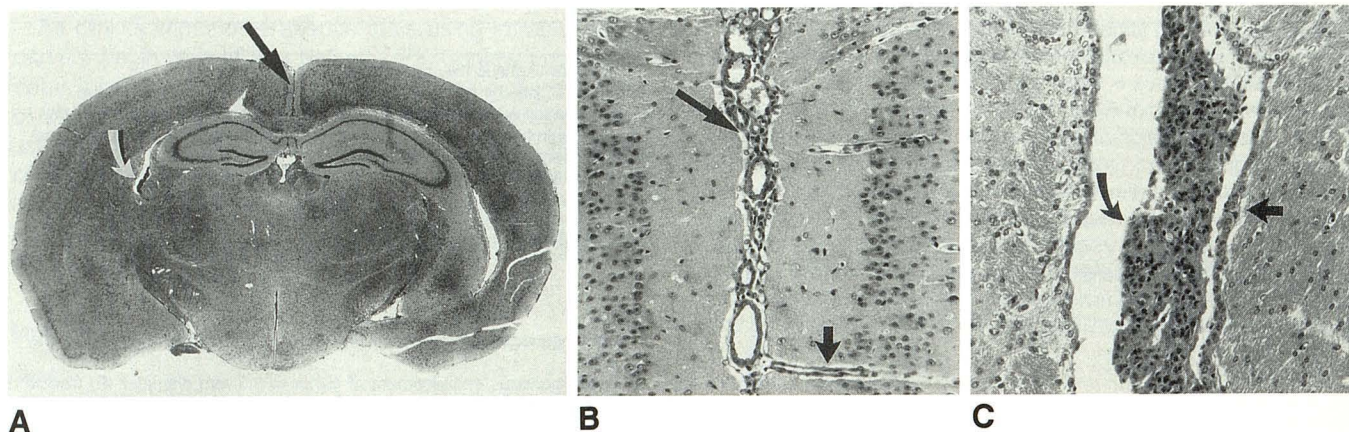


Fig. 2.—Coronal H and E section through ventricles of the animal imaged in Fig. 1 13 days after intracerebral injection of *C. parvum*.
A, Whole mount (x2.5). *Straight arrow* points to interhemispheric leptomeningitis; *curved arrow* shows ependymitis and choroiditis of right frontal horn.
B, Interhemispheric leptomeningitis evidenced by marked meningeal mononuclear infiltrate (*long arrow*) (x20). Note infiltrate into Virchow-Robin spaces (*short arrow*) (x20).
C, Ependymitis and choroiditis. Abundant mononuclear infiltrate of choroid plexus (*curved arrow*) and adjacent ependyma (*straight arrow*) (x20).

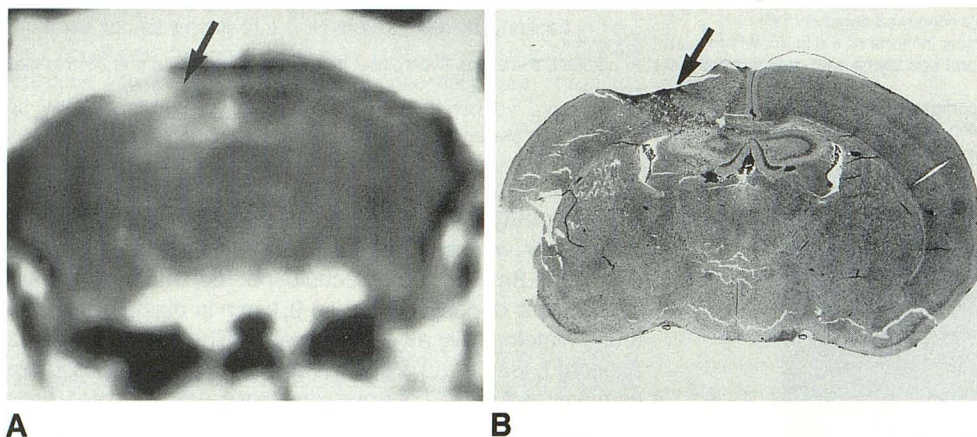


Fig. 3.—Comparison of MR image with whole brain mount 8 days after intracerebral injection of 50,000 KHT sarcoma cells.
A, Postcontrast coronal T1-weighted MR image (800/20) through frontal lobes shows tumor (0.8 x 1.2 mm) (*arrow*) in right frontal lobe with extension along injection tract seen after contrast enhancement.
B, Coronal H and E section (x2.5) of brain tumor in Fig. 3A shows close correlation of tumor and contrast enhancement. *Arrow* points to right frontal lobe tumor.

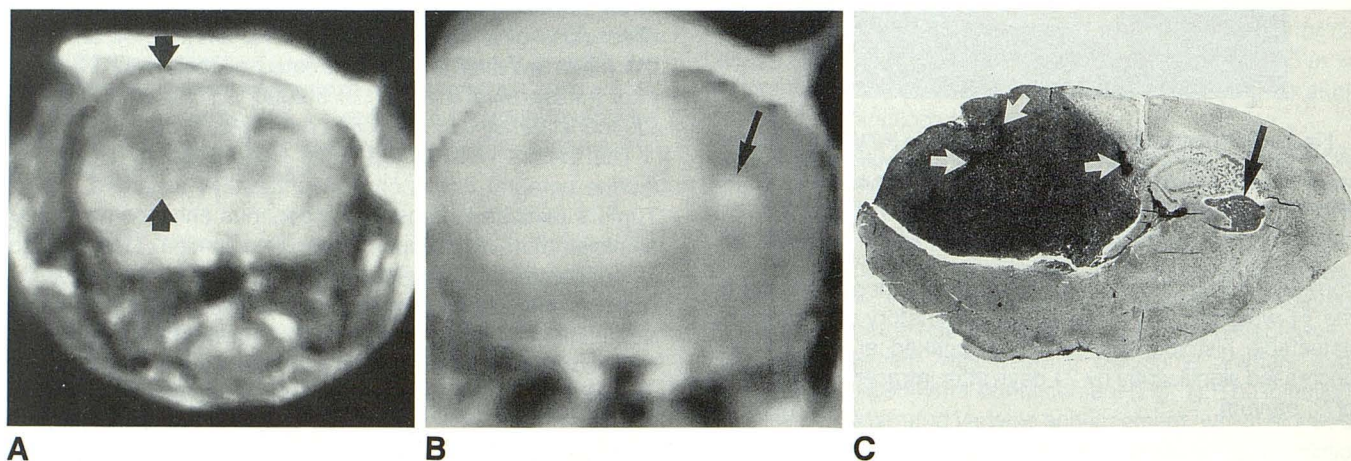


Fig. 4.—Comparison of MR image with whole brain mount 16 days after intracerebral injection of 50,000 KHT sarcoma cells.
A, Precontrast coronal T1-weighted MR image (800/20) shows large right frontal lobe tumor (*arrows*) containing heterogeneous areas of low signal intensity as compared with surrounding brain parenchyma.
B, Postcontrast coronal T1-weighted MR image (800/20) shows entire tumor enhancing nearly homogeneously. A small 0.5-mm focus of tumor is seen extending into left hemisphere (*arrow*).
C, Coronal H and E section (x2.5) of brain shows tumor as a dark area. There is close correlation with tumor size as depicted by postcontrast MR. Spread across midline is confirmed (*black arrow*). Note that the KHT sarcoma tends to be intrinsically hemorrhagic histologically when it approaches a lethal size. *White arrows* indicate focal collections of blood and necrotic debris. This precluded the use of T2-weighted imaging for accurate evaluations of tumor size.

growth and appearance were similar to those seen with 50,000 tumor cells, except the average tumor size was found to lag by 2–3 days as would be expected with a tumor doubling time of 1 day (Table 1).

Effect of Treating Tumor with C. parvum (10,000 and 50,000 KHT Tumor Cells)

A total of 19 mice were injected with 10,000 KHT tumor cells and treated with an intraperitoneal injection of *C. parvum* on day 1 followed by an intracerebral injection of *C. parvum* on day 4. Mice were imaged and sacrificed on day 16 ($n = 8$) and day 30 ($n = 6$) after tumor implantation. Five animals were treated with intraperitoneal *C. parvum* on day 7 and then were imaged on day 10, after which an intracerebral injection of *C. parvum* was given. Of these five animals, two were also imaged on day 17. Another group of eight mice, implanted with 50,000 KHT tumor cells followed by intraperitoneal and intracerebral *C. parvum* injections on day 1 and day 4, respectively, were imaged on day 16 after injection of tumor (Fig. 5). Five of these animals were reinjected with intracerebral *C. parvum* on day 17; these animals were imaged and sacrificed on day 21 (Table 2).

The time course of the ventricular and meningeal inflammation of tumor-bearing mice treated with *C. parvum* was similar to *C. parvum* control mice. Of the 19 animals injected with 10,000 KHT tumor cells, only four animals developed histologically verified tumor in the time period studied. Of the eight mice injected with 50,000 KHT tumor cells, two had histologically confirmed tumor. Owing to technical difficulty (i.e., IV access, respiratory arrests with prolonged anesthesia in ill animals) only three tumor-bearing mice from either tumor cell dose were imaged before and/or after retreatment with intracerebral *C. parvum*. Therefore, the imaging characteristics of possible tumor regression as a result of therapy with *C. parvum* could not be determined. In mice free of tumor at autopsy, contrast enhancement at the injection site was variable but often similar to those animals with demonstrated

macroscopic tumor. The curvilinear ependymal and leptomeningeal enhancement due to *C. parvum*-induced inflammation, however, was easily distinguished from tumor.

Discussion

Cerebral inflammation in the form of diffuse leptomeningitis and ependymitis is a prominent neuropathologic feature of intracranial immunotherapy with *C. parvum*. These inflammatory changes disrupt the blood-brain barrier and can therefore be demonstrated by the administration of a contrast agent such as gadopentetate dimeglumine. The inflammatory changes were detected by gadopentetate dimeglumine-enhanced MR, and severity of inflammation could be assessed by the degree of contrast enhancement. There was some overlap between the appearance of tumor at the injection site and that of parenchymal inflammatory response induced by *C. parvum*. However, there was no meningeal or ependymal enhancement seen in untreated tumor-bearing mice. The peak leptomeningeal and ependymal enhancement was detected at 2 weeks in *C. parvum* controls and in the *C. parvum*-treated animals, which matched the histological appearance of inflammatory changes seen in the brains of these mice (Table 1).

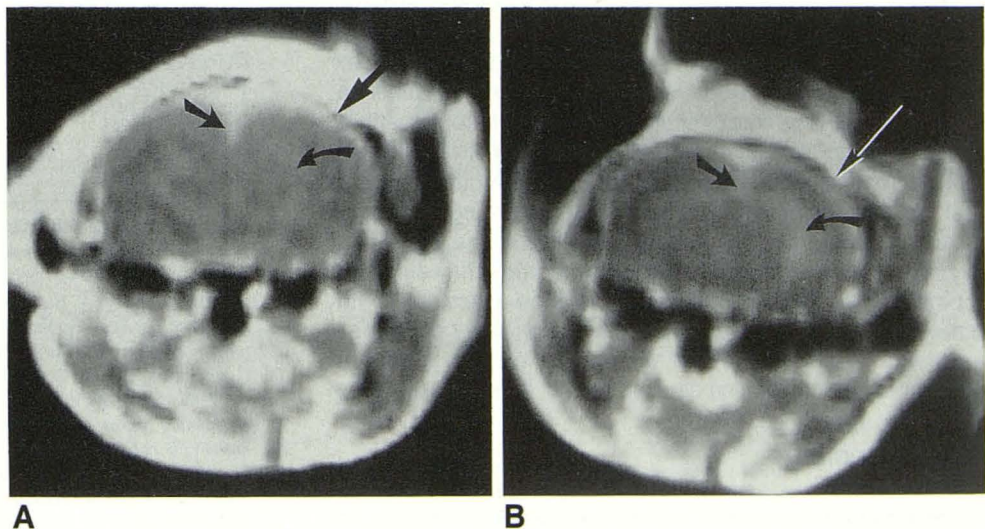
Mice initially treated and then retreated with *C. parvum* demonstrated a similar time course of leptomeningeal and ependymal enhancement as did *C. parvum* control animals that received only a single injection (Table 2). The fact that enhancement was not consistently detected after reinjection of intracerebral *C. parvum* probably reflects the fact that only 4 days elapsed between the initial scan, reinjection, and follow-up scan.

The purpose of this study was to determine the MR imaging characteristics of this tumor and immunotherapy model. Contrast-enhanced T1-weighted MR scans were useful in detecting and monitoring tumor size. Implanted tumor could be consistently resolved at sizes of 1.0 mm in diameter by using contrast-enhanced T1-weighted scans and a pixel size of 0.3

Fig. 5.—Postcontrast coronal T1-weighted (800/20) MR images of animal retreated with intracerebral injection of *C. parvum* 16 and 21 days after intracerebral injection of 50,000 KHT sarcoma cells.

A, At day 16. *Straight arrow* points to leptomeningeal enhancement of lateral convexity; *slanted arrow* points to interhemispheric enhancement; *curved arrow* points to ependymal enhancement.

B, At day 21, 4 days after retreatment with intracerebral injection of *C. parvum*, there was no detectable increase in enhancement or its distribution. *Long straight arrow* points to lateral convexity enhancement; *slanted arrow* points to interhemispheric enhancement; *curved arrow* points to ependymal enhancement (greater on left side), which was unchanged from image in Fig. 5A. Slightly increased apparent ependymal enhancement as compared with Fig. 5A was due to partial voluming of the lateral ventricles at day 16.



A

B

TABLE 2.

| Initial Tumor Burden Day 0 | Treatment Protocol | Treatment Group | | Enhancement ^a |
|--|---|--|--------------------------------------|--|
| | | No. of Days After Intracerebral Injection of Tumor | No. of Animals Imaged and Sacrificed | |
| 1 × 10 ⁴ cells of KHT sarcoma | ip <i>C. parvum</i> : day 1 ic <i>C. parvum</i> : day 4 | 16 | 8 | +2 leptomeningeal, ependymal enhancement with variable injection site enhancement. Two 2–3 mm diameter tumors identified. |
| | | 30 | 6 | +1 leptomeningeal, ependymal enhancement. One 1-cm tumor seen in the group. |
| | ip <i>C. parvum</i> : day 7 ic <i>C. parvum</i> : day 11 | 10 | 3 | No enhancement. No tumor identified. |
| | | 17 | 2 ^b | +1 leptomeningeal, ependymal enhancement. One 3-mm diameter tumor identified on follow-up day 17. |
| 5 × 10 ⁴ cells of KHT sarcoma | ip <i>C. parvum</i> : day 1 ic <i>C. parvum</i> : day 4 | 16 | 3 | +1 to +2 leptomeningeal, ependymal enhancement. No significant increase upon reinjection with ic <i>C. parvum</i> . |
| | | Additional ic <i>C. parvum</i> : day 17 | 21 | 5 ^c |

Note.—ip = intraperitoneal injection, ic = intracerebral injection.

^a +1 = mild to moderate enhancement, +2 = marked enhancement.

^b These animals were also imaged on day 10.

^c These animals were also imaged on day 16.

× 0.3 mm. There was close correlation between the imaging findings and neuropathologic findings for both tumor and the inflammatory response. The MR scans showed that the size of tumors in mice that were not aided by therapy were on the order of the expected size of tumors in untreated mice at the same time after intracranial injection of KHT sarcoma (Table 2). The results of this imaging study, however, do not allow conclusions to be drawn about the efficacy of this treatment. The MR scan monitoring of this model may have highlighted one of its weaknesses. It is likely that tumor successfully treated in this murine model may not reach macroscopic size or never reach a size sufficient to be distinguished from the parenchymal inflammation induced by *C. parvum*. Thus, it may be difficult with this mouse/KHT sarcoma model to simulate closely the imaging characteristics of patients with malignant gliomas and their response to therapy with *C. parvum*. However, the known imaging time course of the inflammatory response induced by intracerebral *C. parvum* should in the individual mouse or patient allow the distinction between tumor and treatment-induced inflammatory change.

MR imaging with gadopentetate dimeglumine-enhancement permits in vivo visualization of tumor and the effect of therapy, two factors that are essential in planning treatment protocols using immunotherapy. The MR findings representing inflammatory changes in the present study may serve as a paradigm for the imaging characteristics associated with other intracerebral immunotherapy protocols.

ACKNOWLEDGMENTS

The authors are indebted to Myung-Mee Scheller and Bonnie Bell for their gracious help both in scanning and in preparation of the animals used in the study.

REFERENCES

- Davis LW. Presidential address: Malignant glioma—a nemesis which requires clinical and basic investigation in radiation oncology. *J Radiat Oncol Biol Phys* 1988;16:1355–1365
- Conley FK, Remington JS. Nonspecific inhibition of tumor growth in the central nervous system: observations of intracerebral ependymoblastoma in mice with chronic toxoplasma infection. *J Natl Cancer Inst* 1977;59:963–973
- Conley FK. Effect of immunomodulation on the fate of tumor cells in the central nervous system and systemic organs of mice. Distribution of [¹²⁵I] 5-iodo-2'-deoxyuridine-labeled KHT tumor cells after left intracardiac injection. *J Natl Cancer Inst* 1982;69:465–473
- Conley F. K. Effect of *Corynebacterium parvum* and chronic toxoplasma infection on metastatic brain tumors in mice. *J Natl Cancer Inst* 1979;63:1237–1244
- Peters LJ. *Actions and interactions of Corynebacterium parvum in experimental tumor systems. Immunotherapy of human cancer.* New York: Raven, 1978:155–170
- Dye ES, North RJ, Mills CD. Mechanisms of anti-tumor activation of *Corynebacterium parvum*: I. Potentiated tumor-specific immunity and its therapeutic limitations. *J Exp Med* 1981;154:609–620
- Kida Y, Cravioto H. Comparative study of chemotherapy and/or immunotherapy of established brain tumors. *Neurol Med Chir (Tokyo)* 1985;25:515–521
- Lau BHS, Woolley JL, Marsh CL, et al. Superiority of intralesional immunotherapy with *Corynebacterium parvum* and *Allium sativum* in control of murine transitional cell carcinoma. *J Urol* 1986;156:701–705
- Lau BHS, Wang-Cheng RM, Tosk J. Tumor-specific T-lymphocyte cytotoxicity enhanced by low dose of *Corynebacterium parvum*. *J Leukoc Biol* 1987;41:407–411
- Thatcher N, Mene A, Banerejee SS, et al. Randomized study of *Corynebacterium parvum* adjuvant therapy following surgery for (stage II) malignant melanoma. *Br J Surg* 1986;73:111–115
- Ludwig Lung Cancer Group Study. Intrapleural *Corynebacterium parvum* as adjuvant therapy in operable bronchogenic non-small cell carcinoma. A preliminary report. In: Terry WD, Rosenberg SA, eds. *Immunotherapy of human cancer.* New York: Elsevier, 1982:111–117
- Ludwig Lung Cancer Group Study. Adverse effect of intrapleural *Corynebacterium parvum* as adjuvant therapy in resected stage I and II non-small cell carcinoma of the lung. *J Thorac Cardiovasc Surg* 1985;89:842–853
- Kennedy JD, Conley FK. Effect of intracerebrally injected *Corynebacterium parvum* on implanted brain tumor in mice. *J Neurooncol* 1989;7:89–101