

Recognizing the Empty Sella by CT: The Infundibulum Sign

Victor M. Haughton,¹
 Arthur E. Rosenbaum,²
 Alan L. Williams,¹
 Burton Drayer³

Inaccuracy in recognizing the empty sella by conventional computed tomography (CT) techniques derives from diverse intrasellar cystic structures that are not distinguished from it. In 23 cases of presumed empty sella, it was observed that the pituitary stalk within the enlarged sella (infundibulum) was demonstrated by thin (1.5 mm) coronal CT sections. Although the diagnosis was not proven by conventional studies, the normal appearance of the infundibulum is believed to exclude an intrasellar cyst or tumor as the cause of sellar enlargement. Coronal CT sections with thin slices and intravenous contrast enhancement are recommended when empty sella is to be documented by CT. When the infundibulum is not demonstrated by this technique, CT with intrathecal enhancement may be warranted.

Radiologic investigations of patients with empty sella are usually undertaken to exclude an intrasellar neoplasm, most often a pituitary adenoma [1-4]. An empty sella can be differentiated effectively but not comfortably, from an intrasellar neoplasm by pneumoencephalography or cisternography. Computed tomography (CT) is reported to be sensitive but not specific for the diagnosis of empty sella [5]. Empty sella, cystic intrasellar tumors, and intrasellar third ventricular recesses may not be distinguished confidently with axial CT images [5]. We have found that the differentiation can be made now because of the greater versatility of current CT equipment. In this report, we illustrate the infundibulum sign, which is specific for empty sella, and describe technical factors that are required for demonstrating it by CT.

Subjects and Methods

We studied 26 patients in whom an empty sella was recognized by CT. All patients were characterized by enlargement of the sella turcica and normal nonspecific neurologic and endocrine evaluation. The CT studies were performed on a GE CT/T 8800. The patients were positioned supine with their necks hyperextended in a modified head holder that facilitated hyperextension. A localizer image was obtained with the Scoutview program and a cursor was used to select coronal planes that avoided artifacts from dental fillings. To obtain the selected plane, the gantry was usually tilted 15° (top of gantry toward patient's feet). While the patient was being positioned, iodinated contrast medium was infused intravenously (30-40 g of iodine in 5 min). One or two contiguous 5 mm cuts and, in almost all cases, four to eight contiguous 1.5 mm cuts were obtained through the sella turcica with 120 kV, 1,150 mAs, 10 sec scan time. In those cases selected for repeat examination with intrathecal metrizamide a technique described previously was used [6]. Metrizamide (about 5 ml, 170 mg I/ml) was injected by lumbar puncture. The patient in prone position was tilted head-down about 30° for 2 min then returned to horizontal and transported to the scanner for CT imaging as described above.

Received June 27, 1980; accepted after revision July 29, 1980.

¹ Department of Radiology, Milwaukee County Medical Complex, 870 W. Wisconsin Ave., Milwaukee, WI 53226. Address reprint requests to A. L. Williams.

² Department of Radiology, Johns Hopkins Hospital, Baltimore, MD 21205.

³ Department of Radiology, Duke University Medical Center, Durham, NC 27110.

This article appears in November/December 1980 *AJNR* and February 1981 *AJR*.

AJNR 1:527-529, November/December 1980
 0195-6108/80/0016-0527 \$00.00
 © American Roentgen Ray Society

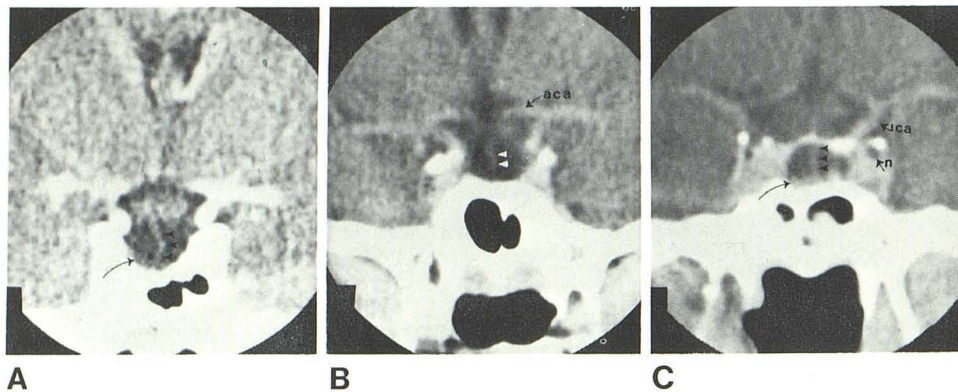


Fig. 1.—Coronal CT images. Infundibulum (arrowheads) in three patients with empty sella is traced from hypothalamus to pituitary gland (arrows). Third cranial nerve (n) in cavernous sinus and internal carotid (ica) and anterior cerebral (aca) arteries.

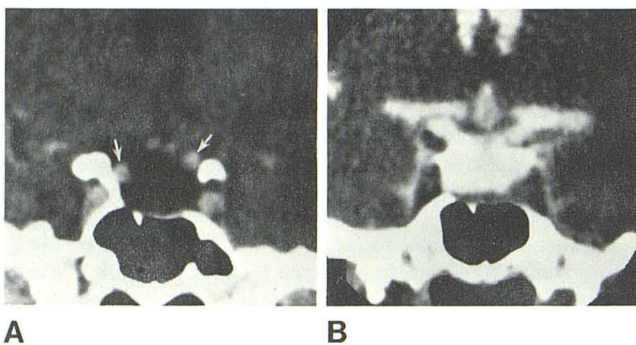


Fig. 2.—Empty sella demonstrated with intrathecal metrizamide. A, Contrast-enhanced coronal scan, 5 mm thick section. Cerebrospinal fluid density in pituitary fossa; vessels (arrows) suggest tumor capsule. B, Metrizamide fills pituitary fossa.

Results

In 23 patients, CT demonstrated the infundibulum extending from the tuber cinereum to the pituitary gland deep in an enlarged pituitary fossa (fig. 1). The pituitary gland measured 2–6 mm in height. The infundibulum was about midline and surrounded by cerebrospinal fluid density both in the chiasmatic cistern and in the sella. Pneumoencephalography, cisternography, or exploratory surgery was not performed in these cases.

In three cases in which 1.5 mm slices were not obtained, the infundibulum was not demonstrated within the pituitary fossa. In these cases, CT imaging after intrathecal metrizamide showed that, except for a small pituitary gland and stalk, the pituitary fossa contained only metrizamide (fig. 2) [1]. Neither pneumoencephalography nor surgery was performed.

Discussion

Demonstration of the infundibulum (i.e., a normal pituitary stalk in an enlarged sella) has not been reported previously.

A priori, such demonstration excludes a solid intrasellar mass or a cystic structure, such as arachnoid cyst, cranio-pharyngioma, adenoma, or herniated third ventricle in the pituitary fossa, since such a structure would displace or obscure the pituitary stalk. None of the 23 cases warranted further radiologic studies; therefore, they are not proven by conventional studies.

To demonstrate the infundibulum effectively, suitable techniques must be used. It is demonstrated ineffectively in axial or thick coronal sections; thin cuts in coronal projections are essential. Since the pituitary stalk enhances [7, 8], intravenous contrast medium facilitates its demonstration. Techniques to optimize spatial and contrast resolution are desirable; therefore, we used 25 cm calibration, maximum milliamperage, and narrow viewing windows.

Failure to demonstrate the infundibulum in a patient with an empty sella may be explained by a thin pituitary stalk, poor enhancement of the stalk with intravenous contrast medium, patient motion, inadequate contrast or spatial resolution, or too thick sections. In those cases in which CT fails initially to demonstrate the infundibulum, repeat CT with intrathecal metrizamide is warranted (fig. 3). Complete opacification of the pituitary fossa with intrathecal metrizamide with or without demonstration of the infundibulum indicates an empty sella [6, 9]. We also observed an empty sella filled by gas administered for myelography (figs. 4 and 5). A reliable technique for demonstrating the empty sella with CT and intrathecal gas may be developed for patients in whom the infundibulum is not demonstrated. However, we currently prefer the technique with metrizamide because of our greater familiarity with it.

REFERENCES

- Engles EP. Roentgenographic demonstration of a hypophyseal subarachnoid space. *AJR* 1958;80:1001–1004
- Gabriele OF. The empty sella syndrome. *AJR* 1968;104:168–170
- Kaufman B. The empty sella turcica. A manifestation of the intrasellar subarachnoid space. *Radiology* 1968;90:931–941
- Lee WM, Adams JE. The empty sella syndrome. *J Neurosurg* 1968;28:351–356

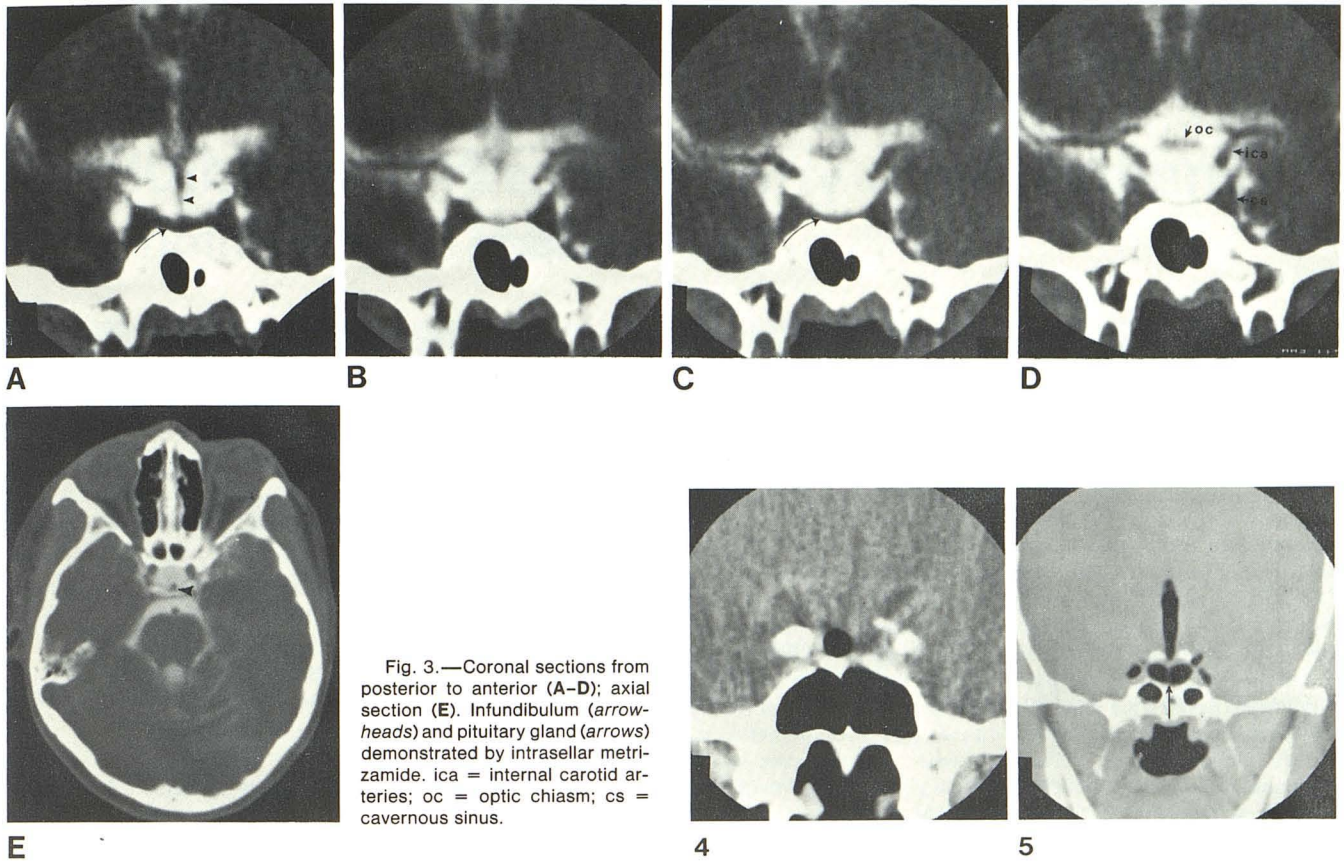


Fig. 3.—Coronal sections from posterior to anterior (A-D); axial section (E). Infundibulum (arrowheads) and pituitary gland (arrows) demonstrated by intrasellar metrizamide. ica = internal carotid arteries; oc = optic chiasm; cs = cavernous sinus.

Fig. 4.—Intrasellar gas incidentally noted after gas myelogram in patient with presumed empty sella.

Fig. 5.—Empty sella and infundibulum (arrow) with intrathecal gas.

5. Rozario R, Hammerschlag SB, Post KD, Wolpert SM, Jackson I. Diagnosis of empty sella with CT scan. *Neuroradiology* 1977;13:85-88
6. Manelfe C, Graud B, Espagno J, Kascol A. Cisternographic computerisée au métrizamide. *Rev Neurol (Paris)* 1978;134:471-484
7. Aubin ML, Bentson S, Vignard J. Tomodensitometrie de la tige

- pituitaire. *J Neuroradiol* 1978;5:153-160
8. Daniels D, Haughton V, Williams A, Gager W, Berns T. Computerized tomography of the optic chiasm. *Radiology* In press. 1981
9. Rosenbaum AE, Drayer BP. CT cisternography with metrizamide. *Acta Radiol [Suppl] (Stockh)* 1977;355:323-337