

# Venovenous Extracorporeal Membrane Oxygenation: Early CT Alterations following Use in Management of Severe Respiratory Failure in Neonates

James A. Brunberg,<sup>1-3,6</sup> Gabriele Kewitz,<sup>4,5</sup> and Robert E. Schumacher<sup>4</sup>

**PURPOSE:** To describe brain CT alterations occurring after neonatal venovenous extracorporeal membrane oxygenation (V-V ECMO). **METHODS:** CT studies were prospectively obtained after V-V ECMO in 31 neonates with severe respiratory failure. Images were scored for cerebrospinal fluid space size, hemorrhage, and regions of decreased attenuation. **RESULTS:** Subarachnoid space enlargement at the interhemispheric fissure, frontal, temporal, or parietal convexity occurred in 21 of the 31 patients. When subarachnoid space enlargement was asymmetric (six of the 21), it was always isolated to or greater on the right. Ventricular enlargement was demonstrated in seven of the 31. Hemorrhage occurred in seven and regions of low brain attenuation in 11 of the 31 neonates. **CONCLUSIONS:** Increased sagittal sinus pressure caused by internal jugular vein ligation and cannulation of the superior vena cava may contribute to subarachnoid space enlargement by decreasing cerebrospinal fluid resorption at the arachnoid villi. Reduced incidence of cerebral hemorrhage with V-V ECMO, as compared with venoarterial (V-A) ECMO, may relate to sparing of the right common carotid artery (it is ligated with V-A ECMO), and to routing of oxygenated blood to the right atrium with V-V ECMO rather than to the arterial circuit as with V-A ECMO.

**Index terms:** Hypoxia; Brain, computed tomography; Infants, newborn; Pediatric neuroradiology; Extracorporeal membrane oxygenation (ECMO)

AJNR 14:595-603, May/June 1993

Extracorporeal membrane oxygenation (ECMO) is increasingly used for the management of severe respiratory failure in the term or near-term neonate. The use of ECMO has reduced the mortality of severe neonatal respiratory failure to approximately 17% from 60% to 80% (1). Two ECMO techniques are currently in use. At most institutions, venoarterial (V-A) shunting routes blood to the membrane oxygenator from the right atrium via a cannula placed in the right internal jugular

vein. The right internal jugular vein is almost always used because of its direct relationship to the superior vena cava. Blood is returned to the aorta via a cannula inserted in the distal right common carotid artery. Both vessels are permanently ligated distal to their site of cannulation at the time of initiation of the procedure. V-A ECMO patients have been found to be at risk for the occurrence of neurologic dysfunction and to have a 10% to 46% risk for the presence of abnormality on neuroimaging studies (2-7). Such sequelae have been ascribed to neurologic manifestations of initial pulmonary insufficiency, to complications of the ECMO procedure itself, and to the immediate or residual effect of permanent internal jugular vein or common carotid artery ligation (8).

The possibility that such sequelae relate in part to permanent right common carotid artery ligation has prompted the development of venovenous (V-V) ECMO. With this second and newer technique, blood is pumped from the right atrium

---

Received December 16, 1991; accepted after revision July 24, 1992.

This paper was presented in part at the 30th Annual Meeting of the ASNR, June 1992, St. Louis, MO.

Departments of <sup>1</sup>Radiology, <sup>2</sup>Neurology, <sup>3</sup>Neurosurgery, and <sup>4</sup>Pediatrics and Communicable Diseases, University of Michigan Hospitals, Ann Arbor, MI.

<sup>5</sup> Present address; Department of Pediatrics, Klinikum-Steglitz, Free University of Berlin, Berlin, Germany.

<sup>6</sup> Address reprint requests to James A. Brunberg, MD, Department of Radiology, University of Michigan Hospitals, 1500 E. Medical Center Drive, Ann Arbor, MI 48109-0030.

AJNR 14:595-603, May/June 1993 0195-6108/93/1403-0595

© American Society of Neuroradiology



TABLE 1: Ventricular and subarachnoid space size in 31 subjects post V-V ECMO

| Ventricular or SAS Location | Normal Size | Mild Enlargement |      |           | Moderate Enlargement |      |           | Severe Enlargement |      |           |
|-----------------------------|-------------|------------------|------|-----------|----------------------|------|-----------|--------------------|------|-----------|
|                             |             | Right            | Left | Bilateral | Right                | Left | Bilateral | Right              | Left | Bilateral |
| Lateral ventricle           | 24          |                  | 6    |           |                      | 1    |           |                    |      |           |
| Third ventricle             | 29          |                  | 1    |           |                      | 1    |           |                    |      |           |
| Fourth ventricle            | 31          |                  |      |           |                      |      |           |                    |      |           |
| IHF                         | 14          |                  | 10   |           |                      | 6    |           |                    | 1    |           |
| SSC                         | 23          |                  | 8    |           |                      |      |           |                    |      |           |
| Frontal SAS                 | 24          | 1                | 1    | 2         | 1                    |      | 2         |                    |      | 1         |
| Temporal SAS                | 22          | 3                | 1    | 2         | 2                    |      | 1         |                    |      |           |
| Sylvian SAS                 | 15          | 2                | 1    | 11        | 1                    |      | 1         |                    |      |           |
| Parietal SAS                | 27          | 2                |      | 1         |                      |      | 1         |                    |      |           |
| Occipital SAS               | 31          |                  |      |           |                      |      |           |                    |      |           |
| Cerebellar SAS              | 30          |                  |      | 1         |                      |      |           |                    |      |           |

Note.—IHF = interhemispheric fissure; SAS = subarachnoid space; SSC = suprasellar cistern.

to the membrane oxygenator and then back to the right atrium through a double-lumen tube placed into the right atrium via the right internal jugular vein and superior vena cava. The internal jugular vein is permanently ligated above the site of cannulation but the carotid artery is not disturbed. At our institution, V-V ECMO has almost completely replaced V-A ECMO. The purpose of this report is to describe early brain computed tomography (CT) findings following the completion of V-V ECMO in a prospective series of patients.

## Methods

Brain CT studies were obtained as a prospective study on 31 V-V ECMO-managed survivors of neonatal respiratory failure. All infants were greater than 34 weeks gestational age at birth and were at high risk for death from respiratory failure. Oxygenation index was greater than 25 in all patients. The oxygenation index (OI) was calculated as:

$$OI = [MAP \times FiO_2 \times 100] / PaO_2$$

where MAP was mean airway pressure in mm Hg,  $FiO_2$  was the fraction of inspired oxygen, and  $PaO_2$  was arterial oxygen pressure in mm Hg (9). An OI over 25 was a relative indication for ECMO, while a value over 40 was considered an absolute indication for ECMO.

Contiguous axial 5-mm CT images were obtained through the cranial vault without intravenous contrast administration. Timing of CT scanning related to the patient's medical condition and to scanner availability. Patients transferred back to other level III neonatal intensive care units after V-V ECMO did not have routine CT imaging and are not included in this study. Images were graded perceptually for size of lateral, third, and fourth ventricles, and for size of subarachnoid spaces over the frontal, temporal, parietal and occipital lobes, and over the cerebellar

hemispheres. Size of the sylvian and interhemispheric fissures, and of the suprasellar cistern was evaluated, as was size of cerebrospinal fluid (CSF) spaces over the cerebellar hemispheres.

Ventricles and CSF spaces were scored as normal or as mildly, moderately, or markedly increased in size. The presence or absence of subarachnoid or intraparenchymal blood was noted, and when present was measured in millimeters and localized as extraaxial, cortical, subcortical, subependymal, intraventricular, or as involving the deep white matter. Cortex and white matter of each lobe was defined as normal or as mildly, moderately, or severely decreased in attenuation.

The presence or absence of regions of increased attenuation within the sagittal or transverse venous sinuses was noted. Regions of increased attenuation in the venous sinuses were characterized in Hounsfield units from region-of-interest measurements of stored image data using the physician CT console. The presence and severity of CT alteration was correlated with oxygenation index prior to ECMO, with duration of ECMO treatment, and with the duration of time between the completion of ECMO and the performance of CT imaging.

## Results

Mean oxygenation index prior to V-V ECMO was 39 (range, 24–62; SD, 9.9). V-V ECMO was initiated at mean age of 2.0 days (range, 0–10; SD, 2.2) and continued for a mean of 5.7 days (range, 3–17; SD, 3.5). CT imaging of the brain was performed at a mean of 4.6 days (range, 2–19; SD, 3.7) following completion of ECMO. Mean patient age at the time of CT was 12.1 days (range, 4–25; SD, 4.7).

Subarachnoid space and ventricular size as demonstrated by CT imaging is documented in Table 1. In 16 of the 31 neonates, there was enlargement of at least one of the scored sub-



arachnoid regions with ventricular size being normal (Figs. 1 and 2). In two, ventricular size was increased with the size of subarachnoid spaces remaining normal. In five, there was an increase in both ventricular and subarachnoid space size (Fig. 3). In six of the 21 neonates with enlarged subarachnoid spaces over the cerebral hemi-

spheres, the enlargement was asymmetric (Fig. 4). In all six cases, subarachnoid space on the right was larger than on the left (three of the six), or was the only side enlarged (three of the six). Ventricular size was symmetric in all 31 cases. There was no statistically significant relationship between the presence or absence of subarachnoid

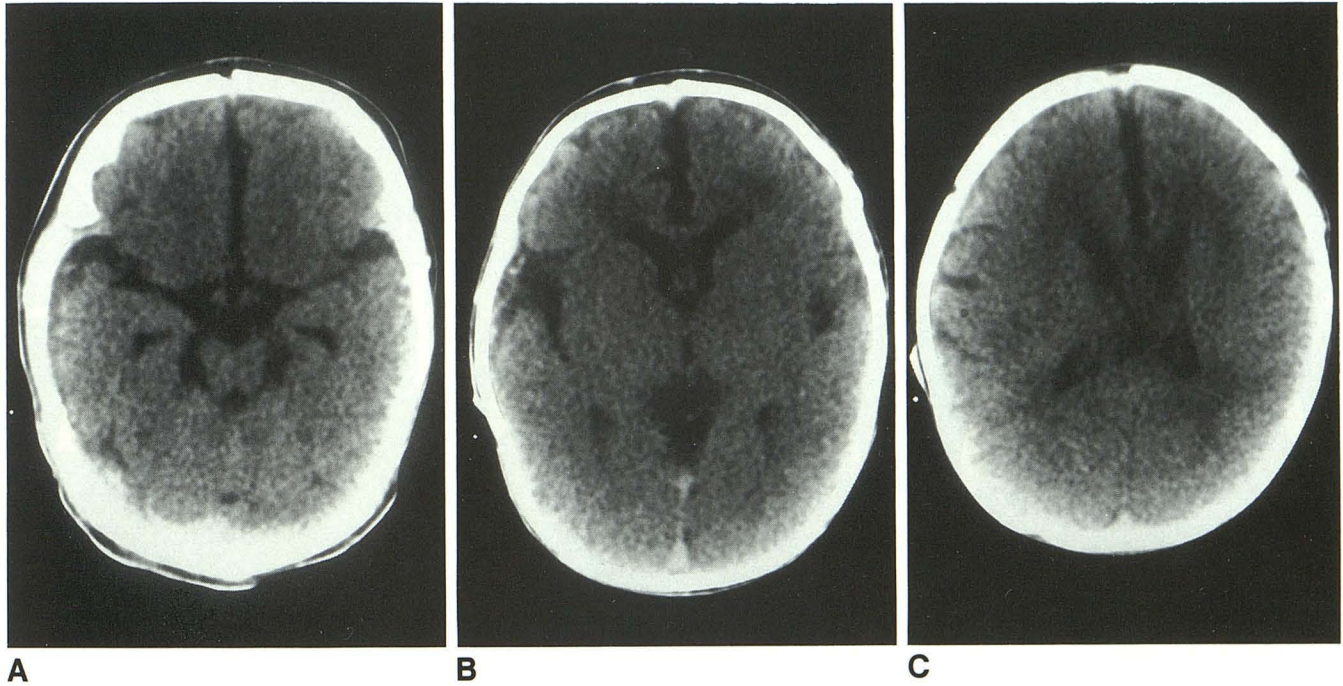


Fig. 1. Moderate enlargement of the anterior interhemispheric fissure and base of the sylvian fissures with no enlargement of subarachnoid spaces over the frontal convexities.

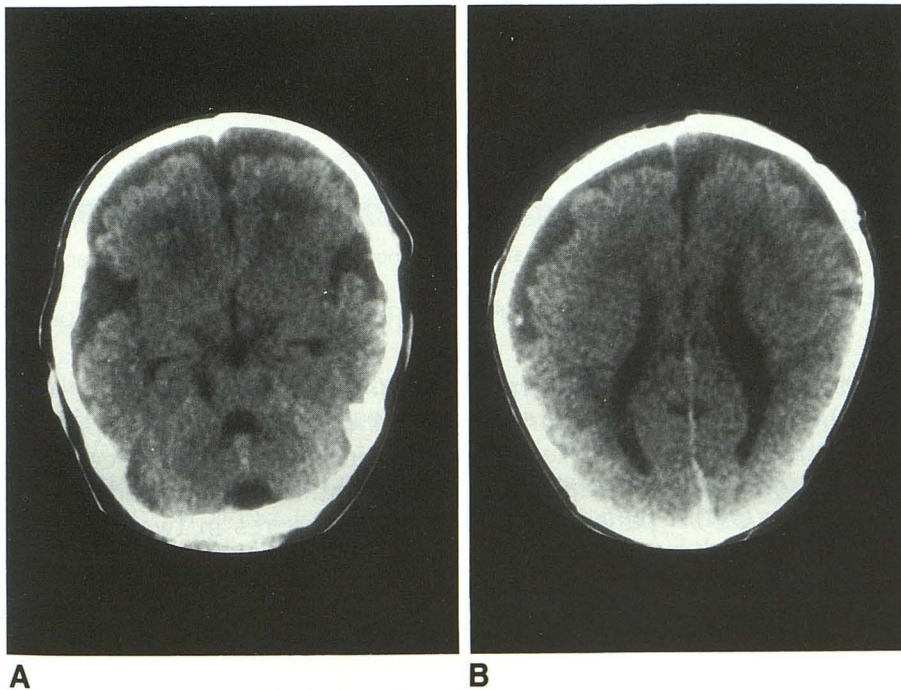


Fig. 2. Moderate enlargement of subarachnoid spaces over the frontal convexities and at the sylvian fissures with mild enlargement of the anterior interhemispheric fissure. There are punctate regions of hemorrhage in the frontal lobe white matter (A) and adjacent to the left anterior horn (B).



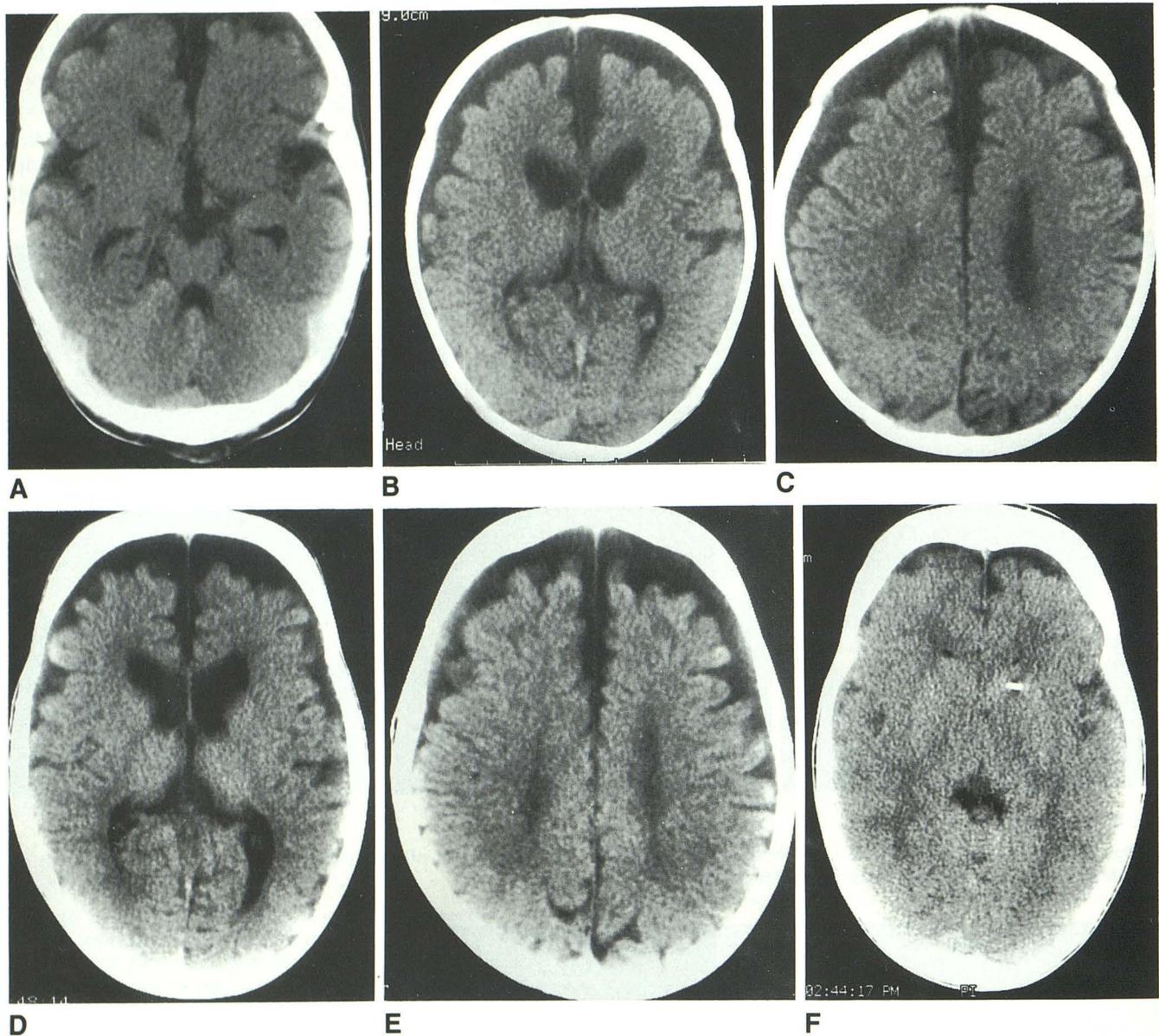


Fig. 3. A–C, Marked enlargement of the anterior portion of the interhemispheric fissure and of subarachnoid spaces over the frontal convexities. Lateral and third ventricles are mildly enlarged. Attenuation in the inferior aspect of the superior sagittal sinus is elevated at 75 HU (C).

D–E, Axial images at age 5 months, similar in location to B and C, demonstrate slightly increased ventricular and subarachnoid space size.

F, Following placement of a ventriculoperitoneal shunt, there is resolution of CSF space enlargement.

space or ventricular enlargement, and oxygenation index prior to placement on ECMO, duration of ECMO, or number of days between the completion of ECMO and the performance of CT scanning. There was no relationship between oxygenation index and duration of ECMO.

Regions of intraparenchymal hemorrhage measuring from 1 mm to 18 mm in diameter were present in seven of the 31 neonates (Figs. 2 and 5). Hemorrhage was less than 4 mm in

largest dimension in five patients and was 12 mm or 18 mm in largest dimension in one patient each. Hemorrhage occurred in the right cerebral hemisphere in one patient, left hemisphere in two patients, and both hemispheres in two patients. A single hemorrhage was seen in each cerebellar hemisphere (Fig. 5). No pattern for lateralization or size of hemorrhage was apparent. No patient demonstrated intraventricular hemorrhage. In one patient, regions of hemorrhage were demon-



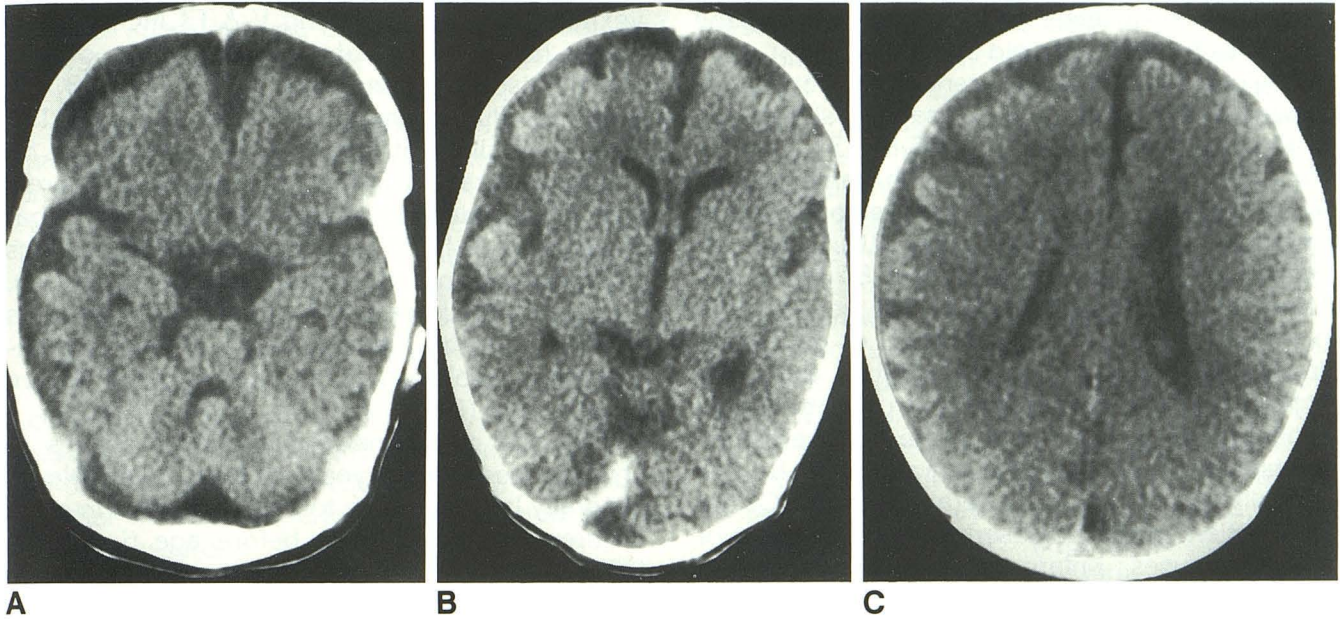


Fig. 4. Mild enlargement of subarachnoid spaces, asymmetrically prominent over the right frontal and right temporal lobes. Attenuation at the origin of the right transverse sinus was elevated at 63 HU (B).

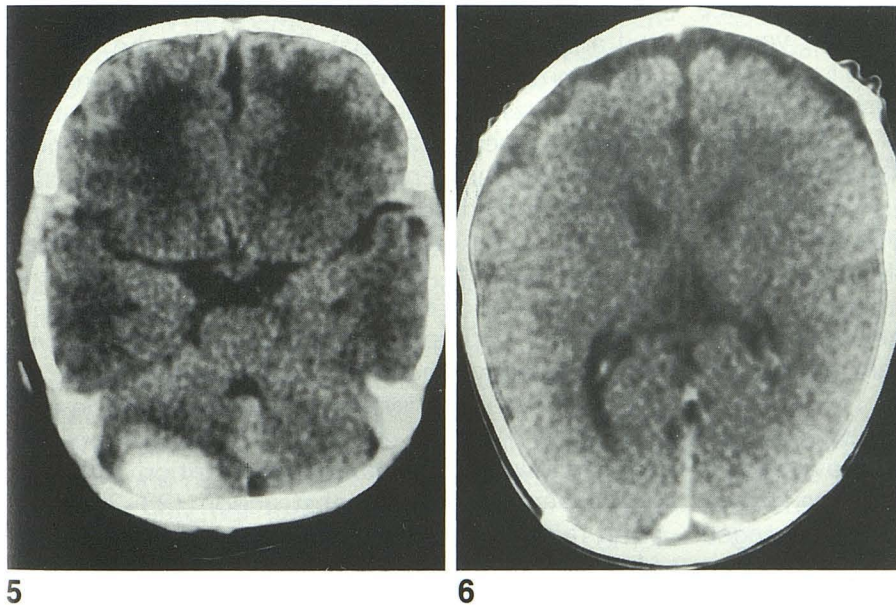


Fig. 5. Intraparenchymal hemorrhage in the right cerebellar hemisphere. There is decreased attenuation anterior to the right cerebellar hematoma and in central white matter of the frontal and temporal lobes. Attenuation in the central portion of the hematoma was 81 HU.

Fig. 6. A focal region of increased attenuation (93 HU) is demonstrated at the origin of the right transverse sinus in this unenhanced study. Adjacent images demonstrated attenuation in the dural sinuses to otherwise be normal.

strated at the medial free margins of the tentorium.

Regions of abnormally decreased attenuation were seen in 11 of the 31 neonates and involved the frontal (five of the 11), temporal (two of the 11), parietal (five of the 11), and occipital (four of the 11) lobes or one cerebellar hemisphere (one of the 11) (Fig. 5). In five of these 11 patients, there was more than one region of diminished attenuation. Regions of decreased cerebral attenuation involved the deep white matter in all 11 and extended to involve the cortex in two. Re-

gions of decreased attenuation were bilateral in seven, were confined to the right side in two, and to the left side in two. One patient had decreased attenuation in the cerebellum adjacent to a 18-mm diameter region of hemorrhage (Fig. 5). In three of the 11 patients, regions of decreased attenuation were noted to be coincident with lobar hemorrhage foci of 1 mm (two patients) or 12-mm (one patient) diameter. There was no statistically significant relationship between the presence or absence of intraparenchymal bleeding or decreased parenchymal attenuation, and



the presence or absence of enlargement of the ventricles or subarachnoid spaces.

Regions of increased attenuation were demonstrated within the superior sagittal sinus and/or the transverse sinus in 8 of the 31 patients (Figs. 3 and 6). Whole blood with hematocrit of 40 to 50 on unenhanced CT images normally has an attenuation of 47 to 60 HU (10). Fresh retracted clot has an attenuation of 85 to 90 HU. Attenuation values of 75 to 95 HU were present in portions of the superior sagittal or transverse sinuses in all eight patients described as having increased attenuation in these structures. An intraparenchymal hematoma in the right cerebellar hemisphere had attenuation values of 81 HU centrally and 71 HU peripherally (Fig. 5). Of the eight patients with increased attenuation in major venous sinuses, enlargement of subarachnoid spaces was demonstrated in five and enlargement of the lateral ventricles was demonstrated in three; two demonstrated neither ventricular nor subarachnoid space enlargement. A statistically significant relationship between the occurrence of regions of high attenuation within the venous sinuses and CSF space enlargement was not established. There was not a significant difference between duration of ECMO (mean, 4.7 days) or the time between completion of ECMO and CT scanning (mean, 7.9 days) for this group of eight patients and the group of 31 patients as a whole.

## Discussion

Structural alterations of the brain have been demonstrated with neuroimaging in 10% to 46% of patients following V-A ECMO (2, 3, 5-7, 11). Data regarding similar alterations following V-V ECMO have not been published, to our knowledge. In the current series of neonates managed with V-V ECMO, subarachnoid space enlargement was demonstrated in 21 of 31 patients and was the most frequent CT alteration. Such enlargement was seen to involve the anterior portion of the interhemispheric fissure, the suprasellar cistern, and CSF spaces over the frontal, temporal, and parietal lobes (Table 1). Lateral ventricular size was less frequently increased (Table 1). Five patients demonstrated combined lateral or third ventricular and subarachnoid space enlargement.

These findings differ from previous reports of V-A ECMO cases in which CT, MR, or sonographic imaging has only infrequently demonstrated enlargement of CSF spaces over the con-

vexities (11, 12). Following V-A ECMO, CT imaging has demonstrated enlargement of the interhemispheric fissure in 5% to 6% (3, 4), extraaxial fluid collection in 5% or 11% (11, 13), and "generalized atrophy" in 5% to 10% (3, 5). Using sonography, Rubin demonstrated progressive interhemispheric fissure enlargement in patients on V-A ECMO and related these findings to increasing somatic edema during ECMO (14). CT studies available in the majority of his patients within 1 month of completing V-A ECMO demonstrated resolution of interhemispheric fissure enlargement (14).

The size of normal subarachnoid spaces in children less than 2 years of age is variable, is generally larger relative to brain size than in older children, and is greatest before age 6 months (15). Findings in our patients were morphologically identical to those described in infants with external or benign communicating hydrocephalus (16-19), suggesting that the alteration may relate to impaired CSF resorption. Ultrastructural studies of arachnoid villi in humans and in experimental animals indicate that CSF enters the venous system through the process of endothelial micropinocytosis and vacuolation, and by passive flow through open channels from the subarachnoid space into the venous sinuses (20). This passive flow may be impaired by increased jugular and superior vena cava venous pressure transmitted to the superior sagittal sinus, resulting in the development of enlarged subarachnoid spaces.

Similar CSF space enlargement as an external or communicating hydrocephalus has been reported with superior vena cava obstruction (16) following Mustard repair of d-transposition (21, 22), following total parenteral nutrition with cerebral venous outflow obstruction (23-25), and with raised venous pressure associated with cardiac failure (16). In experimental animals, enlargement of cortical subarachnoid spaces has been reported following bilateral ligation of external and internal carotid veins with occlusion of the condyloid foramen (26). With V-V ECMO, CSF space enlargement may reflect increased intracranial venous pressure caused by partial SVC obstruction by the shunt cannula or because of right internal jugular vein ligation.

V-V ECMO in our series required insertion through the right internal jugular vein and superior vena cava of a 14-F double-lumen catheter. This catheter was generally larger than the 10- to 14-F single-lumen catheter used for V-A ECMO. The larger diameter may be responsible for



greater superior vena cava flow obstruction and elevated distal venous pressure relative to that occurring with the V-A catheter.

In a study of newborn lambs, Stolar and Reyes have demonstrated the occurrence of decreased intracranial pressure while on V-A ECMO (27). It was postulated that this finding related to lowered pressure in the right atrium that served as the source of blood pumped to the membrane oxygenator. In comparison, in patients treated with V-V ECMO, oxygenated blood is returned to the right atrium instead of to the proximal right common carotid artery, as with V-A ECMO. This resultant increase in right atrial pressure relative to the lowered atrial pressure of V-A ECMO may further increase superior vena cava and sagittal sinus pressure.

Enlargement of subarachnoid spaces was asymmetric in 6 of the 21 neonates, with all six demonstrating either greater enlargement of right than left subarachnoid spaces, or demonstrating enlargement confined to the right side. In previous series of V-A ECMO patients, asymmetric enlargement of extraaxial spaces has been seen in two patients, confined to the right side in one (11), and manifest as right greater than left "atrophy" in another (5). Asymmetric subarachnoid space enlargement may relate to head positioning during ECMO in which the face is turned to the left because of routine jugular venous cannula placement on the right. This prolonged positioning with face to the left may allow a dependent "settling" of the hemispheres to the left, preferentially enlarging subarachnoid spaces on the right. Asymmetry may also result from greater venous pressure in the right internal jugular vein stump and right petrosal venous system because of right internal jugular vein ligation. Although asymmetric lateralization of hemorrhagic complications to the side of cannulae placement and venous ligation has been supported (6) and refuted (2, 4, 5, 11, 13, 28) with V-A ECMO, the asymmetry in subarachnoid space size post-V-V ECMO is a distinct but unexplained finding in this series of patients.

Regions of increased CT attenuation within the sagittal and/or transverse venous sinuses was associated with increased subarachnoid space size in five of 31 patients in this series. Although there was no alteration in adjacent cerebral parenchyma in these patients to suggest venous thrombosis, as previously demonstrated in a single patient following V-A ECMO (2), the presence of regional thrombosis with obstruction of CSF

resorption or of venous flow in portions of the arachnoid villi cannot be excluded. Contrast-enhanced scans were not obtained in our series to exclude nonenhancing intraluminal thrombus. The increase in attenuation within the dural sinuses was not as extensive in our series as in Kuharik and Epgardsi's series of infants with increased venous pressure due to cardiac failure (29). Distinct intracranial dural sinus and venous distension was not demonstrated.

The occurrence in one of our patients of progressive hydrocephalus requiring the performance of a shunting procedure suggests that close follow-up of developmental progress and of head circumference growth will be necessary, and that repeat imaging may be prudent in patients managed with V-V ECMO (Fig. 3). In patients with benign external hydrocephalus, CSF space enlargement is most commonly self-limiting (16, 18), and shunting is infrequently necessary. It is anticipated that upon completion of V-V ECMO, the majority of patients will develop appropriate collateral venous pathways around the ligated internal jugular vein, and that postulated alterations in CSF resorption will also resolve. Enlarged subarachnoid spaces may predispose to accelerated head growth, and subdural hematoma may occur in such situations with minimal or no associated trauma (30). A sufficient number of follow-up CT studies in the current group of patients to determine the long-term outcome of CSF space enlargement following V-V ECMO are not yet available.

In the current series of V-V ECMO-treated neonates, cerebral hemorrhage was demonstrated with CT imaging in seven of 31 patients (22%). In only two patients was hemorrhage greater than 4 mm in largest dimension. Intracranial hemorrhage, the most common imaging alteration following V-A ECMO, has previously been demonstrated in 29% (3), 32% (4), and 46% (13) of patients during or following completion of treatment. When ultrasound is the sole procedure used to determine the presence of hemorrhage, and patients are limited to those with birth weight greater than 2.2 kg and estimated gestational age greater than 34 weeks, the rate of intracranial hemorrhage has been reported to be as low as 7% (7). Ultrasound, however, is less sensitive than CT for the demonstration of small or peripheral hemorrhagic foci (3, 11).

In patients undergoing ECMO, intraparenchymal or intraventricular hemorrhage has been thought to arise predominantly as a result of the



ECMO procedure itself. Hemorrhage has been ascribed to thrombocytopenia from platelet deposition in the membrane oxygenator, to sepsis, to increased cerebral blood flow during ECMO, to hemorrhage at the site of cerebral infarction, and to heparinization, which is necessary during the procedure (2, 7, 9, 31). Ligation of the internal jugular vein with increased intracranial venous pressure has also been postulated to be a contributing factor (7). Antecedent hypoxic/ischemic cerebral injury with impaired autoregulation and the effect of mechanical respiratory support with increased end expiratory pressure could also be responsible. Significant posterior fossa hemorrhage, as seen in one of our patients, has previously been reported to occur in association with V-A ECMO (2, 4, 11, 12). This pattern of hemorrhage is uncommonly associated with hypoxic/ischemic episodes and suggests a relationship to the ECMO procedure itself.

Small subependymal hemorrhages occurring in association with antecedent asphyxia and demonstrated with sonography prior to ECMO have been variously demonstrated to extend (4, 32) or not to extend (3, 4, 9) into the ventricular system while on ECMO. They have been thought not to be a major factor in the development of ECMO-related intracerebral hemorrhage and are not a contraindication to the use of ECMO.

The relatively low incidence of significant cerebral hemorrhage in patients managed with V-V ECMO may relate to improved pretreatment ultrasound imaging to exclude patients with large antecedent hemorrhage or to preservation of blood flow in the right internal carotid artery with diminished right hemisphere ischemia or infarction. There may also be diminished cerebral infarction in the left hemisphere from microemboli inasmuch as oxygenated blood is returned to the venous and pulmonary system rather than directly to the arterial system, as it is with V-A ECMO. In regions of cerebral ischemia, autoregulation is impaired and during periods of systemic blood pressure elevation, regional hyperperfusion can predispose to the occurrence of hemorrhage (31, 33).

Regions of decreased CT attenuation demonstrated in 11 of 31 neonates following V-V ECMO are of uncertain origin. It is not possible to determine whether these alterations, similarly reported to occur following V-A ECMO (3, 4), relate to hypoxic and ischemic events occurring prior to the initiation of ECMO, or whether they relate to additional insults occurring during the course of

V-V ECMO (33). Decreased CT attenuation in central white matter that did not extend to the cortical surface may also reflect delayed myelination for age rather than hypoxic/ischemic insult.

In patients treated with V-V ECMO for severe neonatal respiratory distress, CT imaging has demonstrated the frequent occurrence of subarachnoid space enlargement at the interhemispheric fissure, suprasellar cistern, and over the frontal, temporal, and parietal convexities. Subarachnoid space enlargement is postulated to occur secondary to diminished CSF resorption at the arachnoid villi due to increased sagittal sinus venous pressure. The long-term course of this finding remains undetermined and repeat imaging of patients managed with V-V ECMO to exclude persistence or progression of this finding is suggested. Among patients managed with V-V ECMO, intracranial hemorrhage appears to be less frequent than in patients managed with V-A ECMO, possibly because of preservation of flow in the right common carotid artery and because of return of oxygenated blood to the right atrium rather than to the arterial system as with V-A ECMO, which bypasses the filtering function of the pulmonary vascular bed.

## References

1. Schumacher RE, Palmer TW, Roloff DW, LaClaire PA, Bartlett RH. Follow-up of infants treated with extracorporeal membrane oxygenation for newborn respiratory failure. *Pediatrics* 1991;87:451-457
2. Taylor GA, Fitz CR, Miller MK, Garin DB, Catena LM, Short BL. Intracranial abnormalities in infants treated with extracorporeal membrane oxygenation: imaging with US and CT. *Radiology* 1987;165:675-678
3. Taylor GA, Fitz CR, Glass P, Short BL. CT of cerebrovascular injury after neonatal extracorporeal membrane oxygenation: implications for neurodevelopmental outcome. *AJR: Am J Roentgenol* 1989;153:121-126
4. Taylor GA, Short BL, Fitz CR. Clinical and laboratory observations: imaging of cerebrovascular injury in infants treated with extracorporeal membrane oxygenation. *J Pediatr* 1989;114:635-639
5. Wiznitzer M, Masaryk TJ, Lewin J, Walsh M, Stork EK. Parenchymal and vascular magnetic resonance imaging of the brain after extracorporeal membrane oxygenation. *Am J Dis Child* 1990;144:1323-1326
6. Schumacher RE, Barks JDE, Johnston MV, et al. Right-sided brain lesions in infants following extracorporeal membrane oxygenation. *Pediatrics* 1988;82:155-161
7. Cilley RE, Zwischenberger JB, Andrews AF, Bowerman RA, Roloff DW, Bartlett RH. Intracranial hemorrhage during extracorporeal membrane oxygenation in neonates. *Pediatrics* 1986;78:699-704
8. Fink SM, Bockman DE, Howell CG, Falls DG, Kanto WP Jr. Bypass circuits as the source of thromboemboli during extracorporeal membrane oxygenation. *J Pediatr* 1989;115:621-624
9. Ortega M, Ramos AD, Platzker ACG, Atkinson JB, Bowman CM. Clinical and laboratory observations: early prediction of ultimate



- outcome in newborn infants with severe respiratory failure. *J Pediatr* 1988;113:744-747
10. New PFJ, Aronow S. Attenuation measurements of whole blood and blood fractions in computed tomography. *Radiology* 1976;121:635-640
  11. Babcock DS, Han BK, Weiss RG, Ryckman FC. Brain abnormalities in infants on extracorporeal membrane oxygenation: sonographic and CT findings. *AJR: Am J Roentgenol* 1989;153:571-576
  12. Lewin JS, Masaryk TJ, Modic MT, Ross JS, Stork EK, Wiznitzer M. Extracorporeal membrane oxygenation in infants: angiographic and parenchymal evaluation of the brain with MR imaging. *Radiology* 1989;173:361-365
  13. Slovis TL, Sell LL, Bedard MP, Klein MD. Ultrasonographic findings (CNS, thorax, abdomen) in infants undergoing extracorporeal oxygenation therapy. *Pediatr Radiol* 1988;18:112-117
  14. Rubin DA, Gross GW, Ehrlich SM, Alexander AA. Interhemispheric fissure width in neonates on ECMO. *Pediatr Radiol* 1990;21:12-15
  15. Kleinman PK, Zito JL, Davidson RI, Raptopoulos V. The subarachnoid spaces in children: normal variations in size. *Radiology* 1983;147:455-457
  16. Kendall B, Holland I. Benign communicating hydrocephalus in children. *Neuroradiology* 1981;21:93-96
  17. Maytal J, Alvarez LA, Elkin CM, Shinnar S. External hydrocephalus: radiologic spectrum and differentiation from cerebral atrophy. *AJNR: Am J Neuroradiol* 1987;8:271-278
  18. Ment LR, Duncan CC, Geehr R. Benign enlargement of the subarachnoid spaces in the infant. *J Neurosurg* 1981;54:504-508
  19. Modic MT, Kaufman B, Bonstelle CT, Tomsick TA, Weinstein MA. Megalocephaly and hypodense extracerebral fluid collections. *Radiology* 1981;141:93-100
  20. Tripathi R. Tracing the bulk outflow route of cerebrospinal fluid by transmission and scanning electron microscopy. *Brain Res* 1974;80:503-506
  21. Coulson JD, Pitlick PT, Miller DC, et al. Severe superior vena cava syndrome and hydrocephalus after the Mustard procedure: findings and a new surgical approach. *Circulation* 1984;70(suppl 1):1-47
  22. Abbruzzese PA, Issenberg H, Cobanoglu A, Garcia C, Nunley D, Starr A. Superior vena cava obstruction after Mustard repair of d-transposition of the great arteries. *Scand J Thorac Cardiovasc Surg* 1984;18:5-7
  23. Newman LJ, Heitlinger L, Hiesiger E, Kotsilimbas D, Puljic S. Communicating hydrocephalus following total parenteral nutrition. *J Pediatr Surg* 1980;15:215-217
  24. Stewart DR, Johnson DG, Myers GG. Hydrocephalus as a complication of jugular catheterization during total parenteral nutrition. *J Pediatr Surg* 1975;10:771-777
  25. Haar FL, Miller CA. Hydrocephalus resulting from superior vena cava thrombosis in an infant: case report. *J Neurosurg* 1975;42:597-601
  26. Bering EA Jr, Salibi B. Production of hydrocephalus by increased cephalic-venous pressure. *Arch Neurol Psych* 1959;81:693-698
  27. Stolar CJH, Reyes C. Extracorporeal membrane oxygenation causes significant changes in intracranial pressure and carotid artery blood flow in newborn lambs. *J Pediatr Surg* 1988;23:1163-1168
  28. Matsumoto JS, Babcock DS, Brody AS, Weiss RG, Ryckman FG, Hiyama D. Right common carotid artery ligation for extracorporeal membrane oxygenation: cerebral blood flow velocity measurement with Doppler Duplex US. *Radiology* 1990;175:757-760
  29. Kuharik MA, Edwards MK. Cerebral venous distention associated with cardiac failure in infants. *AJNR: Am J Neuroradiol* 1987;8:657-659
  30. Kapila A, Trice J, Spies WG, Siegel BA, Gado MH. Enlarged cerebrospinal fluid spaces in infants with subdural hematomas. *Radiology* 1982;142:669-672
  31. van de Bor M, Walther FJ, Gangitano ES, Snyder JR. Extracorporeal membrane oxygenation and cerebral blood flow velocity in newborn infants. *Crit Care Med* 1990;18:10-13
  32. Crombleholme TM, Adzick S, de Lorimier AA, Longaker MT, Harrison MR, Charlton VE. Carotid artery reconstruction following extracorporeal membrane oxygenation. *Am J Dis Child* 1990;144:872-874
  33. Pyrdys O. Neurological process: control of cerebral circulation in the high-risk neonate. *Ann Neurol* 1991;30:321-329

**Please see the Commentary by Hayden on page 604 in this issue.**