

The Varied Presentations of Papillary Thyroid Carcinoma Cervical Nodal Disease: CT and MR Findings

Peter M. Som, Margaret Brandwein, Mika Lidov, William Lawson, and Hugh F. Biller

PURPOSE: To review the varied presentations of metastatic cervical lymph node disease in patients with papillary thyroid carcinoma. **METHODS:** Thirteen cases were retrospectively collected and their clinical, imaging, surgical, and pathologic material was reviewed. In the cases reviewed there was no clinical or imaging evidence of a primary thyroid mass. **RESULTS:** On CT, metastatic nodes can have multiple discrete calcifications, appear as benign cysts or hyperplastic or hypervascular nodes, or have areas of high attenuation which reflect intranodal hemorrhage and/or high concentrations of thyroglobulin. On MR, the nodes can have low to intermediate T1- and high T2-weighted signal intensities or high T1- and T2-weighted signal intensities, the latter reflecting primarily a high thyroglobulin content. **CONCLUSION:** If any of these varied appearances of cervical lymph nodes are identified on CT or MR, especially in a woman between 20 and 40 years of age, the radiologist should suspect the diagnosis of papillary thyroid carcinoma, even in the absence of a thyroid mass.

Index terms: Thyroid gland, neoplasms; Carcinoma; Neck, computed tomography; Neck, magnetic resonance

AJNR Am J Neuroradiol 15:1123-1128, Jun 1994

Usually by the time a patient is sent for a sectional imaging examination of the head and neck to evaluate cervical metastatic disease, the primary site is already known. It is in only about 5% of patients that metastatic cervical adenopathy presents clinically with no known primary site (1). In such patients, malignant neck disease is suspected because the clinician palpates rock-hard, nontender, usually nonpainful, and often fixed nodes. But occasionally, despite good clinical examination and sectional imaging studies, the diagnosis of metastatic disease is not initially made. We have collected 13 cases of papillary thyroid carcinoma, all of which presented initially as undiagnosed malignancies. These cases and their computed tomography (CT) and magnetic resonance (MR) findings are

reviewed to demonstrate the often unusual and varied nature of this tumor.

Materials and Methods

We retrospectively reviewed our clinical case material since 1985 to search for cases of papillary thyroid carcinoma that presented clinically with what seemed to be benign neck disease, without suspected thyroid tumor. We found 13 cases that had either CT or MR studies. There were 8 women and 5 men who ranged in age from 21 to 75 years with a mean age of 42.2 years (if the one patient 75 years of age is excluded, the mean age is 39.4 years). The CT scans were performed on either an 8800 (1 patient) or 9800 (9 patients) scanner (General Electric Medical, Milwaukee, Wis) as noncontrast and postcontrast axial 5-mm contiguous studies. The MR scans were performed on either an Elscint 0.5-T Gyrex S5000 unit (Elscint, Boston, Mass) (1 patient) or a 1.5-T Signa scanner (General Electric Medical) (2 patients) as 5-mm-thick sections with 1- to 3-mm interspace gap. There were short-repetition-time/short-echo-time (500-750/11-30) and long-repetition-time/short- and long-echo-time (200-3500/20-35, 80-100) studies. There usually were 2 excitations, and the matrix size varied as 256 × 192 or 256 × 128. Axial scans were available in all cases, and most studies also had coronal and sagittal scans. Postcontrast (Magnevist, Berlex, Wayne, NJ) studies were also obtained in 2 cases with a dose of 0.1 mmol/kg. The images shown are representative

Received July 19, 1993; accepted pending revision September 8; revision received September 21.

From the Departments of Radiology (P.M.S., W.L., H.F.B.), Otolaryngology (P.M.S., M.L.), and Pathology (M.B.), Mount Sinai School of Medicine of the City University of New York.

Address reprint requests to Peter M. Som, MD, Department of Radiology, Mount Sinai Hospital, One Gustave Levy Pl, New York, NY 10029.

AJNR 15:1129-1138, Jun 1994 0195-6108/94/1506-1129

© American Society of Neuroradiology

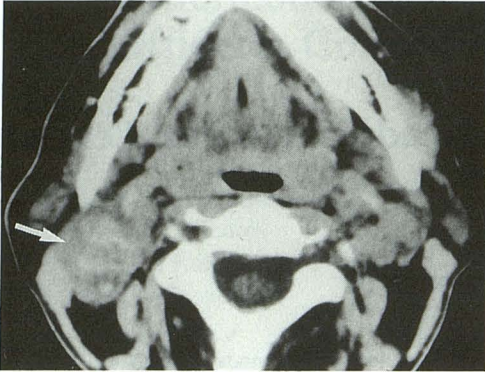


Fig. 1. Axial noncontrast CT scan shows a right-sided lymph node (*arrow*) that has multiple discrete calcifications within it.

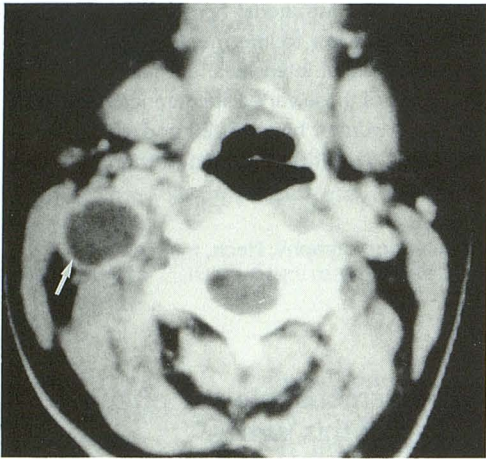


Fig. 2. Axial postcontrast CT scan shows a uniformly thin-walled cystic lymph node (*arrow*). There is slight enhancement of the rim.

of these studies (Figs 1–8). All of the nodes identified on the CT and MR scans were resected at surgery. Each node was correlated for position with the scans and studied histologically. However, thyroglobulin levels were measured only on the nodes identified on the MR scans.

Results

Of the 10 patients who had CT scans, 3 had enlarged, posterior triangle (level V) lymph nodes that, with the exception of scattered multiple discrete calcifications, were of a homogeneous attenuation that was slightly less than that of muscle (Fig 1). Five patients had CT findings of a uniformly thin-walled cyst (Fig 2). In 1 case the cyst wall was enhancing; in 4 cases, the cyst wall was barely identifiable (Fig 3). These cystic nodes were located either in the posterior triangle (level V) (2 patients) or in the submandibular (level 1) region (3 patients). There were 2 additional patients who had nodal enhancement on their CT

scans. In 1, there was fairly uniform diffuse enhancement of several bilateral submandibular (level I), jugulodigastric (level II and upper level III), and upper posterior triangle (level V) nodes (Fig 4). The other patient had a partially enhancing (this area was also of a high attenuation on a noncontrast CT scan) and partially cystic node in the upper infraomohyoid neck (level IV) (Fig 5). Of the 3 patients who had MR studies, 1 had a

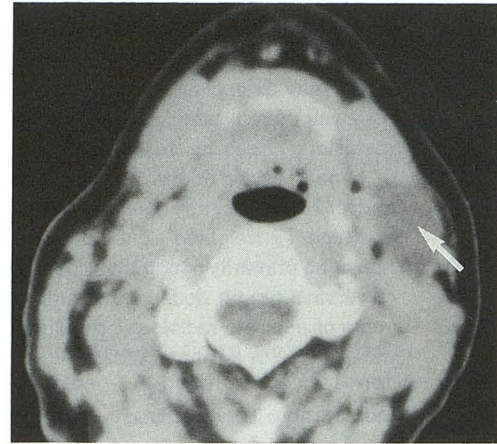

Fig. 3. Axial postcontrast CT scan shows a mucoid attenuation cystlike lymph node in the left submandibular-jugulodigastric region (*arrow*). There is almost no identifiable cyst wall.

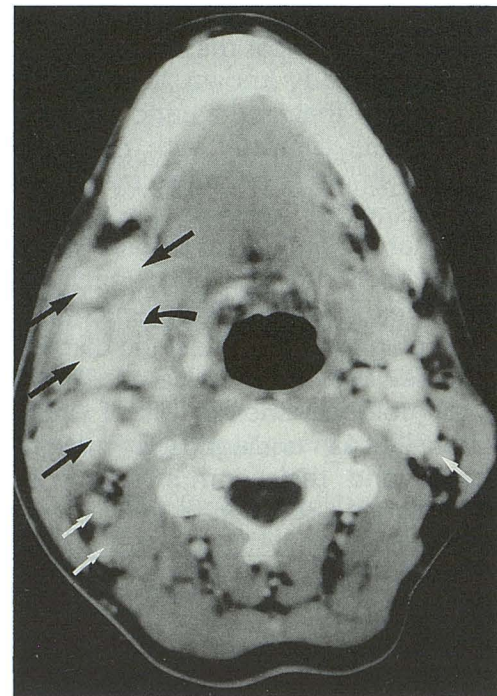


Fig. 4. Axial postcontrast CT scan shows multiple bilateral enhancing lymph nodes. Most of the larger lymph nodes are in the right submandibular and jugulodigastric region (*black arrows*). There are also bilateral posterior triangle enhancing lymph nodes (*white arrows*). *Curved arrow* indicates right submandibular gland.

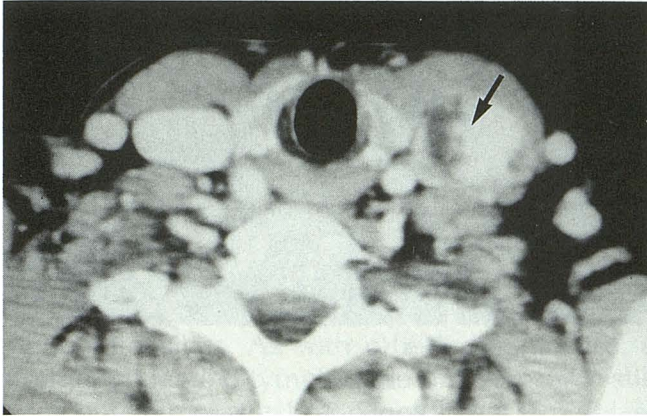


Fig. 5. Axial postcontrast CT scan shows a partially cystic and partially enhancing left internal jugular chain lymph node (arrow). The enhancing portion of the lymph node also had a high attenuation on a noncontrast study.

solitary posterior triangle (level V) node that had a high signal intensity on both T1-weighted and T2-weighted scans (compared with muscle) (Fig 6); 1 patient had several bilateral jugulodigastric and posterior triangle nodes. One of these nodes had high T1- and T2-weighted signal intensity; the remaining nodes had low to intermediate T1-weighted and high T2-weighted signal intensities (Fig 7). The last patient had multiple, albeit primarily unilateral, bilateral internal jugular nodes (levels III and IV). Most of these nodes had relatively low T1-weighted and high T2-weighted signal intensities; however, 1 node had high T1- and T2-weighted signal intensities (Fig 8). All 13 patients had grossly normal thyroid glands on clinical examination and either CT or MR studies. These sectional imaging appearances follow.

On CT:

1. Cystic node with a thin, uniform enhancing rim.
2. Homogeneously enhancing node.
3. Node with variably sized small discrete calcifications.
4. Normal hyperplastic-appearing node.
5. Node with areas of high attenuation that represent hemorrhage.

On MR:

1. Node with low to intermediate T1-weighted signal intensity and high T2-weighted signal intensity.
2. Node with high T1-weighted signal intensity and high T2-weighted signal intensity. The high T1-weighted signal could be caused by

either hemorrhage or high thyroglobulin concentration.

All of the lymph nodes had microscopic papillary thyroid tumor cells, usually forming follicles. Only the one lymph node that had a mixed cystic and high-attenuation CT appearance had gross hemorrhage at pathology.

The three lymph nodes that had high T1-weighted signal intensity had intranodal blood pools with hypervascularity but no clot formation. All of these nodes had large amounts of thyroglobulin (colloid).

Discussion

Fewer than 1% of all malignancies in the United States are caused by thyroid carcinomas, and about 60% of these tumors are papillary thyroid cancers (2, 3). Of those thyroid cancers occurring in patients younger than 40 years of age, papillary is by far the most common form, representing up to 62% of the cases (4). Papillary thyroid carcinoma occurs more commonly in female patients than in male patients (2.3:1), and the age group involved is usually between 20 and 50 years. Pathologically, papillary thyroid carcinoma in cervical lymph nodes can vary in its architecture. It may form largely papillary structures on fibrovascular stalks, which are associated with psammoma bodies (the result of degeneration of the tips of the papillae) and a paucity of colloid. Alternately, this tumor may grow mostly as follicles (follicular variant), which is associated with colloid (thyroglobulin) production. There is no known prognostic significance to this variability. Nodal cystic degeneration is common, and intracystic hemorrhage can occur. Calcification and/

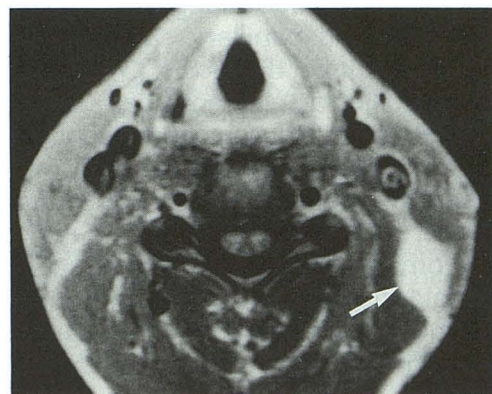


Fig. 6. Axial T1-weighted (757/22) MR scan shows a high-signal-intensity left posterior triangle lymph node (arrow). This lymph node also had a high T2-weighted signal intensity.

Fig. 7. A, Axial T1-weighted (600/15) MR scan shows two right posterior triangle lymph nodes, one of which has a high signal intensity (*large arrow*) and one of which has an overall intermediate signal intensity (*small arrow*).

B, Axial T2-weighted (2400/90) MR scan shows that both of the lymph nodes in A have high signal intensity.

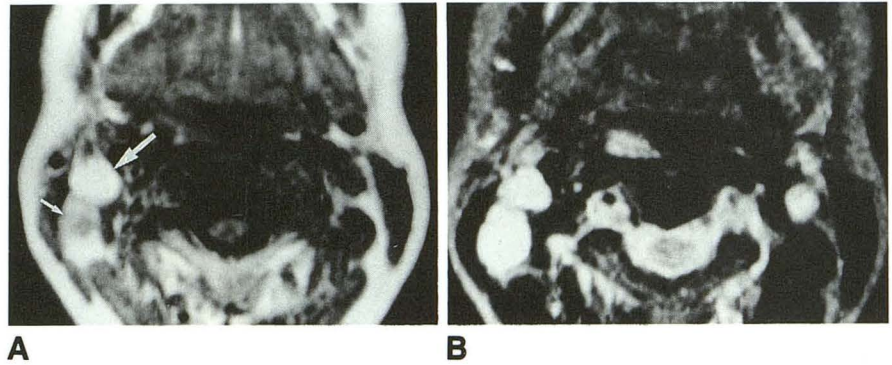
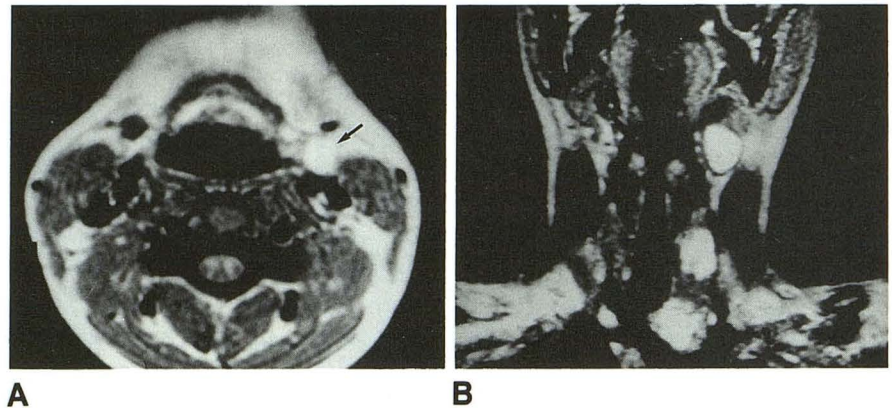


Fig. 8. A, Axial T1-weighted (700/25) MR scan shows a left jugulodigastric lymph node (*arrow*) that has a high signal intensity.

B, Coronal T2-weighted (2200/110) MR scan shows several left-sided enlarged lymph nodes and several smaller right-sided lymph nodes, all of which have high signal intensity.



or ossification may be extensive in some cases, and psammomatous calcifications overall occur in 25% to 40% of the specimens (3, 4). Approximately 50% of patients have cervical lymph node metastasis at the time of initial diagnosis, and 22% of these patients have occult thyroid tumors (like the cases in this study) (4). Only between 2% and 8% of patients have distant metastasis, usually to the lungs (5).

As mentioned, papillary carcinomas frequently also contain evidence of follicular carcinoma, and some pathologists have suggested the term "mixed follicular and papillary carcinoma" as a reasonable descriptive diagnosis (3). The presence of such follicular elements has no definite prognostic value, and these cases essentially behave as purely papillary carcinomas.

Metastasis in cervical lymph nodes from a thyroid cancer usually can be differentiated pathologically from metastasis from a nonthyroidal origin. Thyroid tumors have a strong tendency to produce large amounts of colloid (stains with periodic acid-Schiff) and have little if any mucin production (3).

Thyroid tumor multicentricity is frequent and often occurs in patients who have had prior low-dose irradiation to the head and neck (6) (none

of our patients had prior irradiation). Approximately 10% of these tumors are reported to be bilateral.

The prognosis is excellent when the patient is younger than 40 years of age, with the 5- and 10-year survival rates being 98.8% and 95%, respectively. However, when the patient is older than 40 years of age, the 5- and 10-year survival rates are 86.8%, and 72.8%, respectively. Thus there is evidence that this cancer has a worse prognosis when the patient is older than 40 years of age (4). When the tumor is less than 1 cm in diameter (considered clinically occult), the survival with or without cervical metastasis is essentially the same as for healthy age- and sex-matched patients (4). In general, there is a poorer prognosis when the primary tumor is greater than 2 cm, when there is extension of the primary tumor outside of the thyroid gland capsule, or when anaplastic transformation is present (3).

The role of imaging in aiding the diagnosis and management of patients with cervical nodal disease and in patients with thyroid disease is well established in the literature (7-16). These articles show that on CT, thyroid disease has been reported to be in the differential diagnosis of cervical cystic masses; the presence of variable-size

nodal calcifications also has been noted. On MR, tumor has been reported to have a low to intermediate T1-weighted and an intermediate to high T2-weighted signal intensity compared with brain.

Our experience has shown that metastatic cervical nodal disease also can appear as enhancing nodes on contrast CT, a partially cystic node with an area of high attenuation (hemorrhage), and on MR as masses with high T1- and T2-weighted signal intensities. As with other malignancies, a normal-appearing lymph node on CT or MR still can contain metastasis and look like a hyperplastic node. In such cases, metastatic disease is diagnosed only at pathologic sectioning.

Papillary thyroid carcinoma seems to be one of the very few malignancies that can completely cavitate a lymph node to mimic on sectional imaging an apparently "benign cyst" with a smooth, even wall. In our experience, only a rare eccrine carcinoma has similarly completely cavitated a node. Although other cancers may be able to so mimic a benign cyst on CT or MR, it seems appropriate to say that based on the literature and our case material, the most common carcinoma to do so is papillary thyroid cancer.

Papillary thyroid carcinoma has a proclivity to have tumor vessels and blood pools within a metastatic node and to hemorrhage occasionally, especially within a cystic node. Consequently, it is reasonable to postulate that sufficient methemoglobin may be present within a node to account for shortening of the T1 relaxation time. However, in this limited study, there was no gross end-stage evidence (hemosiderin-laden macrophages) of red cell breakdown and methemoglobin in those lymph nodes that had short T1 relaxation times. Ultraviolet spectrophotometric analysis for methemoglobin could not be performed on the specimens. There was, however, a high concentration of colloid, which is a large macromolecular protein (thyroxine and triiodothyronine are smaller pieces of thyroglobulin).

These findings raise the possibility that it was the high macromolecular protein content of the nodes that primarily accounted for the T1 relaxation effect. Although in our patients it is impossible to prove beyond any doubt that such is the case, as stated, there is evidence in the literature to support the contention that it might be the protein effect, with or without the methemoglobin effect, that accounted for the occasional node with T1 shortening (17).

Although theoretically diffuse fatty replacement of a lymph node could give a diffusely high T1-weighted signal intensity, such an occurrence has not been reported. Only fatty metaplasia of the hilum has been observed in reactive nodes. Similarly, the benign and malignant lipomatous tumors have not been reported to replace structurally the normal lymph node architecture (18).

The differential diagnosis of diseases that cause hypervascular lymph nodes and thus significant enhancement on CT and MR (as well as conceivably shortening the T1 relaxation time by having associated hemorrhage) is short. Entities such as angioimmunoblastic lymphadenopathy with dysproteinemia, angiolymphoid hyperplasia with eosinophilia, Kaposi sarcoma, and Castleman disease (angiofollicular hyperplasia) comprise this list of rare diseases. Acute infection with reactive regional adenopathy also could account for enhancing lymph nodes on CT and MR. Clinically each of these diseases can be excluded from the differential diagnosis in our case material.

In summary, papillary thyroid carcinoma causes varied cervical lymph node appearances on both CT and MR studies that may mimic benign disease. An awareness of these different appearances, especially when they occur in a woman between the ages of 20 and 40 years (even with a normal-appearing thyroid gland), should allow the radiologist at least to suggest the diagnosis of papillary thyroid carcinoma.

References

1. Batsakis JG. *Tumors of the head and neck: clinical and pathological considerations*. 2nd ed. Baltimore: Williams & Wilkins, 1979:245-248
2. Boring CC, Squires TS, Tong T. Cancer statistics, 1993. *CA* 1993;43:18-19
3. Compagno J. Diseases of the thyroid. In: Barnes L, ed. *Surgical pathology of the head and neck*. Vol 2. New York: Marcel Dekker, 1985:1455-1463
4. Beahrs OH, Kiernan PD, Hubert JP Jr. Cancer of the thyroid gland. In: Suen JY, Myers E, eds. *Cancer of the head and neck*. New York: Churchill Livingstone, 1981:599-632
5. Woolner LB, Beahrs OH, Black BM, McConahey WM, Keating FR. Classification and prognosis of thyroid carcinoma: a study of 885 cases observed in a thirty year period. *Am J Surg* 1961;102:354-387
6. Schneider AB, Pinsky S, Bekerman C, Reo U. Characteristics of 108 thyroid cancers detected by screening in a population with a history of head and neck irradiation. *Cancer* 1980;46:1218-1227
7. Marmot-Dupuch K, Brunereau L. Uncommon presentation of thyroid cancer. *Ann Radiol* 1991;34:139-141
8. Hatabu H, Kasagi K, Yamamoto K, Iida Y, Misaki T, Hidaka A. Cystic papillary carcinoma of the thyroid gland: a new sonographic sign. *Clin Radiol* 1991;43:121-124
9. Shulkin BL, Shapiro B. The role of imaging tests in the diagnosis of thyroid carcinoma. *Endocrinol Metab Clin North Am* 1990;19:523-543

10. Auffermann W, Clark OH, Thurnher S, Galante M, Higgins CB. Recurrent thyroid carcinoma: characteristics on MR images. *Radiology* 1988;168:753-757
11. van den Brekel MW, Castelijns JA, Stel HV, Golding RP. Modern imaging techniques and ultrasound-guided aspiration cytology for the assessment of neck node metastases: a prospective comparative study. *Eur Arch Otorhinolaryngol* 1993;250:11-17
12. van Dungeon GA, Leverstein H, Roos JC, Quak JJ. Radioimmunosintigraphy of head and neck cancer using 99mTc-labeled monoclonal antibody E48 F. *Cancer Res* 1992;52:2569-2574
13. Som PM. Detection of metastasis in cervical lymph nodes: CT and MR criteria and differential diagnosis. *AJR Am J Roentgenol* 1992;158:961-969
14. Yousem DM, Som PM, Hackney DB, Schwaibold F, Hendrix RA. Central nodal necrosis and extracapsular neoplastic spread in cervical lymph nodes: MR imaging versus CT. *Radiology* 1992;182:753-759
15. van den Brekel MW, Castelijns JA, Croll GA, Stel HV, Valk J. Magnetic resonance imaging vs palpation of cervical lymph node metastasis. *Arch Otolaryngol Head Neck Surg* 1991;117:663-673
16. van den Brekel MW, Castelijns JA, Stel HV, Valk J, Croll GA. Detection and characterization of metastatic cervical adenopathy by MR imaging: comparison of different MR techniques. *J Comput Assist Tomogr* 1990;14:581-589
17. Som PM, Dillon WP, Fullerton GD, Zimmerman RA, Rajagopalan B, Marom Z. Chronically obstructed sinonasal secretions: Observations on T₁ and T₂ shortening. *Radiology* 1989;172:515-520
18. Barnes L. Tumors and tumorlike lesions of the soft tissues. In: Barnes L, ed. *Surgical pathology of the head and neck*. Vol 1. New York: Marcel Dekker, 1985:725-880