

Correct Placement of Epidural Steroid Injections: Fluoroscopic Guidance and Contrast Administration

Donald L. Renfrew¹
 Timothy E. Moore¹
 Mary H. Kathol¹
 Georges Y. El-Khoury¹
 Jon H. Lemke²
 Craig W. Walker¹

We prospectively evaluated 316 caudal-approach epidural steroid injections given by staff radiologists and residents in our department over a 1-year period. Needle placement was checked with fluoroscopy and corrected if necessary. When the needle tip was within the sacral canal, nonionic contrast material was injected. If epidural contrast was not observed, the needle tip was repositioned. Of 111 procedures performed by physicians who had given fewer than 10 epidural steroid injections, 53 (47.7%) resulted in correct nonfluoroscopically directed placement of the needle. For physicians who had performed between 10 and 50 such procedures, 62 (53.4%) of 116 had correct nonfluoroscopically directed placement. For staff physicians, 55 (61.7%) of 89 placements were correct. Even when the sacral hiatus was easily palpated and a staff physician was confident that he or she was within the epidural space, fluoroscopy revealed incorrect placement 14.2% of the time (seven of 49 procedures). In addition, when the needle was positioned within the sacral canal and no blood was evident on Valsalva maneuver or aspiration, the injection was venous in 29 of 316 procedures (9.2%). The presence of blood on the needle stylus was not a reliable indicator of venous placement of the needle.

Our findings indicate that fluoroscopy is essential for correct placement of epidural steroid injection. Contrast administration is necessary to avoid venous injection of steroids.

AJNR 12:1003-1007, September/October 1991

Epidural steroid injection (ESI) has been shown efficacious in the relief of low back pain [1-6]. For maximum benefit, the steroids injected must be within the epidural space. ESI is frequently performed as a clinical procedure without fluoroscopic guidance of needle placement. The epidural space may be accessed via either a caudal approach (with the needle placed through the sacral hiatus) or a lumbar approach (with the needle placed between two adjacent spinous processes in the lumbar spine). At our institution, we use the caudal approach for ESI.

We undertook this prospective study to answer four questions: (1) What is the accuracy of needle placement without fluoroscopic guidance? (2) What is the effect of training on physician ability to place the needle correctly? (3) When the needle is in an ideal position by fluoroscopy, is injection of contrast material necessary to confirm correct needle placement? (4) Is the presence of blood on the needle stylus an accurate indicator of venous placement of the needle tip?

Subjects and Methods

All patients referred to our department during a 1-year period were studied. There was a total of 328 patients, including 160 females and 168 males. The patients ranged in age from 16 to 92 years (mean, 52.1 years; median, 51 years). All patients had back pain or sciatica. Patient diagnoses included acute herniated nucleus pulposus, spinal stenosis, failed back surgery, and back pain of unknown cause.

Received February 7, 1991; revision requested April 2, 1991; revision received April 19, 1991; accepted April 23, 1991.

¹ Department of Radiology, The University of Iowa Hospitals and Clinics, Iowa City, IA 52242. Address reprint requests to D. L. Renfrew.

² Department of Preventive Medicine, College of Medicine, The University of Iowa, Iowa City, IA 52242.

0195-6108/91/1205-1003

© American Society of Neuroradiology

We used the technique of needle placement described by El-Khoury et al. [7]. Patients were initially placed prone, and the sacral hiatus palpated. Following sterile preparation, a physician attempted, without fluoroscopic guidance, to place a spinal needle within the sacral canal. When the physician was satisfied that he or she had done as good a job as possible without the use of fluoroscopy, the patient was rolled onto the left side and lateral fluoroscopy was performed. If the needle appeared to be within the sacral canal (Fig. 1), a spot film was exposed and the patient was returned to the prone position. If the needle was obviously posterior to the sacral canal, it was repositioned, with the patient either returning to the prone position or remaining in the decubitus position. If the needle was anterior, it was removed and discarded, the patient was placed in a prone position, and the procedure started over.

With the patient once more in the prone position and the needle apparently within the sacral canal, the needle stylus was removed and wiped on a clean cotton gauze (the wipe test). The patient was then instructed to perform a Valsalva maneuver. If blood was apparent in the needle hub, the needle was repositioned so that blood was no longer produced on the Valsalva maneuver. If no blood was seen, aspiration was performed. If blood was apparent on aspiration, the needle was repositioned. If CSF was apparent in the needle hub at any time, the procedure was canceled and rescheduled 1 week later. When fluoroscopy demonstrated correct needle placement and no CSF or blood was forthcoming on either Valsalva or aspiration, 1–5 ml of iopamidol 41% (Isovue-M 200, Squibb, New Brunswick, NJ) was injected. If the pattern of injection was venous (Fig. 2) or otherwise not epidural, the needle was repositioned. If the pattern of injection was epidural (Fig. 3), a spot film was taken for documentation. A volume of 3 ml (18 mg) of betamethazone (Celestone Soluspan Suspension; Shering, Kenilworth, NJ) was injected. This was followed by either 10 ml of diluted 0.25% bupivacain (1:5 mixture Marcaine [Winthrop-Breon, NY] with normal saline) or 1–10 ml of normal saline.

After the injection was completed, the physician filled out a study form regarding the procedure. This form included demographic data on the patient, the date of examination, and the physician's name. He or she also recorded whether it was easy, difficult, or impossible to palpate the sacral hiatus, how confident he or she was that the needle was in the correct position before fluoroscopy was performed, and whether the needle was indeed within the epidural space after blind needle placement. The results of the stylus wipe test, the Valsalva maneuver, and aspiration were recorded. The lateral and frontal spot films were reviewed to document where the needle was placed within the canal, both in the anteroposterior and transverse planes. Needle position following optimal placement by fluoroscopy was recorded: this was documented as either epidural, venous, intrathecal, or other. Physicians were urged to record comments about the procedure at the bottom of the form.

The data gathered were recorded in a database program (Microsoft Works; Microsoft Corp., Redmond, WA) for evaluation. All confidence intervals are exact 95% confidence intervals for binomial probabilities. The chi-bar-squared test of trend for ordered binomial proportions [8] was used to test for improvement in success of needle placement across levels of experience.

Results

Figure 4 shows the distribution of the 328 procedures. In seven cases, the patients had a history of previous contrast reaction so no contrast agent was administered. In five cases, physicians failed to place the needle within the epidural space despite multiple attempts (a failure rate of $5/328 = 1.5\%$). Of these five patients, two were osteoporotic elderly women and the needle tip persistently went into the substance of the sacrum (Fig. 5), one patient had a pilonidal cyst, one patient

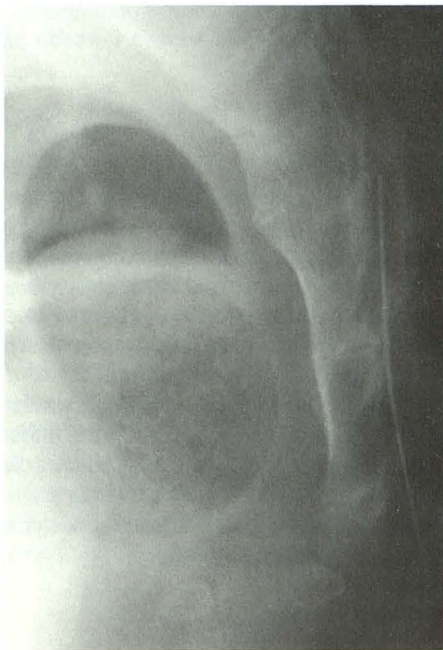


Fig. 1.—Lateral radiograph with needle appropriately positioned within sacral canal. Tip of needle is equidistant from anterior and posterior walls of the canal and lies at S3–S4 interspace.

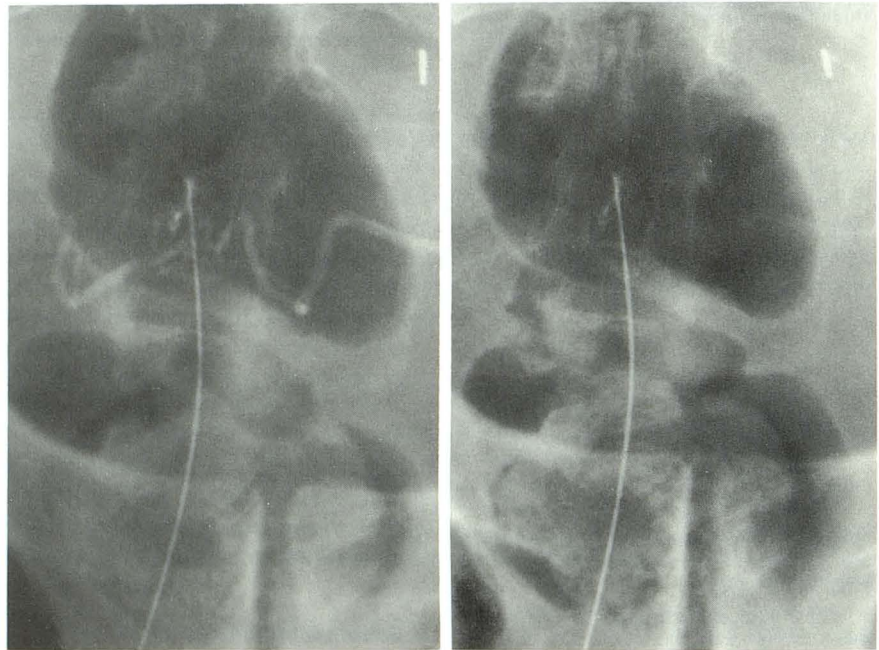


Fig. 2.—Radiographs showing IV needle placement. A, Contrast material is tubular in appearance. B, 20 sec after injection, contrast material has cleared from the veins.

Fig. 3.—Normal epidurogram.

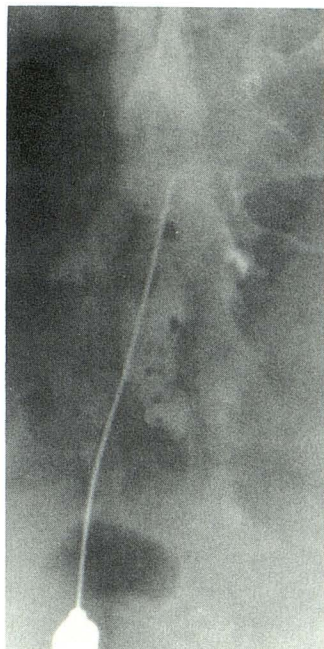
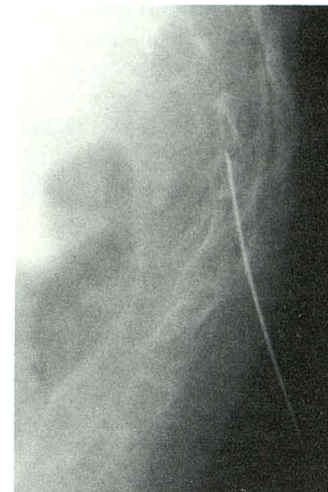


Fig. 5.—Radiograph shows intraosseous needle placement. In elderly, osteoporotic women, it is very easy to pass a 22-gauge needle through the cortex of the sacrum.



had CSF return following needle placement at S3 (the procedure was aborted and rescheduled; ESI was performed uneventfully 2 weeks later), and one patient had a curved sacrum (possibly from prior fracture) and a sacral canal that could not be negotiated. The seven procedures without contrast administration and the five unsuccessful procedures were not further analyzed.

The 316 remaining procedures (which resulted in epidurograms) were divided into those performed by inexperienced physicians who had done fewer than 10 ESIs, moderately experienced physicians who had performed 10–50 ESIs, and staff physicians who had performed more than 50 ESIs (Fig.

4). Figures 6, 7, and 8 diagram the performance of these physicians. The success rates of needle placement without fluoroscopy across increasing levels of experience were 47.7% (<10 ESI: 53/111: exact 95% confidence interval [38.1%, 57.5%]), 53.4% (10–50 ESI: 62/116: exact 95% confidence interval [43.9%, 62.8%]), and 61.8% (>50 ESI: 55/89: exact 95% confidence interval [50.8%, 71.9%]). These success rates increase significantly across levels of experience (chi-bar-squared test statistic = 3.932 with maximum degrees of freedom of 2 and *p* value = .0470). The success rates of the three staff physicians who performed more than 20 ESIs ranged from 60.5% to 66.7%. In the best of cases

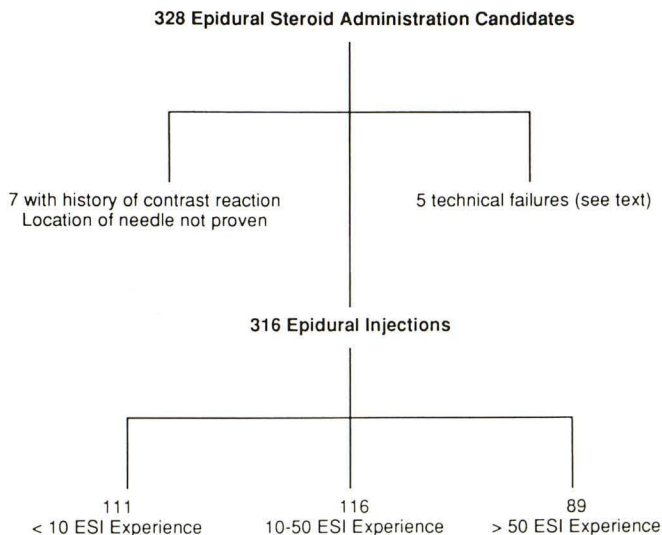


Fig. 4.—Diagram shows distribution of 328 epidural steroid administrations.

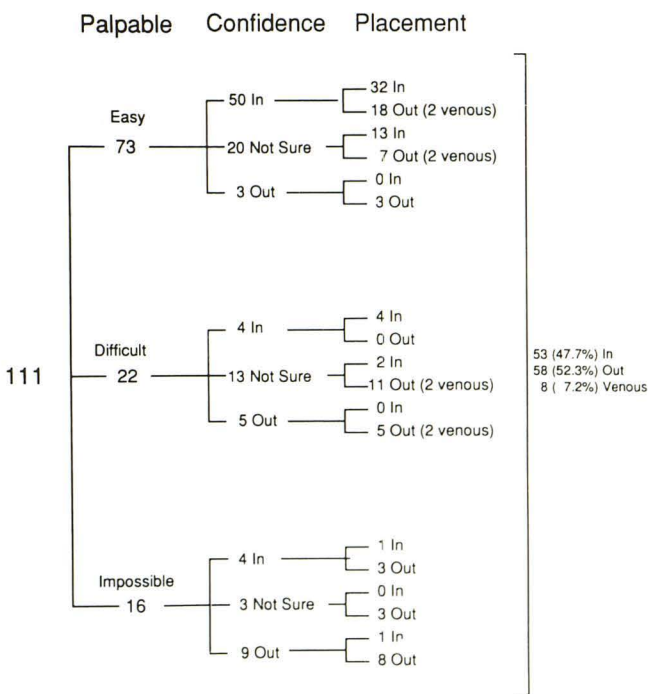


Fig. 6.—Diagram of performance of inexperienced physicians (<10 epidural steroid injections).

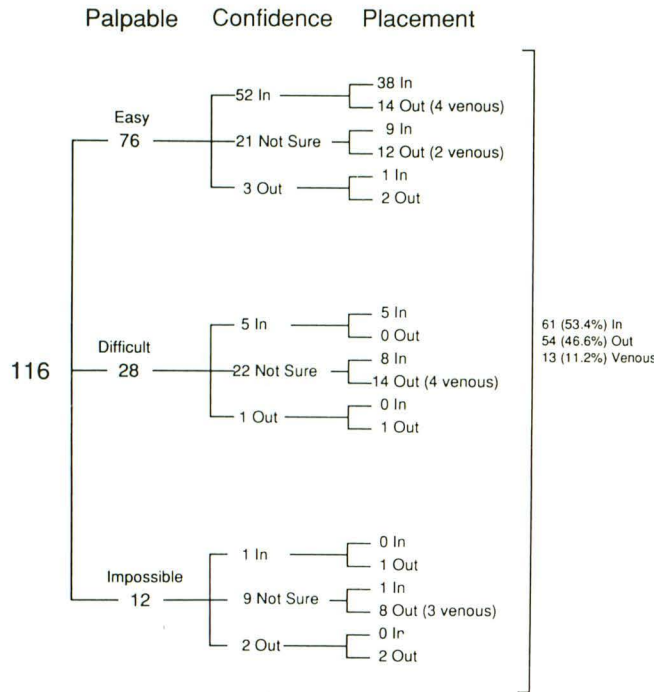


Fig. 7.—Diagram of performance of moderately experienced physicians (10–50 epidural steroid injections).

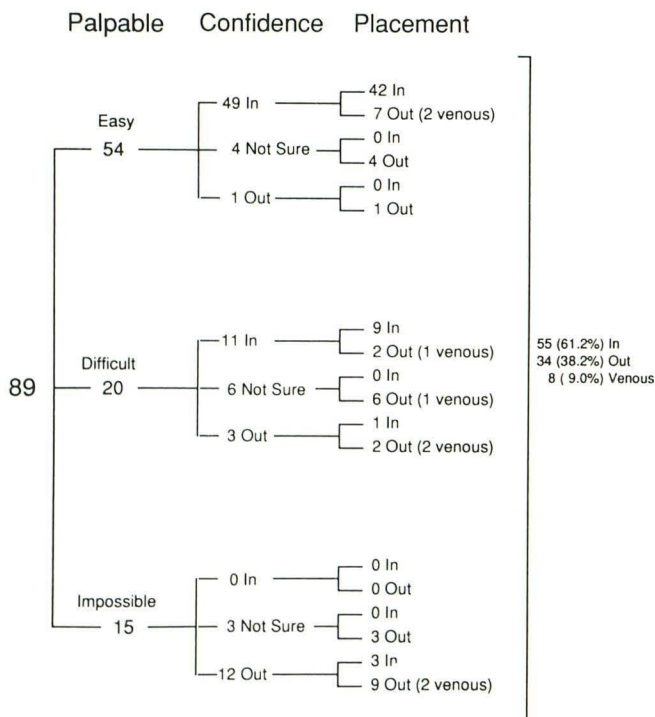


Fig. 8.—Diagram of performance of experienced physicians (>50 epidural steroid injections).

when the sacral hiatus was easily palpated and a staff physician was confident that he or she was within the epidural space, fluoroscopy and contrast injection revealed incorrect

placement 14.3% of the time (7/49: exact 95% confidence interval [5.9%, 27.3%]).

The presence of blood on the needle stylus (a positive wipe test) failed to indicate IV placement of the needle in 25 of 29 instances (a sensitivity of 13.8%) and was falsely positive 11 times.

Discussion

White et al. [6] found that blind needle placement for epidural steroid injection was incorrect 25% of the time with a caudal approach and 30% of the time with a lumbar approach. They also found that the needle could be within a vein despite the absence of blood from the needle on aspiration. They did not recommend routine use of fluoroscopy, however, and stated that in a cooperative patient with an easily palpated sacral hiatus, placement was correct 95% of the time. A previous description of the technique of ESI includes routine fluoroscopy and injection of nonionic contrast medium to confirm needle location prior to administration of steroids or anesthetic [7]. With increased experience with the technique, we considered the possibility of saving patients the charges associated with fluoroscopic guidance and injection of nonionic contrast material.

Our results demonstrate that physicians are frequently unable to place a needle blindly within the sacral canal. This inability shows some improvement with training: those who have performed fewer than 10 procedures are in the epidural space without fluoroscopic guidance 47.7% of the time; those with moderate experience, 53.4% of the time; and staff physicians, 61.7% of the time. When staff physicians performed the procedure on “easy” patients (those with a readily palpated hiatus) they were out 12/54 = 22.2% of the time. It is also of note that in 29/316 = 9.2% of cases, the needle was in a vein within the sacral canal, yet no blood was apparent on Valsalva maneuver or aspiration. Five of these 29 IV injections would have been avoided if a positive wipe test was taken as an indication of IV placement, but this same test was falsely negative in 25 cases and falsely positive in 11. The only sure way to tell if the needle tip is within an epidural vein is to observe the pattern of contrast following injection. Venous contrast will be tubular and transient (Fig. 2).

Our study did not address the lumbar approach to the epidural space, an approach frequently taken by anesthesiologists. The study by White et al. [6] indicates that anesthesiologists are not within the epidural space 30% of the time when they take this approach. These investigators also report that the two dural punctures that occurred during their study accompanied the lumbar approach. The serious complications of epidural steroid administration reported in the literature have followed inadvertent dural puncture, and have usually been encountered in lumbar approach procedures [9].

Our study also does not compare radiologists with orthopedic surgeons or neurosurgeons, who also perform the procedure via a caudal approach. It may be that other physicians are better at placing needles within the epidural space via a caudal approach. It is noteworthy that the levels of

performance among our staff physicians were so similar. We suspect that there is an inherent limit to the accuracy of nonfluoroscopically directed caudal access to the epidural space.

It is possible that physicians in our study may not have been as persistent in placing the needle within the sacral canal as they would have been if they were in a clinic where fluoroscopy was not available. While it is possible that physicians would have repositioned the needle when they suspected that they were not within the sacral canal, it would make little sense to reposition the needle if the physician was confident that he or she was within the sacral canal. Experienced staff physicians who were confident that the needle was correctly placed nonfluoroscopically were in fact out 9/60 = 15.0% of the time. It is also not clear that persistence would necessarily be rewarded in those patients with an impalpable sacral hiatus; repositioning of the needle may merely have subjected the patient to further discomfort without improving needle placement.

Epidurography was once used as an adjunct diagnostic technique for evaluation of patients with a wide ventral epidural space [10, 11]. Epidurography performed in this study was for the purpose of documenting correct position of administered steroids rather than diagnosis, and our injection volumes are smaller than those used for diagnosis. Prior articles [7, 10, 11], as well as Fig. 3, demonstrate the typical epidural pattern of contrast administration.

In summary, physicians are frequently unable to position a spinal needle within the epidural space via a caudal approach without the use of fluoroscopy. This inability demonstrates some improvement with training, but even experienced staff

physicians are often not within the epidural space, even with thin patients and even when they are confident that they are in the epidural space. In addition, it is possible to be within an epidural vein without blood on the spinal needle stylus or blood forthcoming during Valsalva maneuver or aspiration. Our results indicate that both fluoroscopy and contrast injection are necessary for accurate placement of epidural steroids.

REFERENCES

1. Burn JMB, Langon L. Lumbar epidural injection for the treatment of chronic sciatica. *Rheumatol Phys Med* 1970;10:368-374
2. Davidson JT, Robin GC. Epidural injections in the lumbosacral syndrome. *Br J Anaesth* 1961;33:595-598
3. Dilke TFW, Burry HC, Grahame R. Extradural corticosteroid injection in the management of lumbar nerve root compression. *BMJ* 1973;2:635-637
4. Heyse-Moore GH. A rational approach to the use of epidural medication in the treatment of sciatic pain. *Acta Orthop Scand* 1978;49:366-370
5. Warr AC, Wilkinson JA, Burn JMB, Langdon L. Chronic lumbosacral syndrome treated by epidural injection and manipulation. *Practitioner* 1972;209:53-59
6. White AH, Derby R, Wynne G. Epidural injections for the diagnosis and treatment of low-back pain. *Spine* 1980;5:78-86
7. El-Khoury TY, Ehara S, Weinstein JN, Montgomery WJ, Kathol MH. Epidural steroid injection: a procedure ideally performed with fluoroscopic control. *Radiology* 1988;168:554-557
8. Barlow RE, Bartholomew DJ, Bremer JM, Brunk HD. *Statistical inference under order restrictions*. New York: Wiley, 1972
9. Dougherty JH, Fraser RAR. Complications following intraspinal injection of steroids. *J Neurosurg* 1978;48:1023-1025
10. Roberson GH, Hatten HP, Hesselink JH. Epidurography: selective catheter technique and review of 53 cases. *AJR* 1979;132:787-793
11. Hatten HP. Lumbar epidurography with metrizamide. *Radiology* 1980;137:129-136