

Contrast-Enhanced MR Imaging of Malignant Brain Tumors

Moshe Graif¹
 Graeme M. Bydder¹
 Robert E. Steiner¹
 Peter Niendorf²
 David G. T. Thomas³
 Ian R. Young⁴

Magnetic resonance (MR) imaging was performed before and serially after intravenous injection of 1 mmol/kg gadolinium-DTPA (Schering) in 17 patients with clinical and histologic diagnoses of malignant cerebral tumors. There was a decrease of 1% in T1 and 10% in T2 in normal white matter and a decrease of 8% in T1 and 14% in T2 in normal gray matter. Contrast enhancement was observed in 16 of the 17 tumors. In the region of maximal enhancement a mean decrease of 16% in T1 was observed in low-grade gliomas, a mean decrease in T1 of 29% was seen in high-malignancy gliomas, and a mean decrease in T1 of 33% was observed in metastases. The decreases in T1 persisted for at least 50 min. In one case the central cystic region of the tumor displayed a decrease in T1 and T2. Measurements of signal intensity displayed maximal contrast enhancement with an IR 1500/500/44 sequence, much less with SE 1500/44, and least with SE 1500/80. Edema was observed on precontrast images in 14 cases, but satisfactory definition of the tumor-edema margin was only possible in four cases. After contrast enhancement this margin was defined in 10 cases. In four of the 17 cases areas of apparent "edema" seen before administration of Gd-DTPA displayed significant contrast enhancement and probably represented tumor infiltration. Comparison with CT showed a greater degree of contrast enhancement on MR images in eight cases, an equal degree in eight cases, and greater enhancement on CT in one case. Definition of the tumor-edema interface was better with MR in six cases and equal to CT in four cases. No significant toxic effects were found with the contrast agent. Gd-DTPA provided significant additional information over unenhanced MR imaging and enhanced CT.

The value of contrast enhancement was recognized soon after the introduction of cranial CT [1, 2]. The situation with magnetic resonance (MR) imaging is more complex. A greater level of soft-tissue contrast is available without contrast enhancement, and, unlike CT, no contrast agents suitable for parenteral use were available when the technique was first introduced. Nevertheless, particular situations have been defined, such as differentiation between tumor and edema, where contrast enhancement might be useful [3, 4], and recently the paramagnetic contrast agent gadolinium-DTPA has been tested in animals [5, 6] and used in clinical pilot studies [7-9]. In this report we extend our earlier clinical studies by examining the time course of enhancement produced by Gd-DTPA, comparing the degree of enhancement seen with different pulse sequences, monitoring side effects, and assessing the overall clinical efficacy relative to CT.

Subjects and Methods

Permission for the study was obtained from the Royal Postgraduate Medical School Research Ethics Committee, and permission for the use of Gd-DTPA was obtained from the Department of Health and Social Security, medicine division. Informed consent was obtained from each patient.

Primary cerebral tumors were histologically identified in 12 patients. A further patient with a clinical, radiologic, and MR diagnosis of primary cerebral tumor was included although she refused biopsy. Two further patients had direct histologic evidence (biopsy) of a secondary

Received March 6, 1985; accepted after revision June 12, 1985.

This work was supported in part by Schering A.G., Berlin (Gd DTPA), and Medical Research Council, Department of Health and Social Security.

¹ Department of Diagnostic Radiology, Royal Postgraduate Medical School, Hammersmith Hospital, Du Cane Rd., London W12 0HS, United Kingdom. Address reprint requests to M. Graif, NMR Unit.

² Schering AG, Berlin, West Germany.

³ Department of Neurosurgery, Maida Vale Hospital, Maida Vale, London W9, United Kingdom.

⁴ Picker International, Hirst Research Centre, Wembley, Middlesex, United Kingdom.

AJNR 6:855-862, November/December 1985
 0195-6108/85/0606-0855

© American Roentgen Ray Society

TABLE 1: Clinical Diagnoses in Patients Studied with Contrast-Enhanced MR Imaging

Category of Lesion: Clinical Diagnosis	No. of Patients
Low-grade primary lesions:	
Glioma I	3
Astrocytoma I and II	3
Oligodendroglioma	1
High-grade primary lesions:	
Astrocytoma III	2
Glioblastoma	1
Malignant ependymoma	1
Metastatic lesions:	
Small cell carcinoma of lung	1
Oat cell carcinoma of lung	1
Carcinoma of lung	1
Adenocarcinoma of unknown origin	1
Suspected primary tumor (no histology)	1
Total	17

TABLE 2: Pulse Sequences Used in Contrast-Enhanced MR Imaging of Malignant Brain Tumors

Pulse Sequence	Interval (msec)		
	TR	TI	TE
IR 1500/500/44	1500	500	44
SE 1500/44	1500	...	44
SE 1500/80	1500	...	80

Note.—TR = repetition time; TI = inversion time; TE = echo time; IR = inversion recovery; SE = spin echo.

lesion in the brain (amelanotic melanoma in one case and adenocarcinoma of unknown origin in the other). Two other patients had histologically proven lung carcinomas with multiple brain lesions consistent with metastatic spread, although the cerebral lesions were not biopsied. The diagnoses are summarized in table 1.

The MR imager used for this study has been described [10]. It operates at 0.15 T, and in this study one inversion-recovery (IR) sequence and two spin-echo (SE) sequences were used (table 2). Preenhancement scans were obtained using these three sequences, which were repeated serially after injection of Gd-DTPA. The time of injection and that of subsequent scans were recorded.

Gd-DTPA was injected in a dose of 0.1 mmol/kg after determination of baseline values of blood urea, creatinine, electrolytes (Na⁺, K⁺, HCO₃⁻), liver function tests (bilirubin, aspartate transaminase, alkaline phosphatase, total protein), serum iron, blood screen (hemoglobin, red blood cell count, platelets), and coagulation studies. The same tests were repeated 2 and 24 hr after injection of Gd-DTPA.

Signal intensity measurements were obtained directly from the images. Computed T1 and T2 maps were produced by numeric solutions of the equations published elsewhere [10] using the three sequences listed in table 2. Regions of interest (ROIs) were obtained for normal white and gray matter as well as the region of maximal enhancement of the tumor and the central region of the tumor. ROIs were also placed in regions of apparent edema surrounding the tumor. Four measurements were taken in each case, and the mean was used in these studies. The mean time for T1 determination was 17 min for the first cycle and 45 min for the second one. Determination of T2 values were obtained at 37 and 60 min after injection. Since the T2 maps reflecting the T2 values were calculated from two different T2 images of the same slice with the same TR, there was a

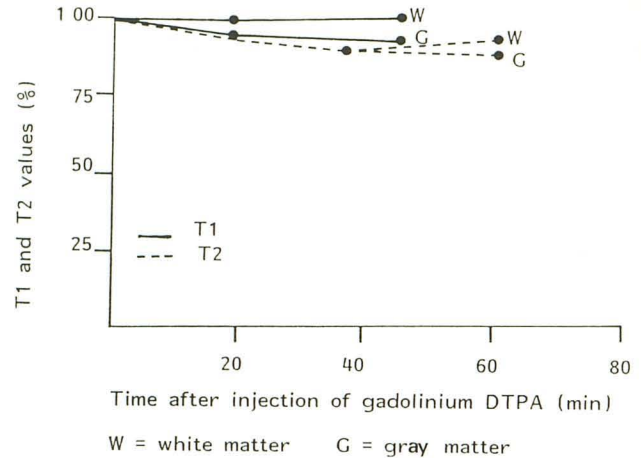


Fig. 1.—Mean change in relaxation times of normal gray and white matter after injection of Gd-DTPA.

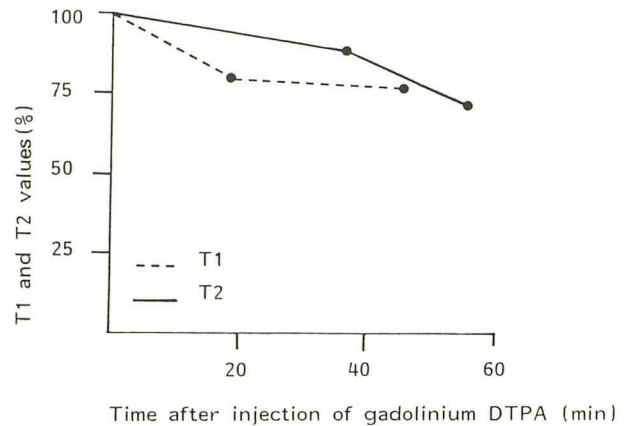


Fig. 2.—Mean percentage change of T1 and T2 in region of maximal contrast enhancement of malignant tumors after injection of Gd-DTPA.

time lapse between the images related to the acquisition times. The times for the T2 values, therefore, were the mean time of the different images. In the sequence comparison table each sequence was represented individually with the respective time determination.

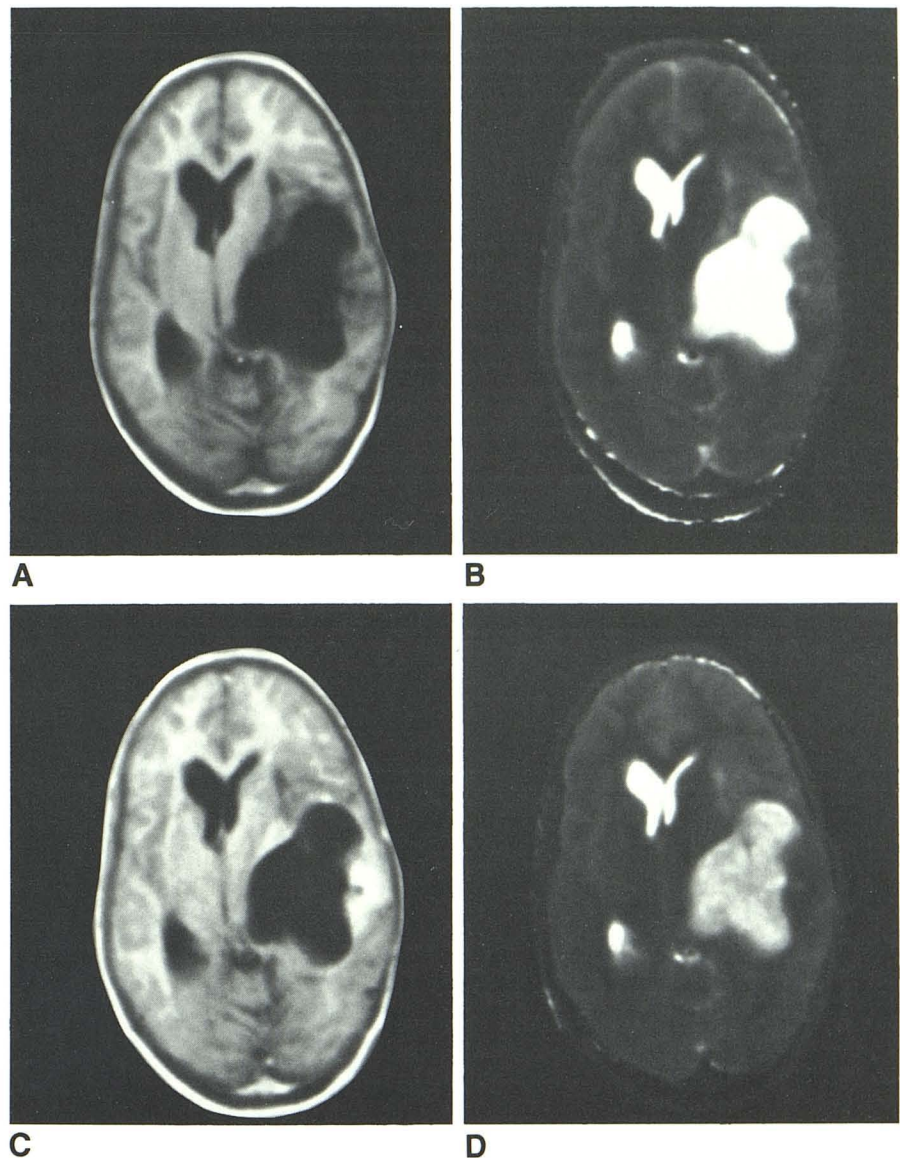
CT studies before and after enhancement were available within days of the MR scan in all cases. CT scans were obtained with a Siemens Somatom II scanner (six cases), GE 8800 scanner (four cases), and an EMI CT 1010 scanner (seven cases).

Results

Normal Brain

Contrast enhancement was apparent as a slight reduction in gray/white-matter difference after injection of Gd-DTPA. White matter displayed a mean reduction in T1 of 1%, while gray matter showed a mean reduction of 8% in T1. The corresponding decrease of T2 was 10% in white matter and 14% in gray matter. The time course of this decrease in

Fig. 3.—Astrocytoma grade III. Precontrast IR (A) and T1 (B) images compared with postcontrast IR (C) and T1 (D) images. Reduction in T1 within cystic component is clearly visible on T1 maps after enhancement (D). For comparison, no change was observed in cerebrospinal fluid.



relaxation times is shown in figure 1. Enhancement was also observed in arteries, veins, and sinuses.

Cerebral Tumors

Contrast enhancement was observed in 16 of 17 cases; the pattern of enhancement was ring-shaped in nine cases, diffuse in seven, patchy in four, and linear in one.

Measurements in the region of maximal contrast enhancement displayed on the last set of scans in each case showed a mean decrease of 22% in T1 and a mean decrease of 21% in T2. The decrease in T1 and T2 increased with time. The time course of this enhancement is displayed in figure 2.

Measurements of T1 and T2 in the central region of the tumor showed no significant change in eight cases, but in nine cases there was a significant reduction. This included

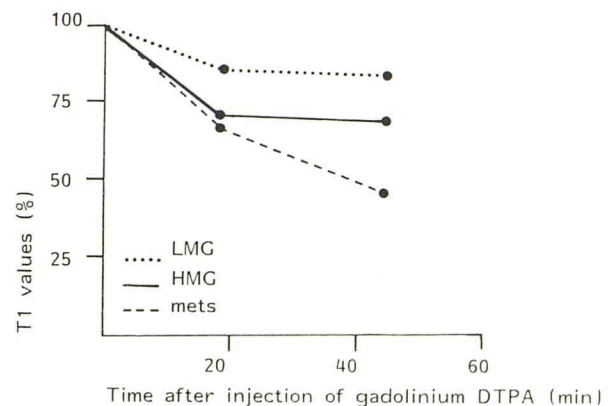


Fig. 4.—Time course and mean changes of T1 in low-malignancy tumors (LMG), high-malignancy tumors (HMG), and metastatic lesions (mets).

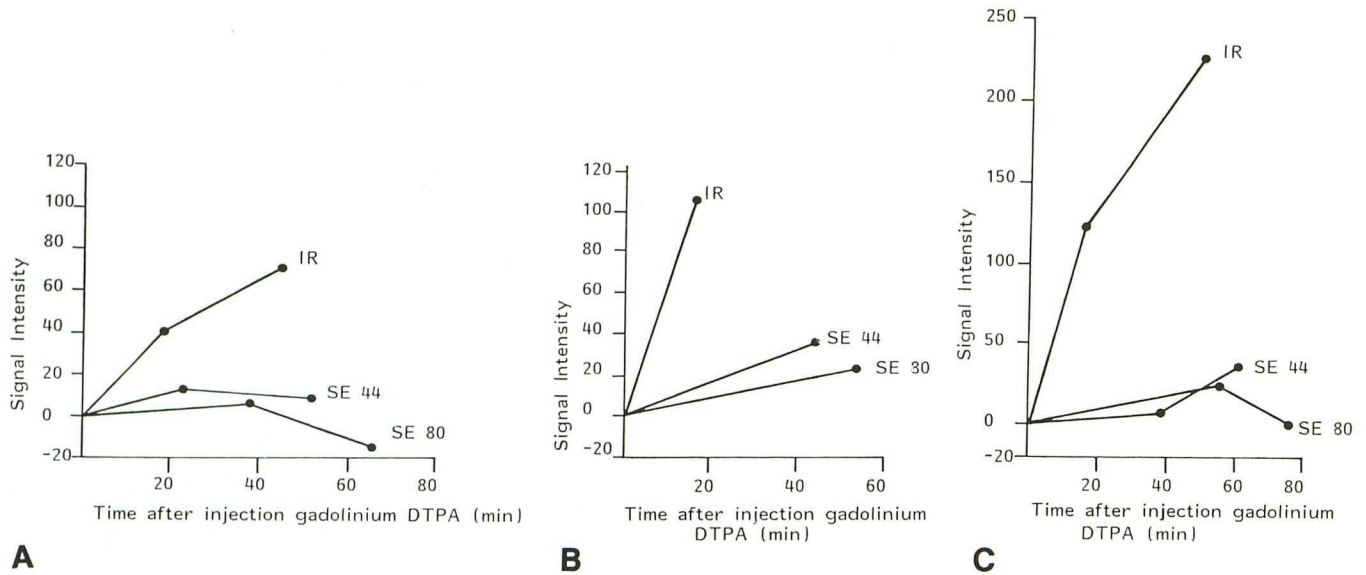


Fig. 5.—Comparison of signal IR 1500/500/44 (IR), SE 1500/44 (SE 44), and SE 1500/80 (SE 80) pulse sequences before and after Gd-DTPA. Baseline level (0) represents preenhancement scan; numbers along vertical axis represent arbitrary signal intensity units. Comparison was carried out for low-grade

malignancies (A), high-grade malignancies (B), and metastatic lesions (C). Maximal enhancement is seen with IR 1500/500/44 sequence. "Negative enhancement" is obtained with SE 1500/80 sequence after 60 min (A); actual pixel value is lower than original value on preenhancement scan by 13 units.

one case in which the central region of the tumor was found to be cystic at surgery (fig. 3).

The time course of enhancement was compared for the three groups of tumors listed in table 1 and is displayed in figures 4 and 5. The primary tumors of low-grade malignancy showed a mean decrease in T1 of 16%, the primary tumors of high-grade malignancy displayed a mean decrease in T1 of 29%, and the metastatic tumors displayed a mean decrease in T1 of 33% (fig. 4).

The changes in signal intensity in the three different sequences in the area of maximal enhancement were compared (fig. 5). The greatest increase in signal intensity was seen with the IR 1500/500/44 sequence, the next greatest with SE 1500/44, and least enhancement was seen with SE 1500/80 (fig. 6).

Maximal enhancement was displayed 20–40 min after injection for the low-malignancy tumors, after which the signal intensity decreased. In the other two groups (of higher malignancy grade), maximal enhancement was displayed between 40 and 60 min. In all groups the decrease of signal occurred earlier in time for the SE sequences than for the IR sequences (fig. 5).

Peritumoral Edema

Areas with appearances consistent with peritumoral edema were seen on the preenhancement scans in 14 cases. These were best seen on the IR 1500/500/44 sequence in eight cases, on the SE 1500/44 in one case, and on the SE 1500/80 in five cases. Radiologic separation of tumor from edema was possible in four cases.

After intravenous Gd-DTPA, 10 of the patients showed no

change in relaxation time in the area of edema (fig. 7), but in four cases a 22%–31% decrease in T1 and T2 was seen (figs. 8 and 9).

The increase in signal intensity was obvious on the IR 1500/500/44 scans, but the SE 1500/44 and SE 1500/80 scans did not show significant change in signal intensity. It was thought likely that the areas of apparent edema in these four cases probably represented tumor infiltration.

Comparison with CT

Comparison with CT was limited by the fact that seven of the CT scans were obtained with a second-generation scanner (EMI CT 1010). On overall subjective assessment the degree of enhancement was greater with MR in eight cases and equal to CT in eight cases. In one case (tiny metastatic lesions of small-cell lung cancer), the lesions enhanced better on the CT scan. Separation of tumor from edema was better with MR in six cases, equal in four cases, and better with CT in no cases. The four regions of apparent edema subsequently thought to be infiltrating tumor with MRI did not display contrast enhancement with CT. Additional metastases were seen with MR in one of the cases of metastatic tumor.

Side Effects

One patient noted a transient metallic taste and another felt faint immediately after injection of Gd-DTPA. These symptoms lasted about 1–2 min. No significant change was noted in any of the biochemical or hematologic parameters, except for a transient rise in the serum iron at 2 hr after injection in

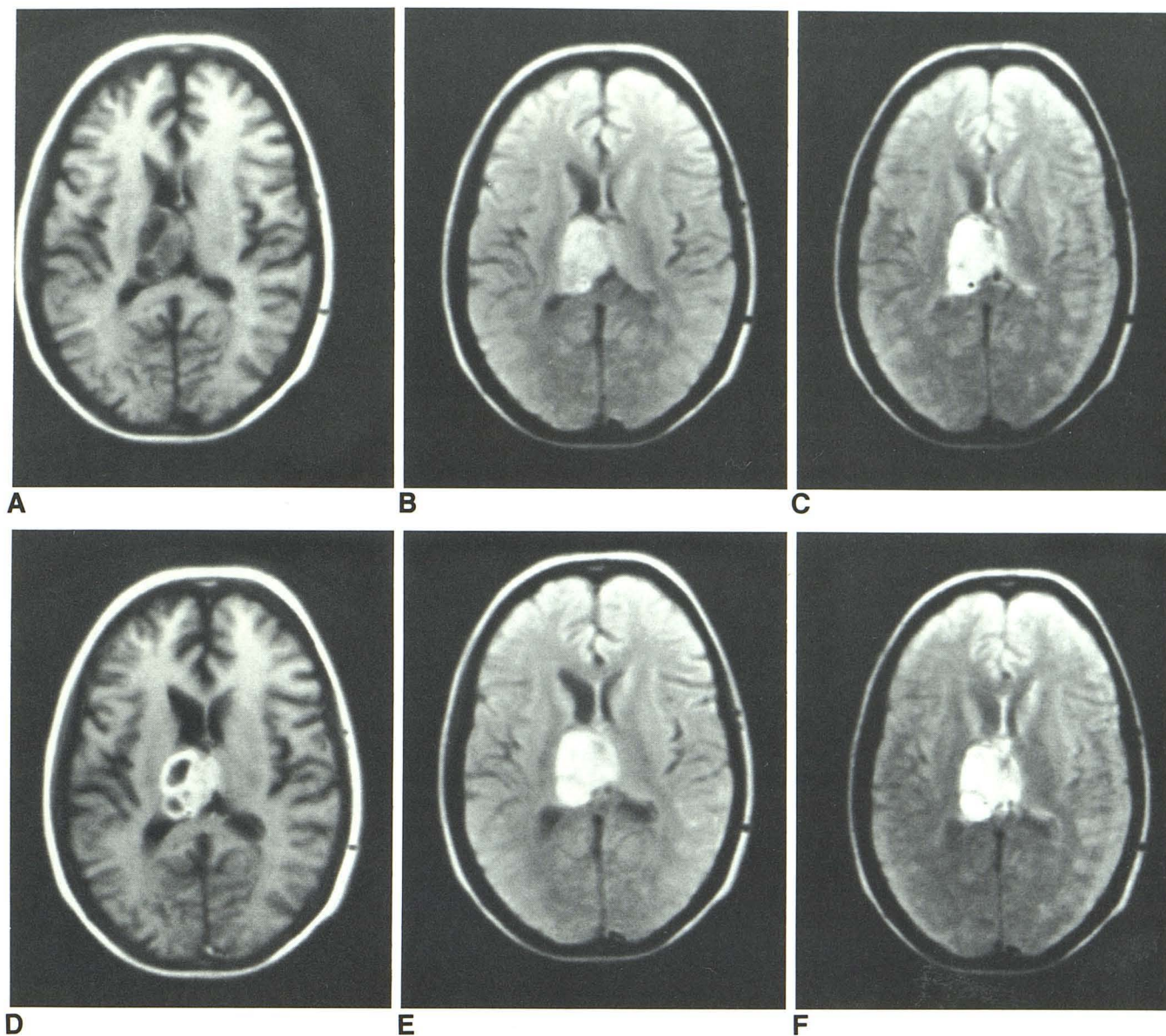


Fig. 6.—Grade III astrocytoma. Pre- (A–C) and post- (D–F) enhancement IR 1500/500/44 (A and D), SE 1500/44 (B and E), and SE 1500/80 (C and F) images. Maximal enhancement is seen between A and D.

two patients. The serum iron returned to normal in both patients within 24 hr.

Discussion

Gd-DTPA is an effective contrast agent producing consistent reduction in tumor T1 and T2. It is distributed within the vascular compartment and excreted unchanged by glomerular filtration through the kidneys with 80% eliminated within 3 hr. More detail about its pharmacology has been published [5, 6, 8].

The high molecular weight of Gd-DTPA (590) is similar to that of diatrizoate, commonly used with CT, and its marked hydrophilic properties probably account for the fact that it

does not appear to cross the normal blood-brain barrier. In the presence of pathology, Gd-DTPA appears to cross the abnormal blood-brain barrier in a manner similar to that described for iodinated contrast agents [5].

The contrast enhancement continued for up to 60 min. This can also occur with CT, where prolonged enhancement of brain lesions has been described in conditions in which blood-brain barrier breakdown was associated with extravascularization of iodinated contrast material into the lesion [11].

The increased level of contrast enhancement found with highly malignant primary tumors and cerebral metastases when compared with low-malignancy tumors is also comparable to CT [12–14]. The decrease in T1 and T2 found in the cystic components of a tumor suggests that Gd-DTPA has

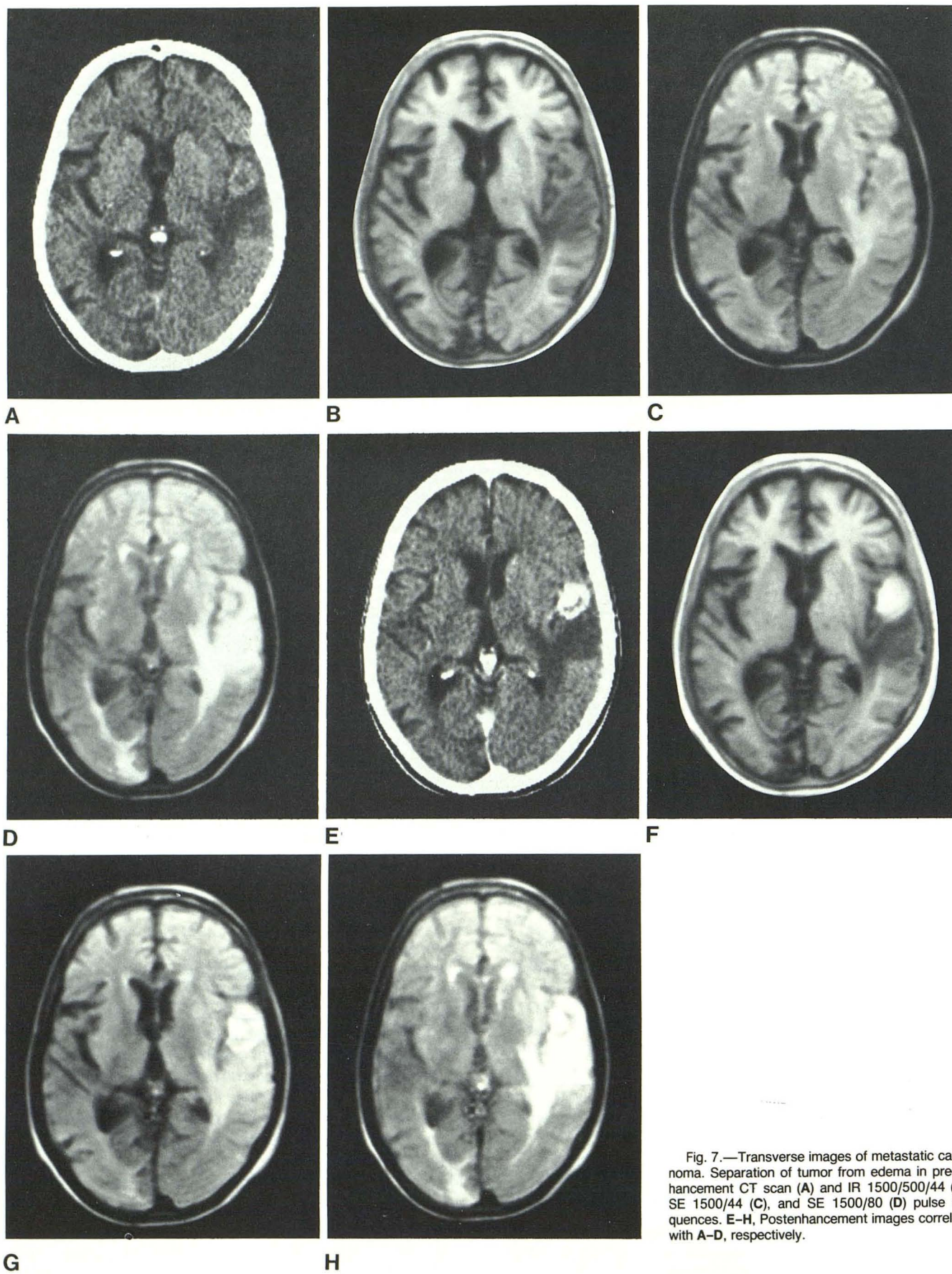


Fig. 7.—Transverse images of metastatic carcinoma. Separation of tumor from edema in pre-enhancement CT scan (A) and IR 1500/500/44 (B), SE 1500/44 (C), and SE 1500/80 (D) pulse sequences. E-H, Postenhancement images correlate with A-D, respectively.

Fig. 8.—Preenhancement CT image (A) of lesion secondary to lung carcinoma. IR scan (B) shows more extensive abnormality (arrows), suggestive of edema. After enhancement, no change is observed in this area (except ring enhancement) on CT (C), while enhancement causing isointensity is clearly visible on MR (D).

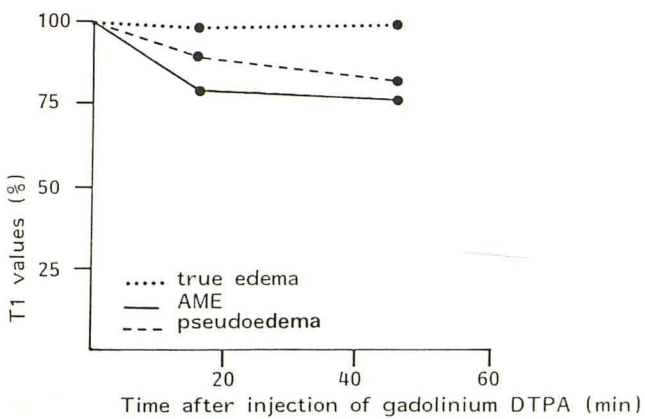
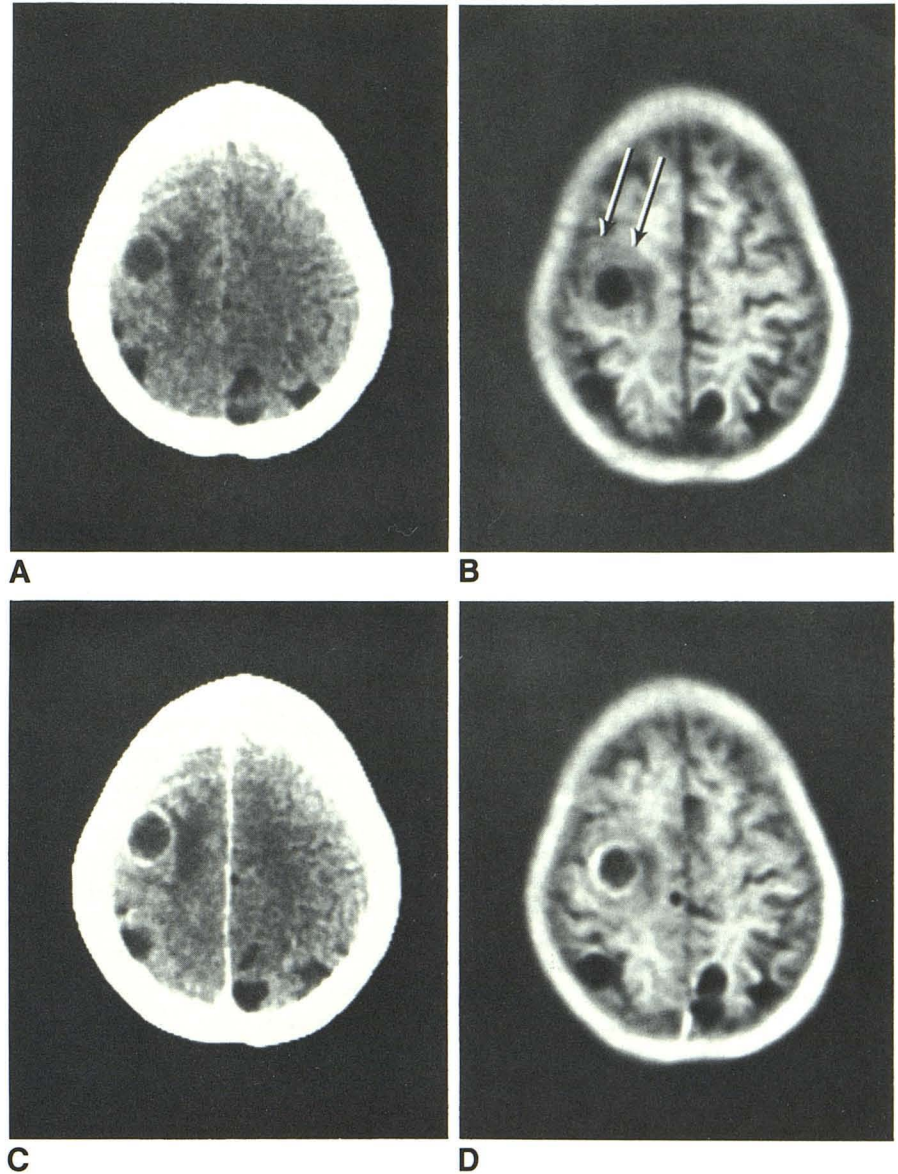
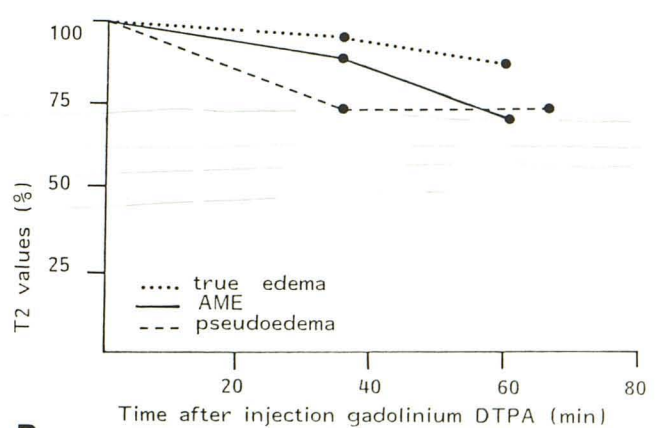


Fig. 9.—Graphic representation of T1 (A) and T2 (B) changes after injection of contrast material. Minimal or no change was observed in true edematous area, significant decrease of T1 and T2 values was seen in pseudoedematous



region, almost to same degree as in area of maximal enhancement (AME) of lesion. (AME and edema T1 and T2 values reflect only the four cases in which this phenomenon occurred.)

diffused into this compartment, as happens with CT [15].

Sequence comparison showed that the IR 1500/500/44 was significantly better than the two SE sequences in demonstrating contrast enhancement. While long TR/long TE SE sequences are sensitive to pathologic differences, they are relatively insensitive to contrast enhancement. If a tumor is detected with this latter type of sequence, minimal additional information is likely to be obtained by repeating the same sequence alone after intravenous Gd-DTPA.

Another important feature is that signal intensity (fig. 5) initially increases and later decreases while the concentration of Gd-DTPA (as expressed by the reduction of relaxation times) is still increasing (fig. 4). The peak and the following decrease in signal intensity is reached at a lower level with the two SE sequences than with the IR sequence. Our experimental results are consistent with the theoretic results described by Gadian et al. [16], indicating that for low concentrations of Gd-DTPA (below 1 mmol), the shortening of T1 gives a signal increase that eventually is negated by the reduction in T2 at high concentrations. The optimal concentration for the SE sequences used was achieved at 20–60 min. The IR sequence, having greater T1 dependence, results in continuing higher signal intensity with the increase of contrast concentration. Since the time course for the IR sequence in our clinical study lasted on average less than 50 min, its optimal time of examination was not determined.

The results in peritumoral edema are of particular interest. Definition of the margin between tumor and edema was better after contrast enhancement. In general edema did not enhance, as found in a canine model studied by Brasch et al. [6]. The enhancement seen in areas thought to be edema in four cases probably indicates areas of tumor infiltration.

Comparison with CT has to be treated with caution because seven of the 17 cases were examined with a second-generation scanner rather than a third- or fourth-generation one. Nevertheless, equal or greater enhancement was seen with MR in all cases; better definition of the margin between tumor and edema was also observed, and the four areas of "edema" enhancement (probably representing tumor) were not detected with CT.

In conclusion, Gd-DTPA is an effective contrast agent, and enhancement persists for at least 50–80 min. The IR sequence is most sensitive to contrast enhancement, with SE sequences much less sensitive. The results compare favorably with CT, and the principal clinical application appears to be the identification of areas of tumor and edema. Toxicity appears low.

REFERENCES

1. Ambrose J. Computerized transverse axial scanning (tomography). Part 2: clinical application. *Br J Radiol* **1973**;46:1023–1047
2. Ambrose J. Sodium iothalamate as an aid to diagnosis of intracranial lesions by computerized transverse axial scanning. *Lancet* **1975**;2:669–674
3. Bydder GM, Steiner RE, Young IR, et al. Clinical NMR imaging of the brain: 140 cases. *AJNR* **1982**;3:459–480, *AJR* **1982**;139:215–236
4. Bydder GM, Pennock JM, Steiner RE, Orr JS, Bailes DR, Young IR. The NMR diagnosis of cerebral tumors. *J Magnetic Resonance Med* **1984**;1:5–29
5. Weinmann H-J, Brasch RC, Press WR, Wesbey GE. Characteristics of gadolinium-DTPA complex: a potential NMR contrast agent. *AJR* **1984**;142:619–624
6. Brasch RC, Weinmann H-J, Wesbey GE. Contrast enhanced NMR imaging: animal studies using gadolinium-DTPA complex. *AJR* **1984**;142:625–630
7. Carr DH, Brown J, Bydder GM, et al. Intravenous chelated gadolinium as a contrast agent in NMR imaging of brain cerebral tumours. *Lancet* **1984**;1:484–486
8. Schonner VW, Felix R, Laniado M, et al. Prung des Kernspintomographischen Kontrastmittels Gadolinium-DTPA am Menschen. *ROFO* **1984**;140:495–500
9. Carr DH, Brown J, Bydder GM, et al. Gadolinium-DTPA as a contrast agent in MRI: initial clinical experience in 20 patients. *AJR* **1984**;143:215–224
10. Young IR, Bailes DR, Burl M, et al. Initial clinical evaluation of an NMR tomograph. *J Comput Assist Tomogr* **1982**;5:1–18
11. Kramer RA, Janetos GP, Perlstein G. An approach to contrast enhancement in computed tomography of the brain. *Radiology* **1975**;117:589–593
12. Sage MR. Review. Blood-brain barrier: phenomenon of increasing importance to the imaging clinician. *AJNR* **1982**;3:127–138, *AJR* **1982**;138:887–898
13. Caille JM, Guibert-Tranier F, Calabet A, Billerey J, Piton J. Abnormal enhancement after contrast injection. In: Caille JM, Salamon G, eds. *Computerized tomography*. Berlin: Springer, **1980**:166–171
14. Gado MH, Phelps ME, Coleman ER. An extravascular component of contrast enhancement in cranial computed tomography. *Radiology* **1975**;117:589–593
15. du Boulay GH, Isherwood I, Kendall B, Moseley I. Computerized tomography of the head. In: du Boulay GH, ed. *Textbook of radiological diagnosis*, vol 1. London: Lewis, **1984**:98
16. Gadian DG, Payne JA, Bryant DJ, Young IR, Carr DH, Bydder GM. Gadolinium-DTPA as a contrast agent in MRI—theoretical projections and practical observations. *J Comput Assist Tomogr* **1985**;9:242–251