

# Contrast-Enhanced MR Images in Patients with Meningioma: Importance of Enhancement of the Dura Adjacent to the Tumor

Shigeki Aoki<sup>1</sup>  
Yasushi Sasaki  
Tohru Machida  
Hisaya Tanioka

Linear enhancement (flare sign) along the dura mater that was continuous with or emanated from the dural margin of meningiomas was frequently observed on contrast-enhanced MR images obtained in 18 patients with intracranial meningiomas (surgically proved). Preoperative MR studies obtained at 1.5 T after administration of gadopentetate dimeglumine were reviewed retrospectively to determine the clinical significance of this sign. Thirteen (72%) of the 18 meningiomas exhibited the finding adjacent to the dural attachments. Four meningiomas of the cerebellopontine angle showed enhancement along the internal auditory canals. Three specimens of the dura adjacent to the tumor in different patients with this finding revealed proliferation of connective tissues abounding with vessels along the dura without definite tumor invasion.

The flare sign is thought to be a common finding of meningiomas on contrast-enhanced MR images obtained with high-resolution sequences, and it is observable without tumor invasion. This sign in the cerebellopontine angle should not be misinterpreted as enhancement of acoustic schwannomas.

*AJNR* 11:935-938, September/October 1990

Gadopentetate dimeglumine has been reported to be a useful contrast agent for MR [1-6]. It shortens T1 and T2 relaxation times and, because of the shortened T1 relaxation time, on short TR/TE images many CNS lesions exhibit enhancement similar to that seen with iodine contrast on CT.

There are a few normal intracranial structures that exhibit different enhancement on MR compared with iodine contrast enhancement on CT, such as flowing vessels and the dura mater [7]. The dura mater usually shows only minimal enhancement on MR after contrast injection, whereas on CT it shows strong enhancement. Therefore, subtle pathologic enhancement along the dura can be detected primarily by MR, because on CT strong enhancement of normal structures may obscure subtle abnormalities.

Meningiomas are dural-based tumors and are frequently associated with hyperostosis, dural invasion, and development of abnormal vessels. On MR, they are often isointense on both short and long TR/TE images [8-10]; therefore, gadopentetate dimeglumine may be extremely helpful and occasionally necessary for the detection of meningiomas [2-6].

We observed linear enhancement (flare sign) along the dura adjacent to meningioma and retrospectively evaluated the clinical significance of this phenomenon.

## Materials and Methods

We retrospectively reviewed the MR studies from 18 patients with surgically proved meningiomas who had gadopentetate-dimeglumine-enhanced (0.1 mmol/kg weight) MR imaging between May 1986 and April 1989. The patients were 27-87 years old and included six men and 12 women (see Table 1). The patients were studied preoperatively on a 1.5-T

Received October 17, 1989; revision requested December 17, 1989; revision received March 7, 1990; accepted March 11, 1990.

<sup>1</sup>All authors: Department of Radiology, Faculty of Medicine, University of Tokyo, 7-3-1 Hongo, Bunkyo-ku, Tokyo 113, Japan. Address reprint requests to S. Aoki.

0195-6108/90/1105-0935  
© American Society of Neuroradiology



superconductive MR imager (Magnetom, Siemens). Postcontrast, 500–600/14–28 (TR/TE), images with spin-echo pulse sequences were evaluated. Imaging planes were routinely coronal and axial and occasionally sagittal. Scans were obtained immediately after injection of contrast material.

Flare sign was diagnosed when all of the following conditions were met: (1) linearly enhanced areas along the dura mater originating from and extending outward from the tumor margin; (2) linear enhancement was greater than similar regions contralaterally or greater than distant dura when midline structures were involved; (3) findings were observed in two different planes; and (4) there was unanimous agreement among the three observers.

Three specimens, which were resected with preservation of the relationship between the tumor and the dura mater adjacent to the

attachments, were compared with the MR findings. Only three convexity lesions could be studied in this manner, since many tumors, especially those that were deep seated, were removed piece by piece or removed separately from the surrounding dura, and we could not evaluate the exact relationship between the tumor and the continuous dura.

## Results

Thirteen (72%) of the 18 meningiomas showed linear enhancement along the dura originating from the margins of the tumors in ways that satisfied our criteria for the flare sign (Figs. 1–5). The locations and presence of the sign are summarized in Table 1.

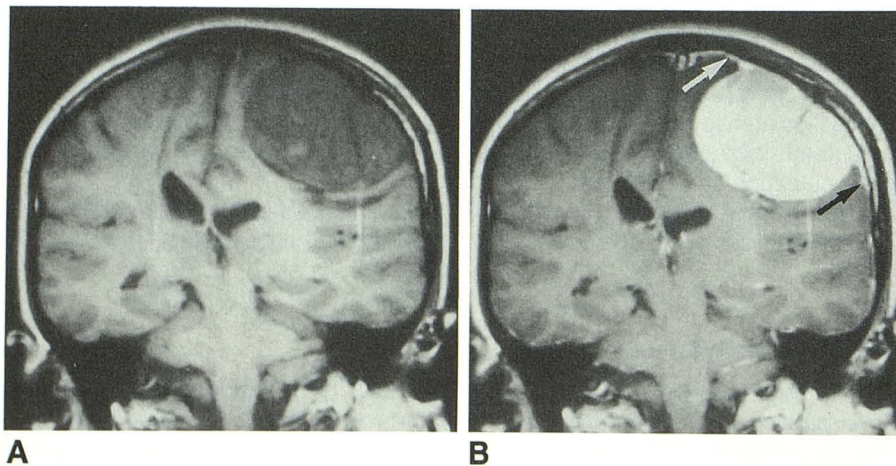
Three resected tumor specimens (cases 1, 3, and 4) with good preservation of the relationship between the tumor and the adjacent dura mater revealed tumor cells just below the attachments; however, tumor invasion was not noted sufficiently distant from the point of attachment to account for all the observed enhancement. There was relatively poorly organized connective tissue abounding with vessels within the dense, highly organized connective tissue of the intact dura mater (Fig. 5).

## Discussion

Gadopentetate dimeglumine is a chelated compound with the molecular weight of about 1000 [11, 12]. Its pattern of enhancement in the CNS has been reported to be similar to that of iodinated contrast because of their similar molecular weight [12]. Distribution of both gadopentetate dimeglumine and iodine contrast within the CNS is related to destruction or absence of the blood-brain barrier [2, 7]. Common exceptions to this similarity are flowing vessels and the dura. Kilgore et al. [7] reported that enhancement of the falx and tentorium is not as evident on MR as on CT. They speculated that these structures do not have a significant degree of vascularity, extracellular fluid, or capillary plexus to exhibit enhancement, although gadopentetate dimeglumine leaks into the extravascular space.

**TABLE 1: Summary of Findings in 18 Patients with Meningiomas on Gadopentetate-Dimeglumine-Enhanced MR Images**

Case No.	Age (years)	Sex	Location of Tumor	Flare Sign	Location of Flare Sign
1	27	F	Convexity	+	Convexity
2	57	M	Convexity	+	Convexity
3	60	M	Convexity	+	Convexity
4	72	F	Convexity	+	Convexity
5	73	F	Convexity	+	Convexity
6	49	F	Falx	+	Falx
7	61	F	Falx	–	
8	55	M	Parasagittal	+	Convexity, falx
9	35	F	Parasellar	+	Posterior fossa
10	48	F	Tentorium	–	
11	53	F	Tentorium	+	Tentorium, posterior fossa, internal auditory canal
12	57	M	Tentorium	–	
13	59	M	Tentorium	+	Tentorium, posterior fossa, internal auditory canal
14	37	F	Posterior fossa	+	Posterior fossa
15	46	F	Posterior fossa	+	Posterior fossa, internal auditory canal
16	47	M	Posterior fossa	–	
17	70	F	Posterior fossa	+	Posterior fossa, internal auditory canal
18	87	F	Posterior fossa	–	



**Fig. 1.—Case 1: 27-year-old woman with convexity meningioma.**

**A,** Coronal SE 500/17 noncontrast MR image shows decreased signal lesion broadly attached to left calvarium.

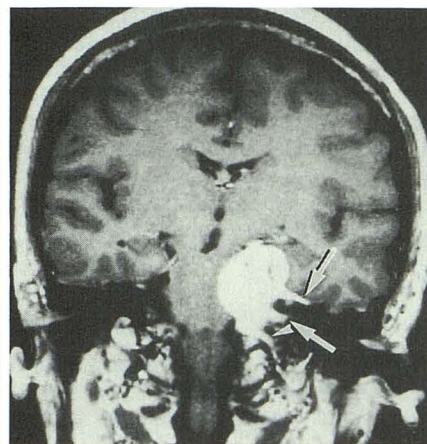
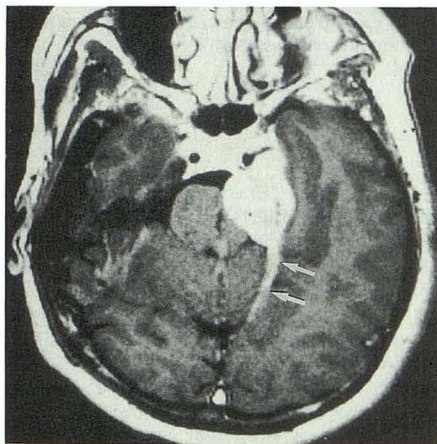
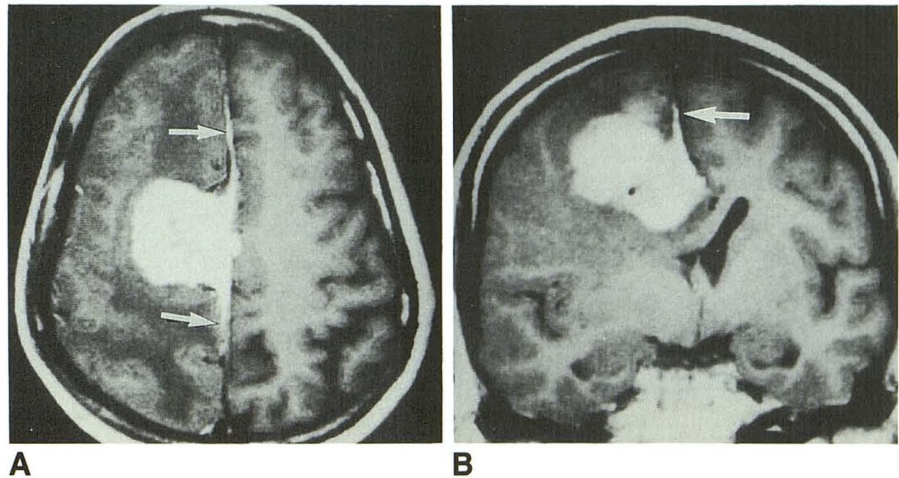
**B,** Same section after IV administration of gadopentetate dimeglumine shows tumor exhibiting hyperintensity due to shortening of T1 relaxation time. Linear enhancement along adjacent dura mater (flare sign) is demonstrated on both sides of tumor (arrows).



Fig. 2.—Case 6: 49-year-old woman with falx meningioma.

A, Axial SE 500/17 contrast MR image shows falx meningioma with linear enhancement along the falx (arrows). This tumor is associated with parenchymal edema, and presented as decreased signal of the right cerebral white matter.

B, Coronal SE 500/17 contrast MR image also shows tumor and flare sign along the falx (arrow).



A

B

Fig. 3.—Case 11: 53-year-old woman with tentorial meningioma.

A, Axial SE 500/17 contrast MR image shows enhanced mass at left cerebellopontine angle and commalike enhancement along left tentorium (arrows). Note that right tentorium does not exhibit definite enhancement.

B, Coronal SE 500/17 contrast MR image shows cerebellopontine angle tumor and spurlike enhancement extending to left middle fossa (upper arrow), internal auditory canal (lower arrow) and, probably, jugular foramen (arrowhead).

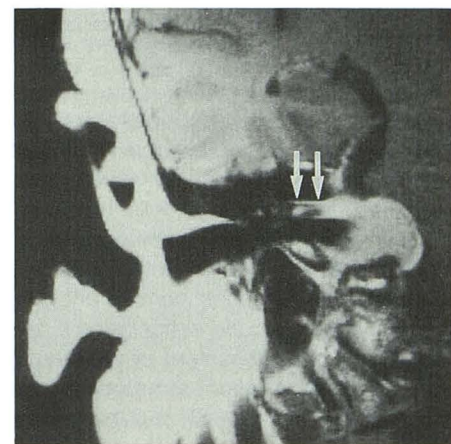


Fig. 4.—Case 17: 70-year-old woman with cerebellopontine angle meningioma. Coronal SE 600/22 contrast MR image using a surface coil shows right cerebellopontine angle tumor associated with enhancement along right internal auditory canal, adjacent dura, and jugular fossa. Note that enhancement within internal auditory canal is more prominent along the walls (arrows).

The precise mechanism for the difference in dural enhancement between MR and CT is poorly understood. However, it is obvious that the dural enhancement is weaker on MR than on CT in most individuals. Therefore, while subtle abnormal enhancement along the dura is obscured on CT by strong enhancement of normal dura, gadopentetate-dimeglumine-enhanced MR can visualize subtle abnormalities adjacent to the dura. In addition, convex dural abnormalities are especially obscured on CT, because of overlying high density of the calvarium.

We observed the flare sign of meningiomas with high frequency in 72% of our cases, a finding that has not been described before. Three specimens of the dura mater of the patients who exhibited the flare sign on enhanced MR images did not exhibit tumor invasion in the majority of the tissue that corresponded to regions of contrast enhance-

ment of the sign. Our observations strongly suggest that the sign could be observed without dural invasion of tumors. The reason why the sign appears without dural invasion is probably due to development of connective tissue (which is rich with vessels) adjacent to the meningioma attachment. Presumably, this is a reactive change caused by the existence of hypervascular meningiomas. Hypervascularity has also been suggested to be the pathogenesis of hyperostosis without bone invasion by meningiomas [13–15].

Thickening and enhancement of dura surrounding meningiomas have been reported. Wilms et al. [16] found tumor invasion at the dura in one case and Tokumaru et al. (paper presented at RSNA, Chicago, 1989) found "markedly increased collagen tissue and highly vascular and dilated vessels, but no obvious direct tumor invasion at the enhanced portion of the dura" in their four cases. Since only



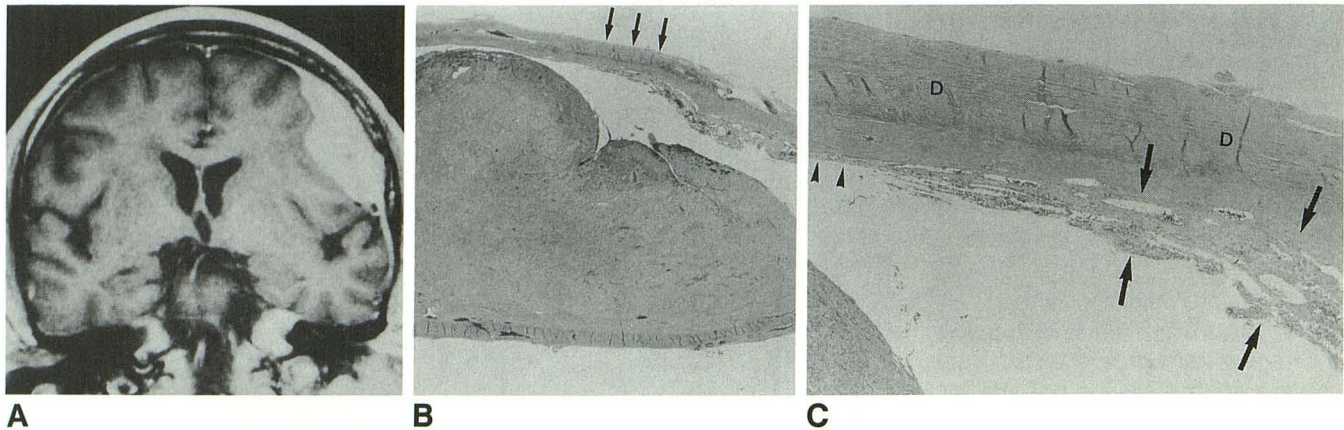


Fig. 5.—Case 3: 60-year-old man with convexity meningioma.

A, Coronal SE 500/17 MR image shows a right convexity tumor with a flare sign.

B, Pathologic specimen of this tumor with preservation of relationship between tumor and adjacent dura mater. (H and E at low power.) Arrows indicate portion that is magnified in C.

C, Poorly organized vascular connective tissue (between arrows) has developed along the dense, highly organized connective tissue of dura mater (D). The vascular tissue gradually tapers and diminishes in thickness. There are no tumor cells in this portion. (H and E at high power)

three cases were appropriately evaluated in our series, the relative probability of this sign being the result of hypervascularity rather than tumor invasion cannot be determined at this time.

One other clinically significant finding is enhancement along the dura within the internal auditory canals by meningiomas at the cerebellopontine angle (Figs. 3 and 4). This finding may mimic the enhancement of acoustic schwannomas. Lack of enlargement of the internal auditory canal on MR or CT and precontrast studies, which exhibit a normal nerve complex with CSF in the internal auditory canal, may be helpful in diagnosing meningioma. Also, high-resolution thin-slice MR imaging might exhibit enhancement that is limited only to the walls of the internal auditory canal. The flare sign might be helpful in this case as well, when meningiomas exhibit the sign at the other margins of the tumor, such as along the tentorium (Fig. 3).

Other possible disorders that might exhibit the sign are tumors originating from meninges (such as sarcomas, dural metastases, and extracerebral extension of aggressive gliomas) and nonneoplastic disorders that produce meningeal irritation, such as abscesses. They have been reported to exhibit external carotid supply occasionally. Clinically, the flare sign may be useful to differentiate dural-based tumors (such as meningiomas) from other tumors (such as neuromas).

In summary, we frequently observed linear enhancement (flare sign) along the dura continuous with or emanating from the dural margin of meningiomas. This flare sign was thought to be caused by hypervascularity of meningiomas and to be a common finding of meningiomas with gadopentetate-dimeglumine enhancement using high-resolution MR. The sign may not always indicate tumor invasion to the dura mater. Meningiomas adjacent to the cerebellopontine angle may exhibit this enhancement along the dura within the internal auditory canal, and this appearance should not be misinterpreted as enhancement of acoustic schwannomas.

#### REFERENCES

1. Felix R, Schoerner W, Laniado M, et al. Brain tumors: MR imaging with gadolinium-DTPA. *Radiology* 1985;156:681-688
2. Berry I, Brant-Zawadzki M, Osaki L, Brasch R, Murovic J, Newton TH. Gd-DTPA in clinical MR of the brain: 2. Extraaxial lesions and normal structures. *AJNR* 1986;7:789-793
3. Breger RK, Papke RA, Pojunas KW, Haughton VM, Williams AL, Daniels DL. Benign extraaxial tumors: contrast enhancement with Gd-DTPA. *Radiology* 1987;163:427-429
4. Schroth G, Grodd W, Guhl L, Grauer M, Klose U, Niendorf HP. Magnetic resonance imaging in small lesions of the central nervous system: improvement by gadolinium-DTPA. *Acta Radiol* 1987;28:667-672
5. Haughton VM, Rimm AA, Czervonke LF, et al. Sensitivity of Gd-DTPA-enhanced MR of benign extraaxial tumors. *Radiology* 1988;166:829-833
6. Bydder GM, Kingsley DPE, Brown J, Niendorf HP, Young IR. MR imaging of meningiomas including studies with and without gadolinium-DTPA. *J Comput Assist Tomogr* 1985;9:690-697
7. Kilgore DP, Breger RK, Daniels DL, Pojunas KW, Williams AL, Haughton VM. Cranial tissues: normal MR appearance after intravenous injection of Gd-DTPA. *Radiology* 1986;160:757-761
8. Zimmerman RD, Fleming CA, Saint-Louis LA, Lee BCP, Manning JJ, Deck MDF. Magnetic resonance imaging of meningiomas. *AJNR* 1985;6:149-157
9. Spagnoli MV, Goldberg HI, Grossman RI, et al. Intracranial meningiomas: high field MR imaging. *Radiology* 1986;161:369-375
10. Yeakley JW, Kulkarni MV, McArdle CB, Harr FL, Tang RA. High-resolution MR imaging of juxtaseptal meningiomas with CT and angiographic correlation. *AJNR* 1988;9:279-285
11. Weinman HJ, Brasch RC, Press WR, Wesbey GE. Characteristics of gadolinium-DTPA complex: a potential NMR contrast agent. *AJR* 1984;142:619-624
12. Brasch RC, Weinmann HJ, Wesbey GE. Contrast-enhanced NMR imaging: animal studies using gadolinium-DTPA complex. *AJR* 1984;142:625-630
13. Russell DS, Rubinstein LJ. Pathology of tumors of the nervous system, 4th ed. Baltimore: Williams & Wilkins, 1977
14. Rowbotham GF. The hyperostosis in relation with the meningioma. *Br J Surg* 1939;26:593-622
15. Kim KS, Rogers LF, Lee C. The dural lucent line: characteristic sign of hyperostosing meningioma en plaque. *AJR* 1983;141:1217-1221
16. Wilms G, Lammens M, Marchal G, et al. Thickening of dura surrounding meningiomas: MR features. *J Comput Assist Tomogr* 1989;13:763-768