

# Cerebral MR in Ophthalmoplegia Plus

C. Leutner, G. Layer, S. Zierz, L. Solymosi, W. Dewes, and M. Reiser

**PURPOSE:** To evaluate MR patterns in ophthalmoplegia plus and correlate them with clinical symptoms. **METHODS:** MR was performed on a 1.5-T whole-body scanner with T2-weighted gradient-echo and spin-echo images. The retrospective analysis included 19 patients with clinically established diagnoses of ophthalmoplegia plus. **RESULTS:** Two types of cerebral MR abnormalities were found in ophthalmoplegia plus: brain atrophy and hyperintensities restricted to the white matter and basal ganglia, which appeared as either focal or diffuse areas of high signal intensity and were of strictly supratentorial location. No specific distribution was found. These findings differ markedly from infarction-like lesions found in mitochondrial myopathy, encephalopathy, lactic acidosis, and strokelike episodes. **CONCLUSIONS:** MR is sensitive for the detection of central nervous system involvement in ophthalmoplegia plus, but findings are nonspecific. However, cerebral MR in ophthalmoplegia plus is different from other mitochondrial encephalomyopathies and underlines the clinical differentiation of mitochondrial encephalomyopathies.

**Index terms:** Nervous system, diseases; Nervous system, magnetic resonance; Muscles, diseases; Paralysis; Brain, magnetic resonance; Degenerative brain disease

*AJNR Am J Neuroradiol* 15:681-687, Apr 1994

Mitochondrial encephalomyopathies are genetically defined multisystem disorders with a large variety of clinical symptoms. These diseases may affect the peripheral and central nervous system, skeletal muscles, heart, retina, and other organs. The typical morphologic hallmarks in the muscle biopsy are "ragged red fibers," which are characterized by accumulation of abnormal mitochondria. Elevated levels of lactate pyruvate in the venous blood under mild physical exercise indicate a dysfunction of mitochondrial metabolism as well (1-4). Various biochemical, histochemical, and genetic abnormalities can be found. However, these biochemical or genetic abnormalities cannot be identified in all cases (5-7).

Among the mitochondrial encephalomyopathies, ophthalmoplegia plus and its variant, Kearns-Sayre syndrome, are defined by clinical symptoms (2). Ophthalmoplegia plus is charac-

terized by various symptoms such as exercise-induced or permanent pareses and myalgia, chronic progressive external ophthalmoplegia, cardiac and retinal manifestations, peripheral neuropathy, and hypacusis (2, 4).

Kearns-Sayre syndrome, in contrast, is defined by the typical triad of chronic progressive external ophthalmoplegia, pigmentary retinopathy, and onset before age 15 years, with one of the following additional symptoms: elevated cerebrospinal fluid protein, heart block, and cerebellar symptoms (6).

Central nervous disorders associated with ophthalmoplegia plus include pyramidal tract and extrapyramidal symptoms, cerebellar syndromes, and dementia (4).

In this study, magnetic resonance (MR) findings of the brain in patients with ophthalmoplegia plus were evaluated and the correlation of MR with clinical symptoms was examined. Results were compared with reported findings in mitochondrial myopathy, encephalopathy, lactic acidosis, and strokelike episodes (8).

## Patients and Methods

Nineteen patients (12 women, 7 men) with a mean age of 40 years (range, 18-61) were included in this retrospec-

---

Received December 29, 1992; accepted for publication May 11, 1993.  
From the Departments of Radiology (C.L., G.L., L.S., W.D., M.R.) and Neurology (S.Z.), University of Bonn, Bonn, Germany.

Address correspondence to Claudia Leutner, MD, Department of Radiology, University of Bonn, Sigmund-Freud-Strasse 25, D-5300 Bonn, Germany.

tive study. Although MR was not performed routinely, almost all patients with ophthalmoplegia plus treated in our center of neurology underwent MR. However, patients with severe cardiac symptoms requiring a pacemaker (about one third of all patients) had to be excluded from the study.

In all patients, diagnosis of ophthalmoplegia plus was established by clinical and laboratory findings and muscle biopsy. At muscle biopsy all patients presented with ragged red fibers, 17 with focal cytochrome *c* oxidase decrease, which is a frequent finding in ophthalmoplegia plus (2). Most of them had elevated lactate pyruvate levels in venous blood under standardized exercise (bicycle ergometer,  $n = 14$ ).

MR examinations were performed on a 1.5-T whole-body scanner (Gyrosan S 15, Philips Medical Systems, The Netherlands) using a standard head coil. The MR examinations included axial and coronal proton-density and T2-weighted spin-echo images with imaging parameters 1800/30, 100/2 (repetition time/echo time/number of excitations; section thickness, 8 mm) and T2-weighted gradient-echo images (fast field echo; 800/34; flip angle, 15°; section thickness, 4 mm) with an angulation parallel to the posterior border of the brain stem.

## Results

In Table 1 clinical symptoms are presented. Chronic progressive external ophthalmoplegia, as the principal sign of ophthalmoplegia plus, was found in all patients. Most of them showed skeletal muscle manifestations such as exercise-induced or permanent pareses and myalgia ( $n = 16$ ), and retinal symptoms such as pigmentary

retinopathy ( $n = 10$ ). Cardiac conduction block (not requiring a pacemaker) was diagnosed in six cases.

Six patients had additional manifestations such as peripheral neuropathy ( $n = 2$ ), hypacusis ( $n = 4$ ), or endocrinologic disorders (diabetes,  $n = 1$ ).

Clinical signs of central nervous system (CNS) involvement were observed in five patients (Table 1). Besides dementia and pyramidal tract abnormalities, the most frequent disorder was a cerebellar syndrome, characterized by intention tremor, dysdiadochokinesia, and ataxia ( $n = 4$ , Table 2).

Cerebral MR scans showed abnormalities in 11 of 19 cases. Pathologic findings could be subdivided into two types: generalized brain atrophy, and hyperintensities of the white matter and basal ganglia, which were seen most clearly on T2-weighted gradient-echo images (Table 2).

Brain atrophy with symmetrical widening of the subarachnoid space was observed in four patients, all of them under 50 years of age (Fig 1). Clinical findings of CNS involvement in these patients included dementia in one case and a cerebellar syndrome plus dementia in another case. Two patients had no clinical sign of CNS involvement (Table 2).

Hyperintensities in the white matter and basal ganglia were found in eight cases. They were restricted to the supratentorial area; no changes were seen in the brain stem, which contains the

TABLE 1: Clinical manifestations of ophthalmoplegia plus

Case	Age (y), Sex	RRF	CPEO	Cardio- pathy	Retino- pathy	Skeletal Paresis	Myalgia	CNS Symptoms	Additional Symptoms
1	22, M	+	+	+	+	+	-		Hypacusis
2	49, M	+	+	+	+	+	-	+	Hypacusis, polyneuropathy
3	30, M	+	+	-	-	-	-	-	
4	35, F	+	+	-	+	+	-	-	
5	56, M	+	+	-	+	+	-	-	
6	48, M	+	+	-	+	+	-	+	Hypacusis
7	33, M	+	+	-	+	+	-	-	
8	30, F	+	+	-	+	+	-	-	Hypacusis
9	37, F	+	+	+	-	+	-	+	Diabetes
10	40, F	+	+	+	+	-	-	-	
11	53, F	+	+	-	+	+	-	+	
12	42, F	+	+	-	+	+	-	-	
13	51, F	+	+	-	-	+	-	-	Polyneuropathy
14	48, M	+	+	-	-	+	-	-	
15	24, F	+	+	-	-	+	+	-	
16	29, F	...	+	+	-	-	-	+	
17	61, F	+	+	+	-	+	+	-	
18	18, F	+	+	-	-	+	-	-	
19	60, F	+	+	-	-	+	-	-	

Note.—+, - indicates positive or negative clinical finding; RRF, ragged red fibers; and CPEO, chronic progressive external ophthalmoplegia.

TABLE 2: MR findings and CNS involvement in patients with ophthalmoplegia plus

Case	CNS Involvement			Findings/location
	Dementia	Pyramidal tract symptoms	Cerebellar syndrome	
2	+			Diffuse area of high signal intensity/bilateral parietooccipital white matter
6	+		+	Generalized atrophy
9			+	Symmetrical spotlike high signal intensities/bilateral internal capsule and globus pallidus; generalized atrophy
11		Bilateral positive Babinski	+	Spotlike high signal intensities/bilateral pyramidal tract
16			+	Diffuse area of high signal intensity/bilateral frontoparietal white matter
1				Diffuse area of high signal intensity/bilateral frontal white matter; symmetrical spotlike high signal intensities/bilateral internal capsule and globus pallidus
10				Generalized atrophy
12				Multiple spotlike high signal intensities/bilateral frontal white matter
14				Generalized atrophy
17				Spotlike high signal intensities/bilateral cerebral white matter
19				Spotlike high signal intensities/bilateral cerebral white matter

Note: + indicates positive clinical finding.

nuclei pathways responsible for intraocular movement. No cerebellar abnormalities were found apart from signs of brain atrophy.

Hyperintensities showed heterogeneous character, but two subgroups could be differentiated: focal hyperintensities (Figs 1 and 2) and diffuse areas of high signal intensity, which extended up to the cortical gray matter and involved the arcuate fibers (Figs 3 and 4). The cortical gray matter appeared to be normal in all patients. Diffuse hyperintense signals were predominantly localized in the parietooccipital region (two of three cases) and showed a symmetrical distribution in all cases (Figs 3 and 4). One patient had both diffuse and localized hyperintensities (Table 2).

CNS symptoms were detected in four patients with hyperintense lesions: two of these had a cerebellar syndrome, one had dementia, and one showed pyramidal tract abnormalities and a cerebellar syndrome. Four of eight patients with cerebral hyperintensities had no clinical sign of CNS involvement (Table 2).

There were abnormal MR findings in both patients with and those without clinical CNS disorders; distribution of MR findings showed no peculiar pattern between both patient groups. On the other hand, all five patients with clinical signs of CNS involvement had abnormal MR findings.

## Discussion

Because of the variation in clinical symptoms affecting almost all organs, classification of mitochondrial encephalomyopathies is difficult. Apart from ophthalmoplegia plus and its clinical variant, Kearns-Sayre syndrome, two more syndromes can be differentiated (Table 3): myoclonus epilepsy with ragged red fibers (MERFF) and mitochondrial myopathy, encephalopathy, lactic acidosis, and strokelike episodes (MELAS) (6, 8–10).

Although CNS involvement is not one of the major symptoms in ophthalmoplegia plus, as it is in MELAS and MERFF, it is a well-known feature. Characteristic radiologic features with CNS involvement would be of great diagnostic and prognostic value in ophthalmoplegia plus.

This retrospective study of 19 patients with ophthalmoplegia plus showed MR abnormalities in no more than half of the cases. Abnormal findings were present in all patients with clinical signs of CNS involvement. In some patients with abnormal MR, however, no clinical sign of CNS involvement was found at the time of MR or during a follow-up period of 2 to 4 years; to date, no correlation of MR abnormalities with prognosis of disease has been found. However, considering the age distribution of our patients with a mean

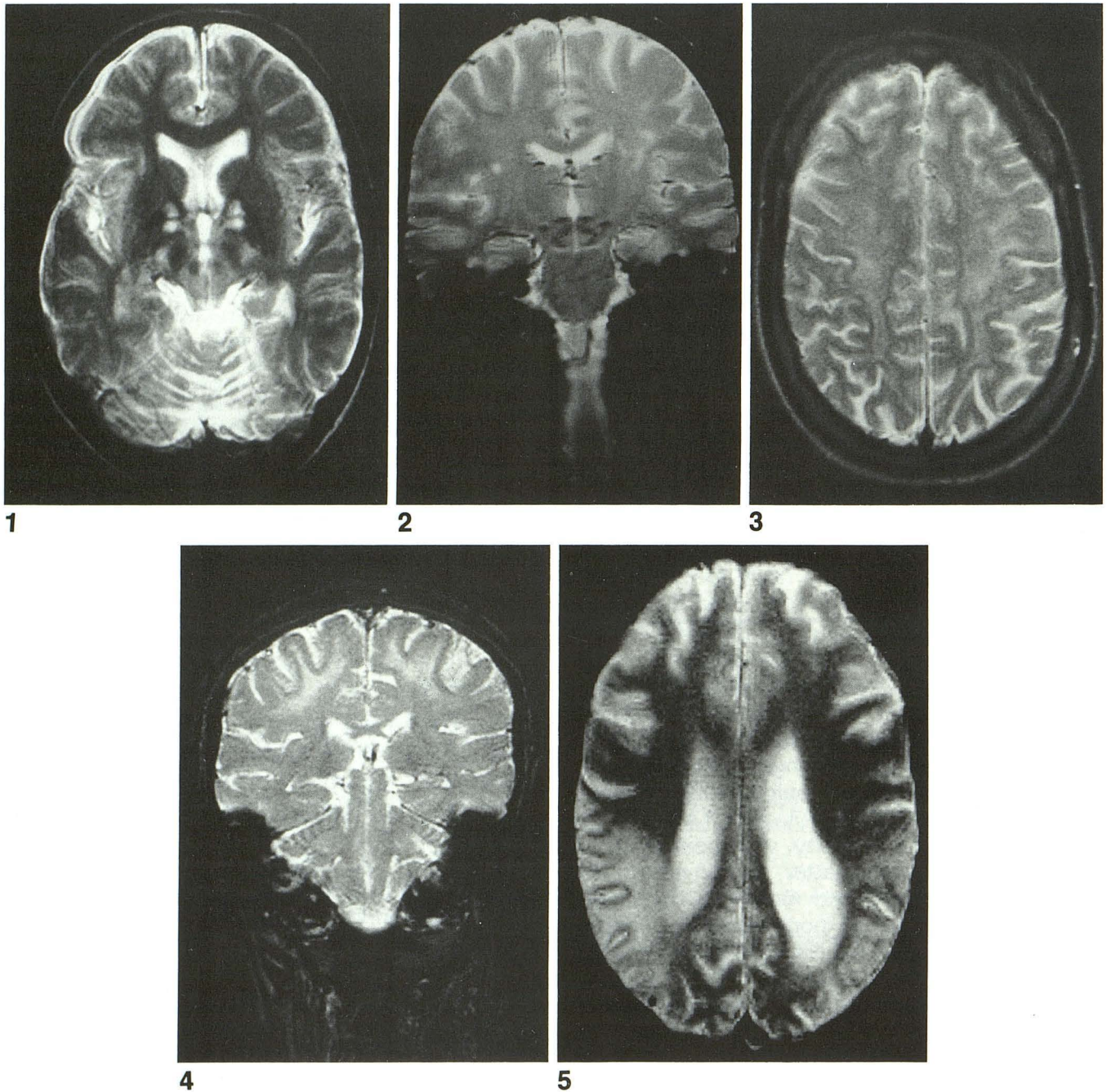


Fig. 1. This 37-year-old woman (case 9) had severe cerebellar symptoms. The axial T2-weighted gradient-echo image (fast field echo 800/34/2, 15° flip angle) shows symmetrical lesions in the posterior branch of the internal capsule and widening of the subarachnoid space.

Fig. 2. This 53-year-old woman (case 11) had bilateral positive Babinski sign. The coronal T2-weighted gradient-echo image (fast field echo, 800/34, 15° flip angle) demonstrates bilateral, spotlike hyperintensities in the white matter, just above the internal capsule and localized to the pyramidal tract. The clinical symptoms of pyramidal tract abnormalities correspond to the location of lesions on MR.

Fig. 3. This 29-year-old woman (case 16) had cerebellar syndrome. The axial T2-weighted fast-field-echo image with imaging parameters (800/34; flip angle, 15°) reveals diffuse areas of hyperintensity bilaterally in the frontoparietal white matter. Arcuate fibers are involved, but cortical gray matter appears normal.

Fig. 4. MR scan of a 49-year-old man (case 2) with dementia. Coronal T2-weighted gradient-echo image (fast field echo, 800/34, 15° flip angle) showing bilateral hyperintensities in the parietooccipital white matter. The lesions have the same appearance as in Fig 3: symmetrical, diffuse areas involving the arcuate fibers but sparing the cortical gray matter.

Fig. 5. This 38-year-old man with MELAS had a cerebellar syndrome, dementia, and left-sided weakness. Axial T2-weighted gradient-echo scan (fast field echo, 800/34, 15° flip angle) demonstrates, apart from generalized brain atrophy, a territorial infarctionlike lesion localized to the parietotemporooccipital area on the right side. Unlike lesions in ophthalmoplegia plus, cortical gray matter is included.

TABLE 3: Mitochondrial encephalomyopathies—major syndromes (4, 5)

Kearns-Sayre Syndrome	Ophthalmoplegia plus	MERRF	MELAS
Chronic progressive external ophthalmoplegia	Chronic progressive external ophthalmoplegia	Myoclonus	Episodic vomiting
Pigmentary retinopathy	Various symptoms: pigmentary retinopathy	Convulsive fits	Cortical amaurosis
Heart block	Heart block, skeletal muscle symptoms (eg, pareses, myalgia), peripheral neuropathy	Muscle weakness Ataxia	Hemiparesis Hemianopsia

Note: Common symptoms are muscle weakness, dementia, hypacusis, and short stature. MERRF indicates myoclonus epilepsy with ragged red fibers; MELAS, mitochondrial myopathy, encephalopathy, lactic acidosis, and stroke-like episodes.

age of 45 years, the unspecific MR findings in these patients are definitely beyond the normal range.

The results of this study may be restricted by the fact that patients with a pacemaker because of severe heart block could not be examined; as a result, a systematic error or bias in this study cannot be ruled out completely.

MR revealed two main findings: brain atrophy, which has previously been found in computed tomography studies (11–13), and hyperintense signals in the white matter and basal ganglia, either focal or diffuse. Diffuse hyperintensities included subcortical white matter and arcuate fibers, but never gray matter of the cortex (Figs 3 and 4). Similar findings have been described previously in case reports on other patients with ophthalmoplegia plus or Kearns-Sayre syndrome (14, 15).

Abnormal MR findings disclosed no peculiar pattern of distribution and occurred in patients with and without CNS involvement (Table 3). Differential diagnosis of hyperintensities in the brain on T2-weighted MR images includes a broad spectrum of disorders, such as vascular, infectious, immune, and metabolic disorders and multiple sclerosis (13). However, none of our patients showed evidence of one of the above-mentioned disorders. Eighty percent of the patients of this study were less than 50 years of age; all underwent thorough clinical examination during their hospitalization.

In this study, MR did not demonstrate any cortical hyperintensities in patients with ophthalmoplegia plus. This is different from findings in MELAS syndrome, which is clinically characterized by stroke-like episodes (8). Matthews et al (16) recently reported three patients with MELAS who showed "multifocal areas of hyperintense signal confined to the cortex of cerebrum and cerebellum, and immediately adjacent white matter" and suggested these findings to be specific for MELAS (16). Other authors' and our own observations confirmed these findings (Fig 5) (11,

17, 18). Lesions affecting the gray matter and adjacent areas of the subcortical white matter, resembling those of ischemic infarcts, were detected in MELAS and they correlated with stroke-like episodes in these patients (17, 18).

This clear-cut correlation of MR findings and neurologic deficits (11, 16, 17, 19) as found in MELAS, could be demonstrated in only two patients with ophthalmoplegia plus in our study.

In a woman with a bilateral positive Babinski sign, MR revealed spotlike hyperintensities in both pyramidal tracts just above the internal capsule (Fig 2).

In another woman with severe cerebellar symptoms, a prominent cerebellar atrophy as part of generalized brain atrophy was detected; two symmetrical lesions in the basal ganglia and internal capsules in the same patient were not accompanied by clinical symptoms (Fig 1). Symmetrical lesions localized in the basal ganglia may be a typical finding in another disease associated with mitochondrial dysfunction: Leigh disease, a subacute necrotizing encephalopathy, characterized by early-onset, severe neurologic deficits and frequently death (6, 13).

Despite the high frequency of cerebellar symptoms in patients with ophthalmoplegia plus, no abnormalities in the cerebellum apart from cerebellar atrophy were found on MR (Table 2). Several authors describe a predominance of lesions within the parietooccipital area in MELAS (16–18). In two of three cases of ophthalmoplegia plus, diffuse areas of hyperintensity were found in the same location, but they did not correspond to any major vascular territory. This lack of correlation with the major vascular territories was described for MELAS, too (8, 16, 20).

However, there are findings indicating a vascular pathogenesis of lesions in MELAS. Microscopic examination of cerebral blood vessels revealed abnormalities of the mitochondria in the smooth muscle and endothelial cells in MELAS, most prominent in small pial arteries and arterioles; larger vessels were less involved and no

vascular occlusion could be demonstrated (21). This suggests that lesions in MELAS are not caused by macroangiopathy, but rather by a mitochondrial microangiopathy, which corresponds well with the above-mentioned lack of correlation of lesions in MELAS with major vascular territories.

Results of single-photon emission computed tomography in patients with MELAS, showing regional hypoperfusion, also confirm a vascular pathogenesis (22). Enhancement of lesions in postcontrast MR and computed tomography scans, indicating a breakdown of blood-brain barrier, was described by several authors (12, 18, 19). Unfortunately, the retrospective character of this study made it impossible to examine lesions in patients with ophthalmoplegia plus in postcontrast scans.

Various defects of the respiratory chain are found in muscle cells of patients with mitochondrial encephalomyopathies, such as decreased activity of complex I and IV of the respiratory chain or focal decrease of cytochrome *c* oxidase (2). However, genetic abnormalities of mitochondrial DNA differ: deletions occur frequently in ophthalmoplegia plus; MELAS and MERFF are associated with point mutations (5, 26).

Histologic examination of the brain shows distinct differences between MELAS and ophthalmoplegia plus. MELAS is characterized by foci of necrosis including the cortex (8, 20, 21), which may be the correlate to the infarctionlike lesions seen in MR.

In ophthalmoplegia plus, the most prominent finding of cerebral histologic examination is a spongy degeneration restricted to the white matter (14, 23–25). This corresponds well with the predominant changes of the white matter found in this study. The underlying mechanism may be the abnormal energy production of the nerve cells and oligodendrocytes, resulting in nerve degeneration, astrocytosis, and demyelination (14, 23, 24).

In ophthalmoplegia plus, clinical symptoms of CNS involvement and abnormal MR findings seem to be less frequent and severe than in MELAS syndrome. In this study, diagnosis of ophthalmoplegia plus was established by clinical findings, results of muscle biopsy, and biochemical examinations. Because MR showed nonspecific lesions in patients with and without CNS involvement, we believe that the potentials of MR concerning diagnosis are rather limited.

However, MR has proved sensitive to CNS involvement in patients with ophthalmoplegia

plus. Considering the small number of patients and the short time of clinical follow-up, the prognostic value of MR cannot be fully evaluated at this point of the study; therefore, we believe that MR could be helpful for assessment of prognosis in patients already showing or developing CNS symptoms in the course of disorder. Further examination of our patients' clinical development and additional MR studies will be needed.

The differentiation of mitochondrial encephalomyopathies in three major syndromes is still the subject of controversial discussion (26). However, in this study, MR findings in ophthalmoplegia plus were clearly different from those reported in patients with MELAS syndrome. This finding underlines the differentiation of MELAS and ophthalmoplegia plus as distinct clinical syndromes.

## References

- Petty RKH, Harding AE, Morgan-Hughes JA. The clinical features of mitochondrial myopathy. *Brain* 1986;109:915–938
- Zierz S, von Wesebe O, Gerbitz K, Jerusalem F. Ophthalmoplegia-plus: biochemical defects and deletions of the mitochondrial DNA. *Nervenarzt* 1990;61:332–339
- Karpati G. The Kearns-Sayre-Shy syndrome. In: Vinken PJ, Bruyn GW, eds. *Handbook of clinical neurology*. Elsevier, 1979:221–232
- Bastiaansen LAK, Joosten EMG, De Rooij JAM, et al. Ophthalmoplegia-plus, a real nosological entity. *Acta Neurol Scand* 1978;58:9–34
- Zierz S, Jerusalem F. Mitochondrial myopathy and encephalomyopathy. *Nervenarzt* 1989;60:394–400
- DiMauro S, Bonilla E, Zeviano M, Nakagawa M, DeVivo DC. Mitochondrial myopathy. *Ann Neurol* 1985;17:521–538
- Zeviano M, Antozzi C. Defects of mitochondrial DNA. *Brain Pathol* 1992;2:121–132
- Pavakis SG, Phillips PC, DiMauro S, DeVivo DC, Rowland LP. Mitochondrial myopathy, encephalopathy, lactic acidosis, and stroke-like episodes: a distinctive clinical syndrome. *Ann Neurol* 1984;16:481–488
- Fukuhara N, Tokiguchi S, Shirakawa K, Tsubaki T. Myoclonus epilepsy associated with ragged red fibers (mitochondrial abnormalities): disease entity or syndrome. *J Neurol Sci* 1980;47:117–133
- Fukuhara N. Myoclonus epilepsy and mitochondrial myopathy. In: Gerri C, Scarlato G, eds. *Mitochondrial pathology in muscle diseases*. Padua: Piccini Editore, 1983:87–111
- Allard JC, Tilak S, Carter AP. CT and MR of MELAS syndrome. *AJNR Am J Neuroradiol* 1988;9:1234–1238
- Van Hellenberg Hubar JLM, Gabreels FJM, Ruitenbeek W, et al. MELAS syndrome: report of two patients, and comparison with data of 24 patients from the literature. *Neuropediatrics* 1991;22:10–14
- Valk J, Van Der Knaap MS. *Magnetic resonance of myelin, myelination, and myelin disorders*. Berlin: Springer Verlag, 1989:130–136
- Sandhu FS, Dillon WP. MR demonstration of leukoencephalopathy associated with mitochondrial encephalomyopathy: case report. *AJNR Am J Neuroradiol* 1991;12:375–379
- Demange P, Pham Gia H, Kalifa G, Sellier N. MR of Kearns-Sayre syndrome. *AJNR Am J Neuroradiol* 1989;10:91
- Matthews PM, Tampieri D, Berkovic SF, et al. Magnetic resonance imaging shows specific abnormalities in the MELAS syndrome. *Neurology* 1991;41:1043–1047

17. Rosen L, Phillips S, Enzmann D. Magnetic resonance imaging in MELAS syndrome. *Neuroradiology* 1990;32:168-171
18. Taverni N, DalPozzo G, Arnetoli G, Zappoli R. Diagnosis and follow-up of mitochondrial encephalomyopathy: CT and MR studies. *J Comput Assist Tomogr* 1988;12:696-679
19. Satoh M, Ishikawa N, Yoshizawa T, Takeda T, Akisada M. N-isopropyl-p-(<sup>123</sup>I) lodoamphetamine SPECT in MELAS syndrome: comparison with CT and MR imaging. *J Comput Assist Tomogr* 1991;15:77-82
20. Mukoyama M, Kazui H, Sunohara N, Yoshida M, Nonaka I, Satozoshi E. Mitochondrial myopathy, encephalopathy, lactic acidosis, and stroke-like episodes with acanthocytosis: a clinicopathological study of a unique case. *J Neurol* 1986;233:228-232
21. Ohama E, Ohara S, Ikuta F, Tanaka K, Nishizawa M, Myatake T. Mitochondrial angiopathy in cerebral blood vessels of mitochondrial encephalomyopathy. *Acta Neuropathol (Berl)* 1987;74:226-233
22. Grünwald F, Zierz S, Broich K, Schumacher S, Bockisch A, Biersack H. HMPAO-SPECT imaging resembling Alzheimer-type dementia in mitochondrial encephalomyopathy with lactic acidosis and stroke-like episodes (MELAS). *J Nucl Med* 1990;31:1740-1742
23. Daroff RB, Solitare GB, Pincus JH, Glaser GH. Spongiform encephalopathy with chronic progressive external ophthalmoplegia. *Neurology* 1966;16:161-169
24. Oldfors A, Fyhr I-M, Holme E, Larsson NG, Tulinius M. Neuropathology in Kearns-Sayre syndrome. *Acta Neuropathol* 1990;80:541-546
25. Seigel RS, Seeger JF, Gabrielsen TO, Allen RJ. Computed tomography in oculocraniosomatic disease (Kearns-Sayre syndrome). *Radiology* 1979;130:159-164
26. Rowland LP, Blake MD, Hirano M, et al. Clinical syndromes associated with ragged red fibers. *Rev Neurol (Paris)* 1991;147:467-473

### Imaging Quiz: Request for Original Submissions

This issue marks the appearance of a new feature in the *AJNR*, the Imaging Quiz. The quiz can be found on page 658 and the diagnosis on page 774. We welcome other original submissions for this feature. This feature must fit on no more than two journal pages: a quiz page and a diagnosis page. Therefore, the approximate length of submissions should be two to three double-spaced pages of text, including references, and up to 10 figures. The submissions will undergo peer review. We look forward to receiving your contributions for this feature.