

---

# Neonatal Hypoglycemia: CT and MR Findings

Jon A. Spar, Jeffrey David Lewine, and William W. Orrison, Jr

**Summary:** A case of neonatal hypoglycemia with extensive occipital cortical loss is presented. Imaging studies revealed a predominance of brain parenchymal loss in the occipital lobes bilaterally with nearly complete absence of cortex in the posterior parietal and occipital regions and generalized thinning of the cortex throughout the brain.

**Index terms:** Brain, computed tomography; Brain, magnetic resonance; Brain, metabolism; Infants, newborn

Glucose and oxygen are both considered essential for normal brain function, and it is generally well accepted that profound hypoglycemia results in significant brain damage (1). Multiple studies have documented acute and long-term abnormalities in infants and children after hypoglycemic episodes. We report here the imaging findings in a well-documented case of isolated hypoglycemia.

## Case Report

A term infant was delivered to a nondiabetic primigravida. The pregnancy was complicated by preeclampsia requiring the mother's hospitalization for close monitoring and control of hypertension 2½ days before delivery. The infant's Apgar score was 8/9 at 1 and 5 minutes. The infant and mother were discharged when the child was approximately 36 hours old. The mother reported that the child was initially feeding well, but she noted increasing irritability and poor feeding approximately 48 hours after delivery. The child had a seizure at 58 hours of age. A glucose level of 3 mg/dL was documented 70 hours after delivery. Pedialyte (Abbott, Columbus, Ohio) was administered, and the infant was admitted immediately to a local hospital. A repeat serum glucose test at 72 hours of age showed a level of 3 mg/dL, despite the earlier administration of Pedialyte. Total bilirubin was 14 mg/dL, and the infant was treated with phototherapy. Antibiotics were started for presumed sepsis; however, subsequent blood cultures proved negative. Intravenous 10% dextrose solution was started immediately at a rate of 10 mL/h, and blood glucose levels had increased to 32 mg/dL by 74 hours after delivery. At 76 hours of age, the child's serum glucose level was 48 mg/dL, and at 85 hours after delivery

it had risen to 54 mg/dL. The child's seizure activity increased despite the improved serum glucose levels, and he exhibited progressive lethargy and poor feeding. Serum glucose at 107 hours of age was normal at 133 mg/dL, ending at least 15 hours of well-documented severe hypoglycemia.

Computed tomographic and magnetic resonance images (Fig 1) demonstrated progressive evidence of parenchymal loss and occipital involvement.

## Discussion

Our review of the English literature revealed 15 cases of brain findings related to hypoglycemia (1-5). Of these 15 cases, 3 of the hypoglycemic episodes occurred during the neonatal period (1). In those cases and ours, there was a generalized neuronal loss grossly identified as thinning of the cerebral cortex. These findings were most severe in the occipital lobes in all 4 cases, and changes were noted to be the least marked in the temporal lobes. The basal ganglia also were found to be involved to a lesser extent.

The pathologic changes of hypoglycemia in the adult demonstrate a different pattern of distribution than those seen in the neonate. Diffuse involvement of the cortex, cerebellum, and basal ganglia, often no or minimal involvement of the occipital cortex, and increased involvement of the temporal lobe are the pathologic findings (2, 3). In nonhuman primate experiments, neuronal injury has been noted to involve especially the parietooccipital region (6).

Acute manifestations of hypoglycemia that may precede abnormal neurologic development include jitteriness, seizures, and vomiting. More delayed neurologic sequelae may include seizures, mental retardation, spasticity, and microcephaly. In 1965, Haworth and McRae reported patients examined within 2 years after episodes of neonatal hypoglycemia. Two members of the symptomatic group demonstrated visual disturbances (7).

---

Received June 4, 1993; accepted after revision February 21, 1994.

From the Departments of Radiology (J.A.S., J.D.L. W.W.O.) and Neurology (W.W.O.), University of New Mexico School of Medicine, Albuquerque; and Department of Radiology, Veterans Affairs Medical Center, Albuquerque (J.A.S., J.D.L., W.W.O.).

Address reprint requests to Jon A. Spar, MD, Department of Radiology, University of New Mexico Hospital, Albuquerque, NM 87131-5336.

AJNR 15:1477-1478, Sep 1994 0195-6108/94/1508-1477 © American Society of Neuroradiology

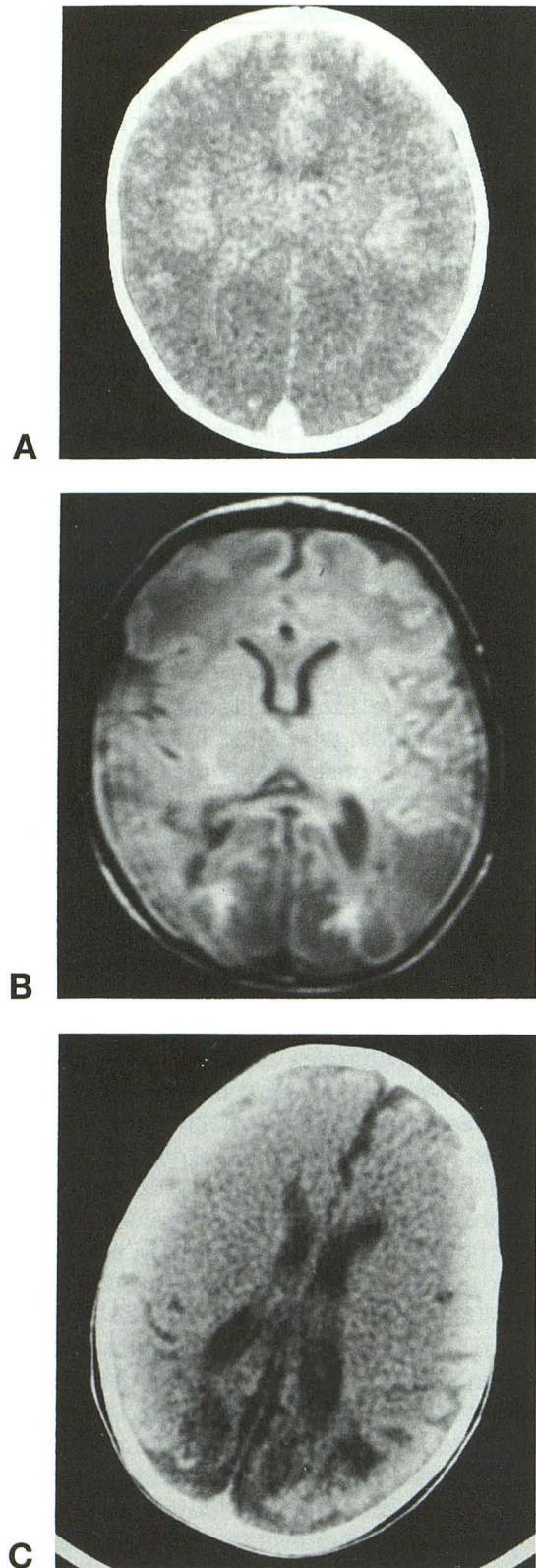


Fig 1. A, Computed tomography at 6 days of age demonstrates generalized edema.

B, Proton-density axial magnetic resonance image (2500/30/2 [repetition time/echo time/excitations]) at 19 days of age shows diffuse parenchymal loss, most severe in the occipital regions.

C, Computed tomography at 78 days of age shows parenchymal loss in the occipital regions.

The reasons the occipital cortex is particularly sensitive to hypoglycemia are not fully clear, especially considering the fact that the glucose demand of neonatal visual areas as assessed with positron emission tomography is relatively low (8). However, total glucose demand probably reflects both the actual maturation process of the cortex and the extent to which a region is functionally active. At birth, the visual system is not very active, because it is undergoing considerable maturation, with geniculostriate fibers still migrating through the cortical layers (9). It is hypothesized that, even though the overall level of metabolism of this area is low, migrating visual fibers are exceptionally sensitive to changes in glucose availability (10). Lack of glucose causes disruption of the normal time course of visual development, and cortical neurons deprived of geniculostriate fibers and their associated tropic factors fail to mature and thus die (11).

Imaging studies of a new case presented here demonstrate neonatal hypoglycemia findings of significant parenchymal loss most prominent in the occipital region. The findings presented seem to be relatively specific for neonatal hypoglycemia and correlate well with previously published pathologic findings.

## References

1. Anderson JM, Milner RDG, Strich S. Effects of neonatal hypoglycemia on the nervous system: a pathologic study. *J Neurol Neurosurg Psychiatry* 1967;30:295-310
2. Baker AB. Cerebral lesions in hypoglycemia, II: some possibilities of irrevocable damage from insulin shock. *Arch Pathol* 1938;26:765-776
3. Lawrence RD, Meyer A, Nevin S. The pathological changes in the brain in fatal hypoglycaemia. *Q J Med* 1942;11:181-201
4. Courville CB. Late cerebral changes incident to severe hypoglycemia (insulin shock). *AMA Arch Neurol Psychiatry* 1957;78:1-14
5. Kalimo H, Olsson Y. Effects of severe hypoglycemia on the human brain. *Acta Neurol Scand* 1980;62:345-356
6. Meldrum BS, Horton RW, Brierley JB. Insulin-induced hypoglycemia in the primate: relationship between physiological changes and neuropathology. In: Brierley JB, Meldrum BS, eds. *Brain Hypoxia*. Lavenham, England: The Lavenham Press, 1971:207-224
7. Haworth JC, McRae KN. The neurological and developmental effects of neonatal hypoglycemia: a follow-up of 22 cases. *Can Med Assoc J* 1965;92:861-865
8. Chugani HT, Phelps ME, Mazziotta JC. Positron emission tomography study of human brain functional development. *Ann Neurol* 1987;22:487-497
9. Takashima S, Chan F, Becker LE, Armstrong DL. Morphology of the developing cortex of the human infant. *J Neuropathol Exp Neurol* 1980;39:487-501
10. Boothe RG, Greenough WT, Lund JS, Wrege K. A quantitative investigation of spine and dendritic development of neurons in visual cortex (area 17) of macaca nemestrina monkeys. *J Comp Neurol* 1979;186:473-490
11. Purves D, Lichtman JW. *Principles of Neural Development*. Sunderland, Mass: Sinauer Associates, 1988