

# Cerebral Infarction: Diagnosis and Assessment of Prognosis by Using $^{123}\text{I}$ IMP-SPECT and CT

L. Anne Hayman<sup>1</sup>  
 Katherine H. Taber<sup>1</sup>  
 Satish G. Jhingran<sup>2</sup>  
 James M. Killian<sup>3</sup>  
 Robert G. Carroll<sup>4</sup>

A multicenter prospective study was performed in 49 patients with 77 regions of cerebral infarction. Each patient was evaluated in the acute (0–5 days) and subacute (6–17 days) phases by (1) clinical neurologic examination, (2) CT scans, and (3) *N*-isopropyl-*p*- $^{123}\text{I}$ -iodoamphetamine ( $^{123}\text{I}$ IMP) single-photon emission CT (SPECT) scans. The abilities of the scans to (1) detect a lesion and (2) predict the clinical outcome were assessed. For lesion detection,  $^{123}\text{I}$ IMP-SPECT was superior to CT in the first 2 days, but the scans were equally effective 3–5 days after onset. In the subacute phase, IV contrast-enhanced CT was superior to  $^{123}\text{I}$ IMP-SPECT and unenhanced CT. The clinical outcome was only mildly correlated with the results of the acute and subacute  $^{123}\text{I}$ IMP-SPECT and the acute CT scans. Reduction in lesion size on the subacute scans did not correlate with clinical improvement.

We conclude that the parameters measured by CT and  $^{123}\text{I}$ IMP-SPECT in patients with acute cerebral infarction cannot reliably be used to predict clinical outcome.  $^{124}\text{I}$  contamination of  $^{123}\text{I}$ IMP and the use of low-energy collimators may have decreased lesion detectability.

A number of imaging techniques are available for evaluating patients with cerebral infarction. CT can be used to detect zones of edema and necrosis. IV contrast-enhanced CT can be used to detect zones of neovascularity in the subacute phase of cerebral infarction.

A relatively new technique, *N*-isopropyl-*p*- $^{123}\text{I}$ -iodoamphetamine ( $^{123}\text{I}$ IMP) single-photon emission CT (SPECT), has been advocated as a sensitive method for determining relative regional cerebral blood flow [1–4]. With this technique, perfusion defects can be seen as early as 6 hr after clinical onset of stroke symptoms. In some patients, the lesions are much larger than those seen on a companion CT scan. In others, only the  $^{123}\text{I}$ IMP-SPECT scan is abnormal. Animal studies have shown that the  $^{123}\text{I}$ IMP marker is more sensitive in the acute phase of asymptomatic cerebral ischemia than are the MR parameters of T1 and T2 [5].

The purpose of this study was to prospectively evaluate the clinical usefulness of CT and  $^{123}\text{I}$ IMP-SPECT scans in acute and subacute stroke patients who have nonhemorrhagic infarctions. Two criteria were evaluated: (1) the ability of the scans to locate an abnormal region and (2) the value of the scans to predict the clinical outcome.

## Subjects and Methods

Patients with sudden onset of neurologic deficits attributable to cerebral infarction were screened with a CT head scan. Patients with cerebral hemorrhage or abnormalities other than cerebral infarction were excluded. A standardized neurologic examination was then performed in the remaining patients. These patients were enrolled in the study and signed an informed consent form. Each patient was then studied by a  $^{123}\text{I}$ IMP\*-SPECT scan. SPECT images were obtained with GE 400T, GE 400AT, or Technicare Omega 500 tomographic cameras with medium- or low-energy collimators. Reconstructions were processed by MDS

Received April 2, 1987; accepted after revision September 15, 1988.

This work was supported by Medi-Physics, Emeryville, CA.

<sup>1</sup> Department of Radiology, Baylor College of Medicine, Texas Medical Center, 1 Baylor Plaza, Houston, TX 77030. Address reprint requests to L. A. Hayman.

<sup>2</sup> Section of Nuclear Medicine, Baylor College of Medicine, Texas Medical Center, Houston, TX 77030.

<sup>3</sup> Department of Neurology, Baylor College of Medicine, Texas Medical Center, Houston, TX 77030.

<sup>4</sup> Department of Radiology, Nuclear Medicine Service, University of South Florida College of Medicine, Bay Pines VAMC, Bay Pines, FL 33504.

**AJNR** 10:557–562, May/June 1989

0195–6108/89/1003–0557

© American Society of Neuroradiology

\* Medi-Physics, Emeryville, CA.

A<sup>2</sup>, GE Star, or ADAC 3300 computer systems. X-ray CT imagers were modern by 1983 standards.

A <sup>123</sup>IMP-SPECT scan was obtained in the acute phase of the stroke 0–5 days after the onset of symptoms. A companion CT scan was also obtained during this period. The <sup>123</sup>IMP-SPECT and CT scans were repeated in the subacute phase of the stroke, 5–17 days after onset. When clinically indicated, patients underwent IV contrast-enhanced (40 g I) CT scanning, in addition to the protocol CT.

Patients who did not receive iodinated contrast medium for the CT scan were given potassium iodine by mouth before the <sup>123</sup>IMP-SPECT scan. A dose of 3–6 mCi (111–222 MBq) was used for each study. To avoid increased cortical occipital blood flow caused by visual stimulation, the patients kept their eyes closed during and for 5 min after the IV injection of IMP.

Two follow-up neurologic examinations were done. The first was 2–6 days after onset and the last was 5–11 days after onset of symptoms. The outcome in each patient was judged by the same neurologist, who compared the first and last examinations. One author evaluated and standardized the clinical parameters of all 49 patients from the multicenter data.

The following clinical parameters were evaluated. A clinical determination of type of stroke (embolic, thrombotic, or indeterminate) was recorded. In addition, the neurologic examination was used to judge the severity of the stroke at the time of onset as either mild, moderate, or severe. Information from the <sup>123</sup>IMP-SPECT and CT scans was combined to determine the location and vessel territory affected. The charts of cerebral function and vessel territories devised by Hayman et al. [6–8] were used as the standard reference. Every abnormal area was graded separately. Areas that were abnormal on any of the <sup>123</sup>IMP-SPECT or CT brain scans were always assumed to be lesions, even if there was no clinical correlation. This assumption was made for two reasons: (1) in many cases, the severity of the neurologic deficits recorded precluded bedside neurologic testing of other areas and (2) damage in certain areas of brain produces no clinically overt manifestation. Thus, the grading system used for this analysis did not attempt to identify false-positive scans.

Two authors reviewed all of the CT and <sup>123</sup>IMP-SPECT brain scans before and after learning of the clinical setting. No attempt was made to exclude scan abnormalities that were not supported by the clinical information. Regions of CT abnormality that were nonspecific (e.g., periventricular low density, calcification in the basal ganglia, and old lacunae that were unchanged on the serial scans) or represented a previously recorded event were excluded from consideration.

The quality of each <sup>123</sup>IMP-SPECT and CT brain scan was graded as fair or good. Patients with poor scans due to technique or motion were not included in this study. The time between onset of symptoms and each scan was recorded. In each area, the results of the <sup>123</sup>IMP-SPECT scans were categorized as (1) normal, (2) decreased tracer uptake, or (3) increased tracer uptake. The CT scan was categorized as either normal or abnormal. In selected cases, each area was reassessed on contrast-enhanced CT scans, which were categorized as normal, no enhancement, or enhancement of the area.

When two or more scans were positive in a given area of abnormality, the authors recorded the size of the area on each scan and compared its size with the size recorded on other scans. Each abnormal area was also categorized by location as (1) a small lesion in the white matter, basal ganglia, thalamus, brainstem, or any combination of these areas; (2) a small cortical lesion (one branch of a cerebral artery); (3) a moderate cortical lesion (more than one branch); or (4) a large cortical lesion (involving all of one or more cerebral arteries). All the data were entered into an IBM PC and analyzed with the SYSTAT statistical package.<sup>†</sup> To evaluate the correlations between variables, a Kendall's tau test was performed. This modification of the Pearson product moment correlation coefficient

for discrete-level data provided a conservative estimate with values ranging from +1 to -1.

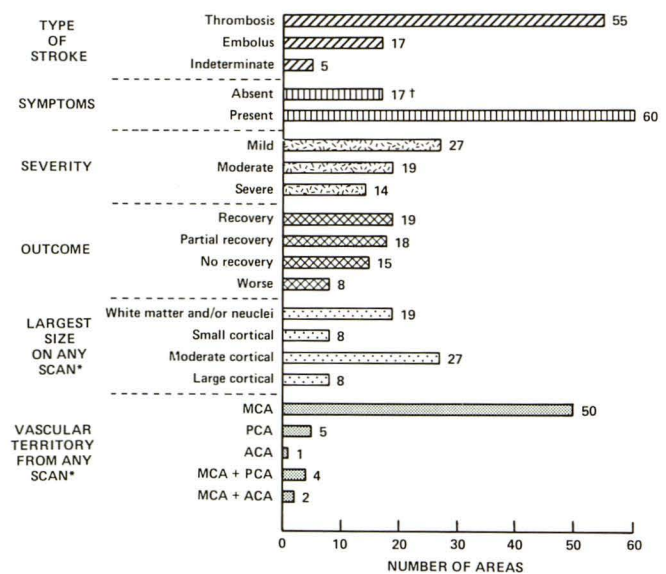
After completion of the initial analysis of the images, new processing software became available. A second full analysis was performed on a subset of the total cases in which SPECT images were reprocessed with newly available software in order to obtain maximal data extraction from noisy images.

**Results**

Ninety-seven patients were entered into the study. Forty-nine patients, 29 men and 20 women, completed the full protocol (i.e., they had acute-phase and subacute-phase <sup>123</sup>IMP-SPECT and CT scans that were graded as fair or good in quality and complete companion neurologic examinations). If a single imaging examination was inadequate or neurologic information was not available the patient was deleted from the study. The mean age of the patients was 68 ± 12 years (range, 35–90). There was no correlation between the age of the patient and any of the measures taken. Seventeen patients had multiple areas of involvement; these were graded and analyzed separately (nine of 17 had two areas, five had three areas, and three had four areas). Thus, there were a total of 77 abnormal areas among 49 patients. A breakdown of these areas by type of stroke, clinical symptoms, severity at onset, outcome, largest size of the lesion on any scan, and vessel territory of the lesion can be found in Figure 1.

*Acute Phase (0–5 Days)*

*Lesion detection.*—During this period only 35% (27/77) of the lesions were detected on the unenhanced CT scans. The



\*Note 15 areas were present clinically but not seen on any scan therefore they are not included in this category.

† The absence of clinical symptoms in these 17 areas precluded grading them in the severity and outcome categories.

**Fig. 1.**—Frequency data for 77 areas of cerebral infarction. MCA = middle cerebral artery; PCA = posterior cerebral artery; ACA = anterior cerebral artery.

<sup>†</sup> Systat, Inc., Evanston, IL.

addition of IV contrast material did not significantly improve detection (Table 1). The companion <sup>123</sup>IMP-SPECT scan allowed detection of 53% (41/77) of the lesions. To determine if the lesion detection rates on CT and <sup>123</sup>IMP-SPECT scans could be compared without bias, the time elapsed between the onset of the stroke and the performance of the various studies was assessed. The companion CT and <sup>123</sup>IMP-SPECT scans were all obtained within a reasonable time span, except for some of the scans in the unenhanced CT/<sup>123</sup>IMP-SPECT set. Twenty-nine pairs of images in this group were obtained more than 1 day apart, which was considered unacceptable. However, when these areas were excluded from the data set and the comparison recalculated for companion scans obtained within 24 hr of one another, the rate of lesion detection was increased only slightly for both studies (Table 2). Detection on CT increased to 40% (19/48) and detection on the <sup>123</sup>IMP-SPECT increased to 56% (27/48).

The comparison between the <sup>123</sup>IMP-SPECT and CT results is shown in Table 3. Results were the same (either both positive or both negative) in 58% (45/77) of the cases. When both scans detected a lesion, the lesion on the IMP scan was judged to be larger in 10 of 18 regions, while the lesion was larger on CT in only one of 18 cases. Adjusting the data so that only companion scans obtained within 24 hr of one another were compared did not change the results significantly (Table 3). Of particular concern was the frequency of mismatches between the companion scans. In 23 cases, a lesion was detected on IMP-SPECT that was not seen on

**TABLE 1: <sup>123</sup>IMP-SPECT and CT Results in Imaging Acute and Subacute Cerebral Infarction**

Study: Finding	No. (%)	
	Acute Phase	Subacute Phase
<sup>123</sup> IMP SPECT:		
No. of days after onset (mean)	2.5 ± 1.1	10 ± 2.6
Abnormal uptake:		
Decreased	40 (52)	20 (26)
Increased	1 (1)	9 (12)
Subtotal	41 (53)	29 (38)
Normal	36 (47)	48 (62)
Total	77 (100)	77 (100)
Precontrast CT:		
No. of days after onset (mean)	1.4 ± 1.1	9.1 ± 2.4
Abnormal	27 (35)	35 (45)
Normal	50 (65)	42 (55)
Total	77 (100)	77 (100)
Postcontrast CT:		
No. of days after onset (mean)	1.8 ± 1.0	9.3 ± 2.6
Abnormal:		
Enhancement	0	17 (41)
No enhancement	12 (35)	9 (21)
Subtotal	12 (35)	26 (62)
Normal	22 (65)	16 (38)
Total	34 (100)	42 (100)

Note.—<sup>123</sup>IMP = *N*-isopropyl-*p*-<sup>123</sup>I-iodoamphetamine; SPECT = single-photon emission CT.

**TABLE 2: Adjusted <sup>123</sup>IMP-SPECT and CT Results in Imaging Acute Cerebral Infarction**

Study: Finding	No. (%)
<sup>123</sup> IMP-SPECT:	
No. of days after onset (mean)	2.2 ± 1.0
Abnormal uptake:	
Decreased	26 (54)
Increased	1 (2)
Subtotal	27 (56)
Normal uptake	21 (44)
Total	48 (100)
CT:	
No. of days after onset (mean)	1.7 ± 1.0
Abnormal	19 (40)
Normal	29 (60)
Total	48 (100)

Note.—<sup>123</sup>IMP = *N*-isopropyl-*p*-<sup>123</sup>I-iodoamphetamine; SPECT = single-photon emission CT.

unenhanced CT, and in nine cases, a lesion was detected on CT that was not seen on <sup>123</sup>IMP-SPECT. In seven of these nine cases, small lesions (<1–2 cm) in the basal ganglia or white matter were below the limits of SPECT resolution.

The division of the acute phase into an early (0–2 days) and late phase (3–5 days) showed that on the early <sup>123</sup>IMP-SPECT scans, 55% of the lesions were detected, as compared with 30% on the early CT scans. Contrast enhancement on CT did not increase the level of lesion detection (Fig. 2). In the late phase (3–5 days), the <sup>123</sup>IMP-SPECT, nonenhanced CT, and enhanced CT scans each detected 50–51% of lesions.

*Clinical correlation.*—The results of the unenhanced CT, enhanced CT, and <sup>123</sup>IMP-SPECT scans were compared with the clinical parameters (i.e., type of stroke, severity of stroke, outcome, location, and territory involved). There were no correlations between either unenhanced and enhanced CT and any of the clinical parameters except for a mild correlation between unenhanced CT and clinical outcome (tau value = 0.207). There was no discernible pattern between the results of the <sup>123</sup>IMP-SPECT scan and the type of stroke or its severity or territory affected. There was a mild correlation between the ability of the <sup>123</sup>IMP-SPECT scan to detect a lesion and the clinical outcome (tau value = 0.272). Exclusion of small zones of infarct below the resolution of the SPECT camera reduced the correlation with the clinical outcome (tau value = 0.262).

#### Subacute Phase (>5 Days)

*Lesion detection.*—During the subacute phase, the rate of lesion detection was lower for <sup>123</sup>IMP-SPECT (38%) but increased slightly for CT without contrast enhancement (45%) compared with the acute phase (Table 1). Addition of IV contrast material to the CT scan improved lesion detection to 62% (26/42). There was no significant difference between the rate of detection during the early (6–10 days) or the later (10–17 days) portions of the subacute phase (Fig. 2).

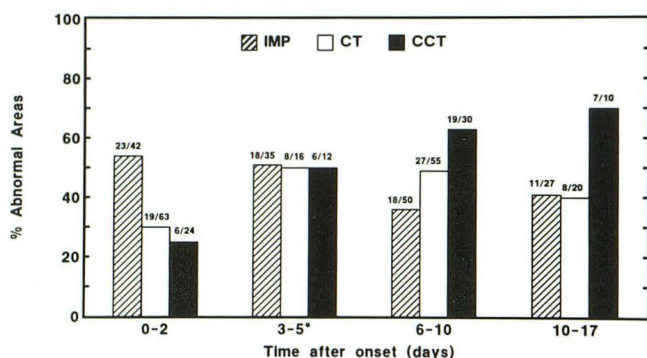
A lesion was detected on unenhanced CT during the subacute phase that had not been seen during the acute phase

TABLE 3: Comparison of  $^{123}\text{I}$ IMP-SPECT and CT in Imaging Cerebral Infarction

Finding	No. (%)		
	Acute	Adjusted Acute <sup>a</sup>	Subacute
Scan results were different:			
IMP positive; CT negative	23 (30)	14 (29)	13 (17)
IMP negative; CT positive	9 (12)	6 (13)	19 (25)
Scan results were the same:			
IMP negative; CT negative	27 (35)	15 (31)	29 (37)
IMP positive; CT positive:			
IMP lesion larger than CT lesion	10	6	3
IMP lesion equal to CT lesion	7	7	9
IMP lesion smaller than CT lesion	1	0	4
Subtotal	18 (23)	13 (27)	16 (21)
Total	77 (100)	48 (100)	77 (100)

Note.— $^{123}\text{I}$ IMP = *N*-isopropyl-*p*- $^{123}\text{I}$ -iodoamphetamine; SPECT = single-photon emission CT.

<sup>a</sup> See Results section.



\*2 of the areas in the subacute group had CT2 and CCT2 scans at 5 days. For the purposes of this table they were shifted into the acute group.

Fig. 2.—Percentage of abnormal results vs time after onset of stroke for pre- and postcontrast CT and  $^{123}\text{I}$ IMP-SPECT images. CT2 and CCT2 = acute-phase noncontrast and contrast CT, respectively.

in only 10% (8/77) of the cases, and there were no cases in which a lesion seen on CT during the acute phase was not also seen on CT during the subacute phase (Table 4). The size of a lesion on acute-phase unenhanced CT increased on subacute CT in three of 27 cases and decreased in five of 27 cases.

A lesion was detected on a  $^{123}\text{I}$ IMP-SPECT scan during the subacute phase that had not been seen on the acute-phase  $^{123}\text{I}$ IMP-SPECT scan in 5% (4/77) of the cases. In 21% (16/77) of cases, the lesion seen during acute-phase  $^{123}\text{I}$ IMP-SPECT was not seen during the subacute-phase study. The size of the lesion on  $^{123}\text{I}$ IMP-SPECT during the acute phase increased in the subacute-phase scan in three of 25 cases and decreased in eight of 25 (Table 4).

The comparison between the  $^{123}\text{I}$ IMP-SPECT and the CT is shown in Table 3. The results were the same (either both positive or both negative) in 58% (45/77) of the cases. When both scans detected a lesion, the lesion on the subacute  $^{123}\text{I}$ IMP-SPECT scan was judged to be larger in three of 16 regions, while the lesion was larger on subacute CT in four of 16 regions. In 13 cases, a lesion was detected on subacute  $^{123}\text{I}$ IMP-SPECT that was not seen on subacute CT, and in 19 cases a lesion was detected on subacute CT that was not

TABLE 4: Comparison of Acute and Subacute  $^{123}\text{I}$ IMP-SPECT and CT in Imaging Cerebral Infarction

Finding	No. (%)
Acute IMP vs subacute IMP:	
Scan results were different:	
Acute IMP positive; subacute IMP negative	16 (21)
Acute IMP negative; subacute IMP positive	4 (5)
Scan results were the same:	
Acute and subacute IMP both negative	32 (42)
Acute and subacute IMP both positive:	
Acute lesion larger than subacute lesion	8
Acute lesion equal to subacute lesion	14
Acute lesion smaller than subacute lesion	3
Subtotal	25 (32)
Total	77 (100)
Acute CT vs subacute CT:	
Scan results were different:	
Acute CT positive; subacute CT negative	0
Acute CT negative; subacute CT positive	8 <sup>a</sup> (10)
Scan results were the same:	
Acute and subacute CT both negative	42 (55)
Acute and subacute CT both positive:	
Acute lesion smaller than subacute lesion	3
Acute lesion equal to subacute lesion	19
Acute lesion larger than subacute lesion	5
Subtotal	27 (35)
Total	77 (100)

Note.— $^{123}\text{I}$ IMP = *N*-isopropyl-*p*- $^{123}\text{I}$ -iodoamphetamine; SPECT = single-photon emission CT.

<sup>a</sup> Five of these eight were imaged 0–0.4 days after onset.

seen on subacute  $^{123}\text{I}$ IMP-SPECT. Thirteen of these 19 lesions were small and were below the limits of SPECT resolution.

**Clinical correlation.**—There was no correlation between the subacute unenhanced CT scans and any of the clinical parameters. There was only a mild correlation between the subacute IMP-SPECT scans and the clinical outcome (tau value = 0.136). Exclusion of small zones of infarct below the resolution of the SPECT camera actually decreased the correlation with the clinical outcome to a tau value of 0.065.

Because none of the acute or subacute scan results were strongly correlated with the clinical outcome, a second analysis was done. The clinical parameters were compared with patterns of scan results. The following pairs were examined:

(1) acute  $^{123}\text{I}$ IMP-SPECT positive, subacute  $^{123}\text{I}$ IMP-SPECT negative; (2) acute  $^{123}\text{I}$ IMP-SPECT negative, subacute  $^{123}\text{I}$ IMP-SPECT positive; (3) acute and subacute  $^{123}\text{I}$ IMP-SPECT both negative; (4) acute and subacute  $^{123}\text{I}$ IMP-SPECT both positive; (5) acute CT positive, subacute CT negative; (6) acute CT negative, subacute CT positive; (7) acute and subacute CT both negative; (8) acute and subacute CT both positive; (9) acute CT negative, acute  $^{123}\text{I}$ IMP-SPECT positive; and (10) acute CT positive, acute  $^{123}\text{I}$ IMP-SPECT negative. None of the clinical parameters had a significant correlation with any of the pairs of scan results.

The results of the subacute  $^{123}\text{I}$ IMP-SPECT scan raised the possibility that a correlation might exist between the scan abnormality and the type of stroke. Of the nine areas that showed increased radiotracer uptake, seven were associated with strong clinical evidence to support the diagnosis of emboli while only two were judged to be thrombotic. Five of the areas with increased tracer uptake were clinically silent. Of the remaining four areas, one was an area with a mild neurologic deficit, one was an area with a moderate neurologic deficit, and two were areas with a severe deficit. All nine areas of increased uptake were in the middle cerebral territory and eight of nine were moderate or large cortical lesions.

Of the 20 areas in which uptake decreased, 19 were judged to be thrombotic stroke, while only one was judged to be embolic. Only three of 20 areas with decreased uptake were clinically silent. Of the remaining 17 areas, four were associated with mild, seven with moderate, and six with severe neurologic defects.

A second full data analysis was performed by using a subset of the total cases in which images were reprocessed by those centers that believed that newly available filtering and reconstruction software might improve the SPECT data. Of the original 77 regions, 46 were included in the reanalysis. Because there were only minor changes in the results obtained in these 46 regions, there were no significant differences between the results of the first and second analyses. Thus, acute  $^{123}\text{I}$ IMP-SPECT still allowed detection of approximately one-half (47%) of the lesions, and the detection rate was higher in the early phase (48%) than in the late phase (43%). Similarly, on the acute unenhanced CT scans, only one-third (34%) of the lesions were detected. As with the first analysis, the results were the same on acute unenhanced CT and  $^{123}\text{I}$ IMP-SPECT (both positive or both negative) in slightly more than one-half (54%) of the cases, and of the eight lesions that were missed on acute  $^{123}\text{I}$ IMP-SPECT that were identified on acute CT, six were small lesions in the basal ganglia and white matter. As with the first analysis, the rate of lesion detection dropped during the subacute phase to about one-third (36%) for  $^{123}\text{I}$ IMP-SPECT. A lesion was detected on subacute  $^{123}\text{I}$ IMP-SPECT but not on acute  $^{123}\text{I}$ IMP-SPECT in 2% (1/46) of the cases. In 13% (6/46) of the cases the lesion seen on acute  $^{123}\text{I}$ IMP-SPECT was not seen on subacute  $^{123}\text{I}$ IMP-SPECT. Overall, then, the reanalysis of the data after image enhancement supported totally the conclusions drawn from the first analysis, indicating that the pattern of results was *not* due to inadequate image processing. Image quality may have been compromised by  $^{124}\text{I}$  contamination producing septal and camera side penetration from activity in

the lung and liver. Holman et al. [2] discussed the  $^{124}\text{I}$  contamination problem as early as 1982.

## Discussion

The  $^{123}\text{I}$ IMP-SPECT scan obtained within 48 hr after the onset of symptoms was found to be more sensitive in detecting the presence and size of abnormal brain regions than the companion CT scan. Both examinations were equally effective by 3–5 days after onset. The addition of IV contrast enhancement to the acute CT scan did not improve the rate of lesion detection in the acute phase.

Detectability of small lesions on IMP imaging was compromised by background noise from scatter photons from high-energy contaminants present in  $^{123}\text{I}$  made by the P-2N reaction. Modern gamma cameras used in this clinical trial do not have adequate side shielding to prevent penetration by 600-keV gamma rays from  $^{124}\text{I}$  contamination. Lung and liver activity also contributes to septal penetration, especially when low-energy collimators are used. Medi-Physics dosimetry data indicate that at 11 min after injection 24% of the total dose is in the lungs, 8% is in the liver, and 5.6% is in the brain. At 1 hr, 15% of the total dose is in the lungs, 13% is in the liver, and 6% is in the brain. Side penetration of the gamma camera and septal penetration of the collimator by 600-keV gamma rays from  $^{124}\text{I}$  in lung and liver degrades the image obtained from the 159-keV gamma rays collimated from  $^{123}\text{I}$  in the brain. Septal penetration by 600-keV gamma rays occurs even with medium-energy collimators, but is a particular issue with low-energy collimators [9–12].  $^{124}\text{I}$  contamination levels in this clinical trial were comparable to the current package insert data, which allow up to 4.8%  $^{124}\text{I}$  at the time of calibration and up to 6.2%  $^{124}\text{I}$  at the 6-hr expiration time. IMP made with  $^{123}\text{I}$  from the P-5N reaction does not contain  $^{124}\text{I}$  contamination. Therefore, a clinical trial of IMP containing pure  $^{123}\text{I}$  would be of interest.

Both the acute CT and  $^{123}\text{I}$ IMP-SPECT (0–5 days) scans showed only a mild correlation with clinical outcome. Combining the results of either of the acute studies with data obtained from subsequent studies in the subacute phase (6–17 days) did not result in a pattern that could predict the clinical outcome. Specifically, the presence of large regions of abnormality on the acute  $^{123}\text{I}$ IMP-SPECT scan that decreased in size or resolved on the subacute  $^{123}\text{I}$ IMP-SPECT scan did not correlate with the degree of clinical recovery. This finding would be expected if the original blood-flow deficit represented a mild decrease in blood flow that did not result in a neurologic deficit.

In the subacute phase of cerebral infarct, the IV contrast-enhanced CT scan was clearly superior to either the unenhanced CT or the  $^{123}\text{I}$ IMP-SPECT scan in lesion detection. In fact, the subacute IV contrast-enhanced CT scan was the most effective overall imaging technique in the study (see Table 1). However, neither the contrast-enhanced nor the unenhanced subacute CT scans showed a significant correlation with clinical outcome. The subacute  $^{123}\text{I}$ IMP-SPECT scan showed only a mild clinical correlation with outcome. The timing of these scans 6–17 days after the onset of symptoms makes the superior detection rate of the IV con-

trast-enhanced CT scan and the mild clinical correlation of the  $^{123}\text{I}$ IMP-SPECT scan of dubious clinical value. The data do not support the hypothesis that repeating the CT or  $^{123}\text{I}$ IMP-SPECT studies during the subacute phase will yield a significant increase in the rate of lesion detection compared with the acute scans (see Table 4). Raynaud et al. [13] suggested that a "peripheral area" of moderately decreased IMP uptake around a chronic infarct might be useful in establishing prognosis and evaluating the efficacy of therapy. A halo of prolonged T2 has also been noted around chronic infarctions on MR scans. It was proposed that this represented "blood flow alterations," "hypometabolism," or ischemic penumbra. However, careful pathologic correlation in a postmortem brain specimen has shown this region corresponds with wallerian degeneration [14].

There was a 12% incidence (9/77) of increased IMP tracer uptake in the subacute category compared with a 1% incidence of this pattern in the acute category (see Table 1). The small number of cases with this pattern prevented the statistical analysis of the significance of this finding. It was noted, however, that seven of the nine regions seen in the subacute group were associated with clinical evidence of embolic rather than thrombotic infarcts. This pattern of infarct may be associated with increased cerebral perfusion and, therefore, tracer deposition after lysis of the embolus. This observation may have clinical significance in evaluating the cause of the infarction. However, there was no correlation between the patients' symptoms and this type of abnormality on the  $^{123}\text{I}$ IMP-SPECT scan (i.e., five of nine areas were clinically silent).

Recently, investigators have suggested that  $^{123}\text{I}$ IMP-SPECT studies should be supplemented by obtaining a second set of delayed images 4–6 hr after injection. Ueda et al. [15] reported 12 patients with cerebrovascular disease, and they suggested that initial hypoactivity, which approached normal on the 4- to 6-hr images, might represent "hypofunctioning parenchyma without significant damage." These preliminary studies await the evaluation of a statistically significant clinical trial.

### Summary

The measurement of relative regional cerebral blood flow with the use of  $^{123}\text{I}$ IMP-SPECT scans in the acute and subacute phases of cerebral infarction had only a mild correlation with clinical outcome. The sensitivity of the IMP marker to zones of reduced perfusion in asymptomatic cortical areas may account for this finding. The  $^{123}\text{I}$ IMP-SPECT scan was the most sensitive for detecting a lesion in the first 48 hr after clinical onset.

Although CT is a sensitive marker of cerebral edema and necrosis, in patients with acute cerebral infarction the quantification of these regions has only a mild correlation with the

clinical outcome. The addition of IV contrast medium in patients with subacute cerebral infarction resulted in the most sensitive technique for detecting the lesion, but it had no correlation with the clinical outcome.

### ACKNOWLEDGMENTS

This cooperative study was carried out at the following medical centers: Thomas Jefferson University Medical Center, Philadelphia, PA; The Veterans Administration Medical Center, Bay Pines, FL; Veterans Administration Medical Center, Tucson, AZ; The Johns Hopkins Medical Institution, Baltimore, MD; St. Paul Hospital, Dallas, TX; The Methodist Hospital, Houston, TX; University of Massachusetts Medical Center, Worcester, MA; and Emory University Hospital, Atlanta, GA.

### REFERENCES

- Hill TC, Holman BL, Lovett RD, et al. Initial experience with SPECT (single-photon computerized tomography) of the brain using N-isopropyl I-123 p-iodoamphetamine. *J Nucl Med* **1982**;23:191–195
- Holman BL, Hill TC, Magistretti PL. Brain imaging with emission computed tomography and radiolabeled amines. *Invest Radiol* **1982**;17:206–215
- Moretti JL, Askienazy S, Raynaud C, et al. N-isopropyl-p-iodoamphetamine I-123 en tomographic cerebral. *Ann Radiol (Paris)* **1983**;26:59–67
- Holman BL, Hill TC, Polak JF, Lee RGL, Royal HD, O'Leary DH. Cerebral perfusion imaging with iodine 123-labeled amines. *Arch Neurol* **1984**;41:1060–1066
- Holman BL, Jolesz FA, Polak JF, Kronauge JF, Adams DF. Comparison of I-123 IMP cerebral uptake and MR spectroscopy following experimental carotid occlusion. *Invest Radiol* **1985**;20:370–373
- Hayman LA, Berman SA, Hinck VC. Correlation of CT cerebral vascular territories with cerebral function: II. Posterior cerebral artery. *AJNR* **1981**;2:219–225, *AJR* **1981**;137:13–19
- Berman SA, Hayman LA, Hinck VC. Correlation of CT cerebral vascular territories with cerebral function by computed tomography. III. Middle cerebral. *AJNR* **1984**;5:161–166, *AJR* **1984**;142:1035–1040
- Berman SA, Hayman LA, Hinck VC. Correlation of CT cerebral vascular territories with cerebral function: I. Anterior cerebral artery. *AJNR* **1980**;1:259–263, *AJR* **1980**;135:253–257
- Polak JF, English RJ, Holman BL. Performance of collimators used for tomographic imaging of I124 contaminated I123. *J Nucl Med* **1983**;23:1065–1069
- Baker GA, Lum DJ, Smith EM, Winchell HS. Significance of radiocontaminants in I123 for dosimetry and scintillation camera imaging. *J Nucl Med* **1976**;17:740–743
- Mueller SP, Polak JF, Kijewski MF, Holman L. Collimator selection for SPECT brain imaging: the advantage of high resolution. *J Nucl Med* **1986**;27:1729–1738
- Macey DJ, Denardo GL, Denardo SJ, Hines H. Comparison of low and medium-energy collimators for SPECT imaging with iodine 123 labelled antibodies. *J Nucl Med* **1986**;27:1467–1474
- Raynaud C, Rancurel G, Samson Y, et al. Pathophysiologic study of chronic infarcts with I-123 isopropyl iodo-amphetamine (IMP): the importance of periinfarct area. *Stroke* **1987**;18:21–29
- Dewitt LD, Kistler JP, Miller DC, Richardson EP. NMR-neuropathologic correlation in stroke. *Stroke* **1987**;18:342–351
- Ueda T, Kinoshita K, Watanabe K, Hoshi H, Jinnouchi S. Early and delayed single photon emission CT in various cerebral diseases using N-isopropyl-p-(123I)iodoamphetamine. *Neuroradiology* **1988**;30:123–131