

# Acute Intracranial Hemorrhage Secondary to Thrombocytopenia: CT Appearances Unaffected by Absence of Clot Retraction

Jeffrey N. Pierce, Katherine H. Taber, and L. Anne Hayman

**PURPOSE:** To describe the in vivo CT appearance of acute intracerebral blood clots formed from anemic platelet-depleted blood. **METHODS:** Three patients with intracerebral hemorrhage secondary only to thrombocytopenia were examined with CT within 2½ hours after the onset of clinical symptoms. **RESULTS:** There were no unusual CT features found in the intracerebral hemorrhages of patients with only thrombocytopenia. Specifically, a hyperdense zone(s) surrounded by areas of decreased density was identified. **CONCLUSION:** Clot retraction (which cannot occur in patients with severe thrombocytopenia) is not necessary for the CT appearance of acute intracerebral hemorrhage.

**Index terms:** Cerebral hemorrhage; Anemia; Blood, coagulation; Platelets; Brain, computed tomography

*AJNR Am J Neuroradiol* 15:213–215, Feb 1994

The early computed tomography (CT) literature proposed that the process of retracted clot formation created the hyperdense appearance of intracerebral hemorrhage on CT scans (1–3). Others subsequently demonstrated that increased CT density could be produced in vitro by artificial techniques that pack unclotted red blood cells (4–6). It is now well accepted that CT provides a noninvasive measure of hemoglobin concentration (6, 7). Hemoglobin levels above 9 to 11 g/dL allow visualization of intracerebral hemorrhage as a hyperdense zone on CT scans of the brain. This study was undertaken to determine whether the presence of the gelatinous *unretracted* clot which forms in anemic patients with severe thrombocytopenia is visible as a hyperdense zone on CT.

## Methods

Three cases of *isolated* thrombocytopenia with CT-documented intracerebral hemorrhage were reviewed. The CT scans in each were of excellent quality and were performed within 2½ hours after onset of neurological

symptoms. The patients had thrombocytopenia caused by: phenobarbital in case 1; aplastic anemia in case 2; and idiopathic thrombocytopenia in case 3. There were no other diseases or sources of coagulopathy in any of these cases. Only case 1 survived. The pertinent laboratory values were obtained from the medical records. They are summarized in Table 1.

## Results

In all three cases, hyperdense regions of hemorrhage were clearly seen on the CT scans obtained within 2½ hours after clinical onset of neurologic symptoms. In two cases, multiple areas of density were seen (Figs 1 and 2). In the third (prospective) case, a single massive cerebral hemorrhage was observed, which had a heterogeneous appearance (Fig 3). The Hounsfield units in this intracerebral hemorrhage ranged from  $36.1 \pm 3.7$  to  $68.1 \pm 2.8$ , which corresponded to a

TABLE 1: Summary of data on cases 1 to 3

Case	Age	Sex	Hemoglobin <sup>a</sup> (g/dl)		Platelet Count <sup>b</sup> (thousands of cells/mm <sup>3</sup> )		PT/PTT <sup>c</sup>
			Admission	Before CT	Admission	Before CT	
1	61	F	5.3	7.5	6.0	9.0	10.9/21.2
2	61	F	3.8	7.5	0	9.0	9.9/18.5
3	37	F	10.2	10.5	8.0	7.0	14.1/31.0

<sup>a</sup> Hemoglobin (normal range of 12 to 16 g/dL).

<sup>b</sup> Platelet count (normal range 150 to 400 000 of cells/mm<sup>3</sup>).

<sup>c</sup> PT indicates prothrombin time (sec) (normal range of 10.4 to 13.8 sec); PTT, partial thromboplastin time (sec) (normal range of 20 to 38 sec).

Received October 28, 1992; accepted pending revision January 28, 1993; revision received March 8.

From the Department of Radiology and Herbert J. Frensky Center for Imaging Research, Baylor College of Medicine, One Baylor Plaza, Houston, TX 77030. Address reprint requests to L. Anne Hayman, MD.

*AJNR* 15:213–215, Feb 1994 0195-6108/94/1502-0213

© American Society of Neuroradiology



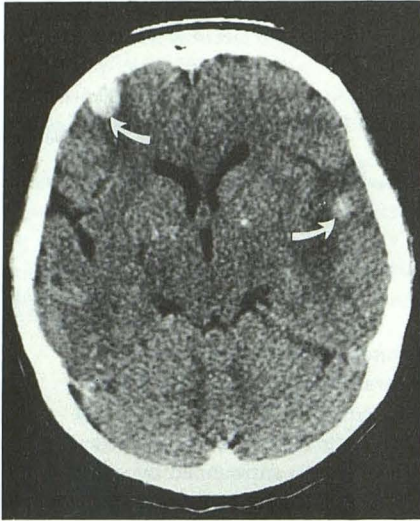


Fig. 1. Case 1. Axial CT scan done 2 hours after clinical onset demonstrates two sharply circumscribed hyperdense hematomas in the right middle frontal gyrus and the left superior temporal gyrus (arrows).

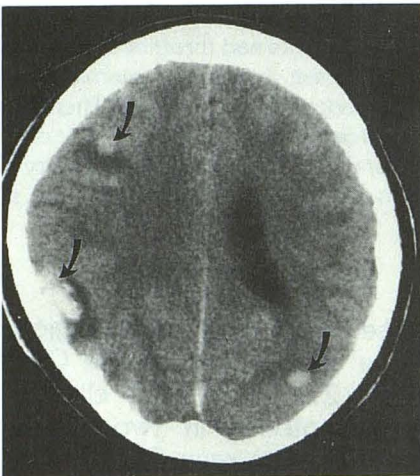


Fig. 2. Case 2. Axial CT scan done 2.5 hours after clinical onset demonstrates sharply circumscribed hyperdense hematomas in the right middle temporal and inferior frontal gyri and the left inferior temporal gyrus (arrows).

hemoglobin concentration of 5.5 to 19 g/dl. The mean value of the hypodense zones surrounding the intracerebral hemorrhage was  $23.7 \pm 1.7$ . The mean values for normal gray and white matter in the contralateral cerebral hemisphere were  $33.7 \pm 5.1$  and  $24.5 \pm 0.7$ , respectively.

### Discussion

It is well documented that patients with thrombocytopenia (ie, platelet counts below  $20,000/\text{mm}^3$ ) form clots that cannot retract (8–10). The CT appearance of these unusual clots was sur-

prisingly unaffected by the absence of clot retraction. They appeared no different from normal clots (11, 12). The hypodense rim around the hematoma has been attributed to serum created by clot retraction (13). This CT finding in all of our cases indicates that fluid accumulates around a hematoma even if clot retraction does not occur. This phenomenon can best be explained by examining the work done with in vitro blood clots. Serum is held within a clot by the capillary forces generated by the fibrin mesh of the clot (9). Even without clot retraction, the clot loses *some* serum: this is presumably the cause of the hypodense ring seen around the intracerebral hemorrhage in our cases. Severe deficiencies in the fibrin mesh (ie, patients with coagulopathies, not thrombocytopenia) result in large quantities of free serum; fluid-blood levels can be seen in these patients (14). Fluid-blood levels have been reported within intracerebral hemorrhage found in patients with coagulopathies that interfere with the formation of a clot itself or cause lysis of the clot matrix (15, 16). Fluid-blood levels are commonly encountered when unclotted blood settles in the dependent portion of the ventricular or subarachnoid space. This did not occur in our patients because their fibrin mesh formation was normal.

Intracerebral hemorrhage in patients with isolated thrombocytopenia occurs in less than one percent of cases (17–21). Two cases of unretracted intracerebral hemorrhage caused by thrombocytopenia have been reported (22). The

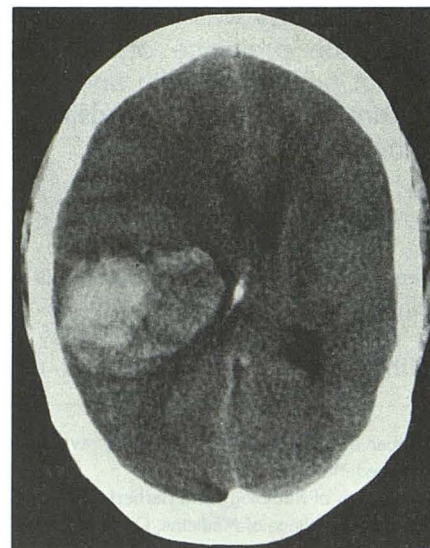


Fig. 3. Case 3. Axial CT scan done 2 hours after clinical onset demonstrate a huge inhomogenous, hyperdense hematoma in the right parietal lobe.



presence or absence of other clotting disorders in these patients was not described. In the present study, cases of thrombocytopenia associated with leukemia, liver disease, alcoholism, and other significant clotting factor abnormalities were excluded. The patients comprising this report had intracerebral hemorrhage secondary *only* to thrombocytopenia.

All three patients in this report and the two cases previously cited had hyperdense hematomas indicating hemoglobin concentrations that clearly exceeded the density of normal cortex. CT scans in each of the two patients published previously showed multiple zones of intracerebral hemorrhage which resembled cases 1 and 2 in this series. The hemoglobin values in case 3 measured as high as 19 gm/dL. This indicates that even in the presence of anemia, red blood cell aggregation aided only by the formation of an unretracted clot is sufficient for CT detection of acute intracerebral hemorrhage. This contradicts the hypothesis that clot retraction is necessary to produce the hyperdense appearance of hemorrhage on CT.

In summary, we have described three patients with anemia and intracerebral hemorrhage caused by isolated thrombocytopenia who had hyperdense zones on CT scans of the brain acquired within 2½ hours after the onset of clinical symptoms. We conclude that the classic CT appearance of an acute intracerebral hemorrhage is attributable to increased density caused by the formation of an unretracted clot. Development of the surrounding hypodense ring probably results because the capillary forces of the fibrin mesh inside the clot are not sufficient to hold all of the serum within it.

## References

- Ambrose J. Computerized transverse axial scanning (tomography): Part 2. Clinical application. *Br J Radiol* 1973;46:1023-1047
- Ambrose J. Computerized x-ray scanning of the brain. *J Neurosurg* 1974;40:679-695
- Bergstrom M, Ericson K, Levander B, Svendsen P, Larsson S. Variation with time of the attenuation values of intracranial hematomas. *J Comput Assist Tomogr* 1971;1:57-63
- New PFJ, Aronow S. Attenuation measurements of whole blood and blood fractions in computed tomography. *Radiology* 1976;121:635-640
- New PFJ, Scott WR. *Computed tomography of the brain and orbit*. Baltimore: Williams and Wilkins, 1975:263-267
- Norman D, Price D, Boyd D, Fishman R, Newton TH. Quantitative aspects of computed tomography of the blood and cerebrospinal fluid. *Radiology* 1977;123:335-338
- Smith WP, Batnitzky S, Rengachary SS. Acute isodense subdural hematomas: a problem in anemic patients. *AJNR Am J Neuroradiol* 1981;2:37-40
- Tullis JL. *Clot*. Springfield, Ill: Charles C. Thomas, 1976:32-65
- Budtz-Olsen OE. *Clot retraction*. Springfield, Ill: Charles C. Thomas, 1951:14-15
- Tocantins LM. Platelets and the structure and physical properties of blood clots. *Am J Physiol* 1936;114:709-715
- Kendal BE, Radue EW. Computed tomography in spontaneous intracerebral haematomas. *Br J Radiol* 1978;51:563-573
- Cohen WA, Hayman LA. Computed tomography of intracranial hemorrhage. *Neuroimaging Clin N Am* 1992;2:1-13
- Enzmann DR, Britt RH, Lyons BE, Buxton JL, Wilson DA. Natural history of experimental intracerebral hemorrhage: sonography, computed tomography and neuropathology. *AJNR Am J Neuroradiol* 1981;2:517-526
- Pfleger MJ, Hardee EP, Contant CF Jr, Hayman LA. Sensitivity and specificity of fluid-blood levels for coagulopathy in acute intracerebral hematomas. *AJNR Am J Neuroradiol* 1994;15:217-223
- Weisberg LA. Significance of the fluid-blood interface in intracranial hematomas in anticoagulated patients. *Comput Radiol* 1987;11:175-179
- Livoni JP, McGahan JP. Intracranial fluid-blood levels in the anticoagulated patient. *Neuroradiology* 1983;25:335-337
- Born GVR, Begent NA, Cusack NJ. Functional physiology of platelets. In: Biggs R, Rizza CR, eds. *Human blood coagulation, haemostasis and thrombosis*. 3rd ed. Oxford: Blackwell Scientific Publications, 1984:319-348
- Wintrobe MM, Lee RG, Boggs DR, et al. *Clinical hematology*. Philadelphia: Lea and Febiger, 1981:1096-1127
- Cahill DW, Ducker TB. Spontaneous intracerebral hemorrhage. *Clin Neurosurg* 1982;29:722-779
- Taheri SA, Wani MA, Lewko J. Uncommon causes of intraventricular hemorrhage. *Clin Neurol Neurosurg* 1990;92:195-202
- McCormick WF, Rosenfield DB. Massive brain hemorrhage: a review of 144 cases and an examination of their causes. *Stroke* 1973;4:946-954
- Scott WR, New PFJ, Davis KR, Schnur JA. Computerized axial tomography of intracerebral and intraventricular hemorrhage. *Radiology* 1974;112:73-80