

Glioblastoma Multiforme: MR Imaging at 1.5 and 9.4 T After Injection of Polylysine-DTPA-Gd in Rats

Steven Kornguth¹
Mark Anderson²
Patrick Turski³
James Sorenson³
H. Ian Robins¹
Justin Cohen¹
Al Rappe³
John Markley²

Polylysine-DTPA-Gd, a new MR contrast agent, was injected into the aorta of rats 7 days after C6 glioblastoma was implanted in their brains; MR imaging was performed 3 days later. The imaging was done at two field strengths: (1) 1.5 T with a 3-mm slice thickness and in-plane resolutions of 600 μm and (2) 9.4 T with a 125- or 500- μm slice thickness and in-plane resolutions of 95 μm . In animals injected with polylysine-DTPA-Gd (1 μg or more per rat), the T1-weighted images and mixed T1, T2 images of the C6 glioblastoma revealed a higher signal intensity at the marginal region between tumor and normal brain than that seen in surrounding normal brain. The central tumor region had a low signal intensity. The concentration of Gd in the C6 glioblastoma, after injection of 1 μg polylysine-DTPA-Gd per rat, was calculated to be 0.14 $\mu\text{mol/l}$. The central tumor region also had a low signal intensity in animals that were not injected with the contrast agent, but the margin between tumor and normal brain was resolved poorly, if at all. The polylysine-DTPA-Gd revealed the microvasculature of the C6 glioblastoma in the 125- μm -thick slices obtained at 9.4 T.

This is the first study to reveal the utility of the 9.4-T MR imager for examination of glioblastomas in situ and to demonstrate the utility of polylysine-DTPA-Gd as a contrast agent for the definition of the margin between glioblastoma and normal brain tissue.

AJNR 11:313-318, March/April 1990

Determination of the marginal region between normal tissues and tumors is important in the surgical, chemical, and radiologic management of neoplasms. In the case of rapidly growing intracranial tumors, such as glioblastomas, delineation of the tumor margin by imaging agents should provide more precise definition of the tumor size, shape, and vascularity [1, 2]. MR imaging at 1.5 T has provided a useful tool for the study of brain structure in rats [3, 4]; imaging at 9.4 T has provided information on the structure of human tumor xenografts in nude mice [5]. The development and use of MR contrast agents, which bind to glioblastoma cells to an extent greater than to endothelial and normal brain cells, may facilitate the precise localization of the tumor in vivo because these agents provide an increased signal-to-noise ratio; the increased definition of the tumor margin may facilitate the therapeutic management of the disease.

We have previously demonstrated [6] that rat C6 and human U87MG glioblastoma cells, in vitro, bind 10 times more to polylysine (4×10^8 molecules of polylysine per cell) than endothelial cells do. Many tumors have a high binding capacity for polylysine [7-12] because their cell surface carries a higher net negative charge than the surface of many nontumor cells [7, 13]. The question arises as to whether the effectiveness of a tumor imaging agent, such as paramagnetic gadolinium, can be enhanced by introducing it into a tumor-selective binding molecule such as polylysine. Polylysine has very weak antigenic properties [14, 15]; therefore it can be used repeatedly as a carrier vehicle. The present report describes the synthesis of polylysine-DTPA-Gd and examines its effect on the imaging of C6 glioblastoma in rat brains at 1.5 and 9.4 T.

Received July 14, 1989; revision requested August 21, 1989; revision received September 7, 1989; accepted September 14, 1989.

This work was supported by a grant from the American Cancer Society, RD-298 (to S. Kornguth), and by grants from the Graduate School of the University of Wisconsin, Madison, the Departments of Radiology and Neurology, and the Thornton Fund for Neurooncology Research at the University of Wisconsin, Madison. J. Cohen is supported by National Institutes of Health Training Grant T32 CA09614.

¹ Department of Neurology, Room 659 Waisman Center, University of Wisconsin, Madison, WI 53706.

² Department of Biochemistry, University of Wisconsin, Madison, WI 53706.

³ Department of Radiology, University of Wisconsin, Madison, WI 53706

0195-6108/90/1102-0313
© American Society of Neuroradiology

Materials and Methods

Poly-L-lysine hydrobromide (DP88) was purchased from Sigma (St. Louis). The polylysine was obtained as the fluorescein derivative (DP88 by light scattering). The fluorescein permitted rapid analysis, by fluorometry, of the polylysine concentration. DTPA dianhydride was also purchased from Sigma.

The polylysine was coupled covalently to DTPA by modifications [6] of previously published methods [16–19]. The polylysine hydrobromide was dissolved in bicarbonate buffer (0.1 mol/l, pH 9.0); then, DTPA, dissolved in anhydrous dimethyl sulfoxide (DMSO), was added to the polylysine. Polylysine-DTPA complexes were prepared with one DTPA per 16 lysyl residues. To prepare these complexes, a stoichiometric ratio of one DTPA dianhydride in DMSO was added per 10 lysyl residues. The reaction was permitted to proceed for 60 min at 25°C; then, the reactants were passed through G-25 Sephadex columns (PD-10 columns from Pharmacia, Piscataway, NJ) that were preequilibrated with citrate buffer (0.1 mol/l, pH 5.5). The polylysine-DTPA product emerged at the void volume of the column.

The DTPA-modified polylysine in citrate buffer was reacted with gadolinium chloride (Aldrich Chem., Milwaukee, WI) dissolved in the same citrate buffer. The polylysine-DTPA-Gd chelates were then passed through G-25 Sephadex gel filtration columns, which were preequilibrated with 0.15 mol/l of sodium chloride, to separate the free gadolinium from the polylysine-DTPA-Gd complex.

The C6 glioblastoma cells were cultured in Ham F10 medium supplemented with 2.5% fetal calf serum (Hyclone Laboratories, Logan, UT), 15% horse serum (Gibco, North Andover, MA), 100 µg streptomycin and 100 U penicillin/ml, and 1.2 g bicarbonate buffer/l.

Male Wistar-Furth rats (approximately 320 g each) were purchased from Harlan Sprague Dawley (Indianapolis, IN). The rats were separated into five groups of three animals each (see Table 1). Groups 1–4 were implanted with the C6 glioblastoma cells (2×10^6 cells in 10 µl of Ham medium containing 0.5% agarose) through a 0.5-mm-diameter burr hole, placed 3 mm to the left of the midline in the frontal region. Cells were injected through a 25-gauge needle over a period of 2–3 min. Group 5, the nontumor control group, was injected with Ham medium, but without tumor cells. Seven days after tumor implantation, groups 1–3 received intraaortic injections of polylysine-DTPA-Gd: 100, 10, and 1 µg/animal, respectively. Rats in group 4 were injected with medium without any polylysine-DTPA-Gd. The nontumor controls in group 5 received a dose of 100 µg polylysine-DTPA-Gd. To ensure intraaortic injection, contrast medium was injected as illustrated (Fig. 1). The polylysine-DTPA-Gd, in 500 µl of saline solution, was then injected into the aorta.

Ten days after tumor implantation the animals were anesthetized with chloral hydrate and imaged by the 1.5-T Signa MRI Unit (General Electric, Milwaukee, WI) using the GE extremity coil (17-cm diameter). T1-weighted images were acquired with the 1.5-T instrument at the

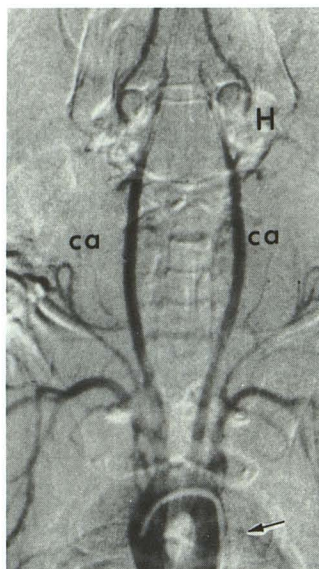


Fig. 1.—Fluoroscopic image of chest and head of rat with catheter placed in ascending aorta. Carotid arteries (ca), catheter tip (arrow), and cranial vasculature (H) are seen.

level of the frontoparietal cortex where the tumors were implanted. The technique parameters were 400/20 (TR/TE) in all cases shown; the image slice thicknesses were 3 mm and the in-plane resolution was 0.6 mm.

For 9.4-T imaging (Bruker AM-400 instrument, Karlsruhe, FRG), the brains were removed from the rats to permit insertion into the maximum 2.5-cm-diameter-capacity coil. The brains were covered with Saran wrap to prevent loss of moisture, positioned in a 20-mm NMR tube for imaging, and maintained at 4°C prior to and during imaging. The images had T1 and T2 characteristics and were acquired using a multislice spin-echo pulse sequence. Eight slices were acquired using 3000/16 (TR/TE) for the slice thicknesses that were obtained at 0.5 mm; the gradient strengths were 2.3 G/cm for the x and z dimensions and 2.2 G/cm for the y dimension. The TR of 3000 permitted multislice images to be acquired at this field strength. For the 0.125-mm-thick slices, the MR parameters were 3000/24 (TR/TE); the x gradient was 2.3 G/cm, the y was 2.2 G/cm, and the z gradient was increased to 9.3 G/cm. The in-plane resolution was 95 µm in all the 9.4-T images. Eight images were reconstructed either from adjacent 0.5-mm-thick sections or from adjacent 0.125-mm-thick sections of intact brain.

Tissue histology studies were performed on all brain samples to validate the location of the implanted C6 cells. Frozen sections (40 µm) of formalin-fixed brains were cut, stained with thionine, and covered with DePex embedding material (Gurr Microscopy, Ltd.) and a coverslip. The sections were examined in a DADS microscope (Leitz, E, Inc., Rockleigh, NJ) and photographed on an optical bench.

TABLE 1: Summary of Rat Groups, Treatment, and Analysis

Variable	Group				
	1	2	3	4	5
C6 tumor cells on day 1	+	+	+	+	–
Polylysine-DTPA-Gd on day 7 (µg/rat)	100	10	1	0	100
MR on day 10					
High signal intensity at tumor edge	+	+	+	–	–
Low or normal signal intensity in central tumor region	+	+	+	±	–
Identification of tumor by histology	+	+	+	+	–

Note.—There were three rats in each group.

Results

All the imaging data were obtained 10 days after C6 tumor implantation and 3 days after administration of the polylysine-DTPA-Gd contrast agent. This protocol permits the proliferation of the tumor cells in the rat brains during the first 7 days and maximizes the tumor-to-blood ratio of the polylysine-DTPA-Gd during the next 3 days. Appropriate controls without tumor cells or without polylysine-DTPA-Gd were included in the experimental design. The results obtained at the two field strengths are described separately.

MR at 1.5 T

There were major differences between the images of the C6 glioblastomas acquired *in vivo* from the rats that were injected with the polylysine-DTPA-Gd (Table 1, groups 1–3; Figs. 2–4) as compared with those from controls (Table 1, group 4), which did not receive the polylysine agent (Fig. 5). The MR images of the C6 glioblastomas in all the animals that received 100, 10, or 1 μ g polylysine-DTPA-Gd per rat (groups 1–3) revealed a zone of increased signal intensity between the marginal region of the tumor and the normal brain and a reduced lateral ventricle on the left (Figs. 2–4). The central tumor area had a low signal intensity in groups 1–4. These observations are illustrated by images acquired from group 2 rats injected with 10 μ g (Figs. 2 and 3) or group 3 rats injected with 1 μ g (Fig. 4) of the polylysine-DTPA-Gd. The diameters of the tumors were 3–4 mm in all animals, as measured on histologic sections (Figs. 2–5); the widths of the entire coronal sections of brain were 13–15 mm. No histologic evidence was found for a hematoma or vascular hemorrhage. Where hemorrhage has been observed in other experiments, its signal intensity was lower than in the central tumor region.

The boundary between tumor and normal brain tissue was in the same location whether determined by MR or histologic techniques (Figs. 2–4). Two tumor masses were observed in the left hemisphere of one rat in group 2 (Fig. 3); the mass on the dorsal surface extended from the brain when the cranial vault was opened. The high signal intensity of the tumor edge in this animal is apparent between the two tumor masses.

As seen in Figure 4, the MR images of the C6 glioblastomas were enhanced by the administration of 1 μ g polylysine-DTPA-Gd per rat, as compared with controls (group 4). The marginal region of the tumor had an increased signal intensity com-

pared with that of the surrounding tissue, and the central tumor region of one rat injected with 1 μ g of polylysine-DTPA-Gd had a low signal intensity. The observation that the marginal zones appear discrete and sharp on images acquired with a 3-mm slice thickness suggests that the polylysine-DTPA-Gd material had deposited in the tumor edge adjacent to the vascular bed.

The central region of tumor in one rat in group 4 (Fig. 5), which did not receive polylysine-DTPA-Gd, had a lower signal intensity than the surrounding normal brain, whereas the central tumor region in the two other rats in the same group had a signal intensity similar to that of normal brain. The ventricles in all three rats were reduced in size on the left, suggestive of an increased mass in the tumor-bearing hemisphere. There were no identifiable margins between the tumor mass and the normal brain in the group that was not exposed to polylysine-DTPA-Gd.

MR at 9.4 T

The 9.4-T images of the C6 tumors from group 2 animals treated with 10 μ g polylysine-DTPA-Gd (Figs. 2 and 3) reveal the detailed shape of the tumor *in situ* and the vascular margin of the intracerebral mass. The vascular bed of the tumor and the tumor margin were defined more precisely in the thinnest sections (9.4 T) than in the thicker sections (1.5 T), as seen in Figure 3. The central tumor region had a low signal intensity and the margin had an increased signal intensity. The images of the 125- μ m-thick slices of intact brain revealed fine, high-contrast, thin lines coursing through the tumor mass. The fine, thin lines of high signal intensity in the section appear to represent the vascular bed with the tortuous configuration of the vessels. The discrete areas of lower signal intensity are

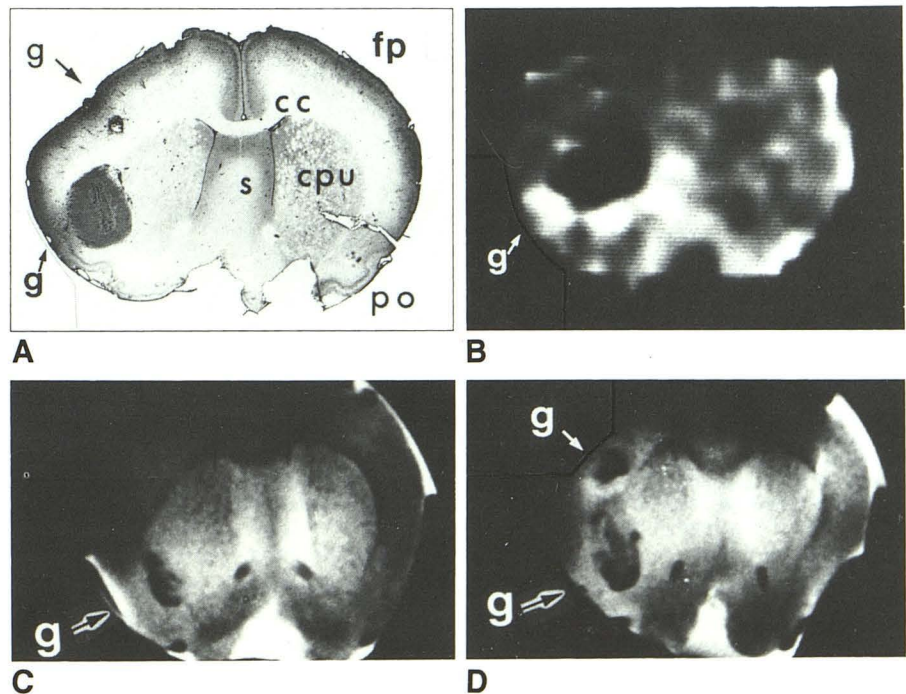


Fig. 2.—Rat injected with 10 μ g of polylysine-DTPA-Gd 7 days after intracerebral injection of glioma cells; images were acquired 3 days later.

A, Photograph of thionine-stained frozen coronal section (40 μ m thick) through frontoparietal cortex (fp). Glioblastoma (g) is in two sites: (1) ventrally near caudate putamen (cpu) and primary olfactory cortex (po); (2) more dorsally in parietal cortex (cc). s = septal nuclei.

B, 1.5-T MR image, 400/20, 3-mm-thick slice. Ventral and medial surfaces of glioblastoma have markedly increased signal intensity. Locations of glioblastoma on MR and histology sections are similar.

C and D, 9.4-T MR images, 3000/16, 500- μ m-thick slices. Ventral and medial surfaces of glioblastoma have higher signal intensity than surround normal brain, consistent with images acquired at 1.5 T.

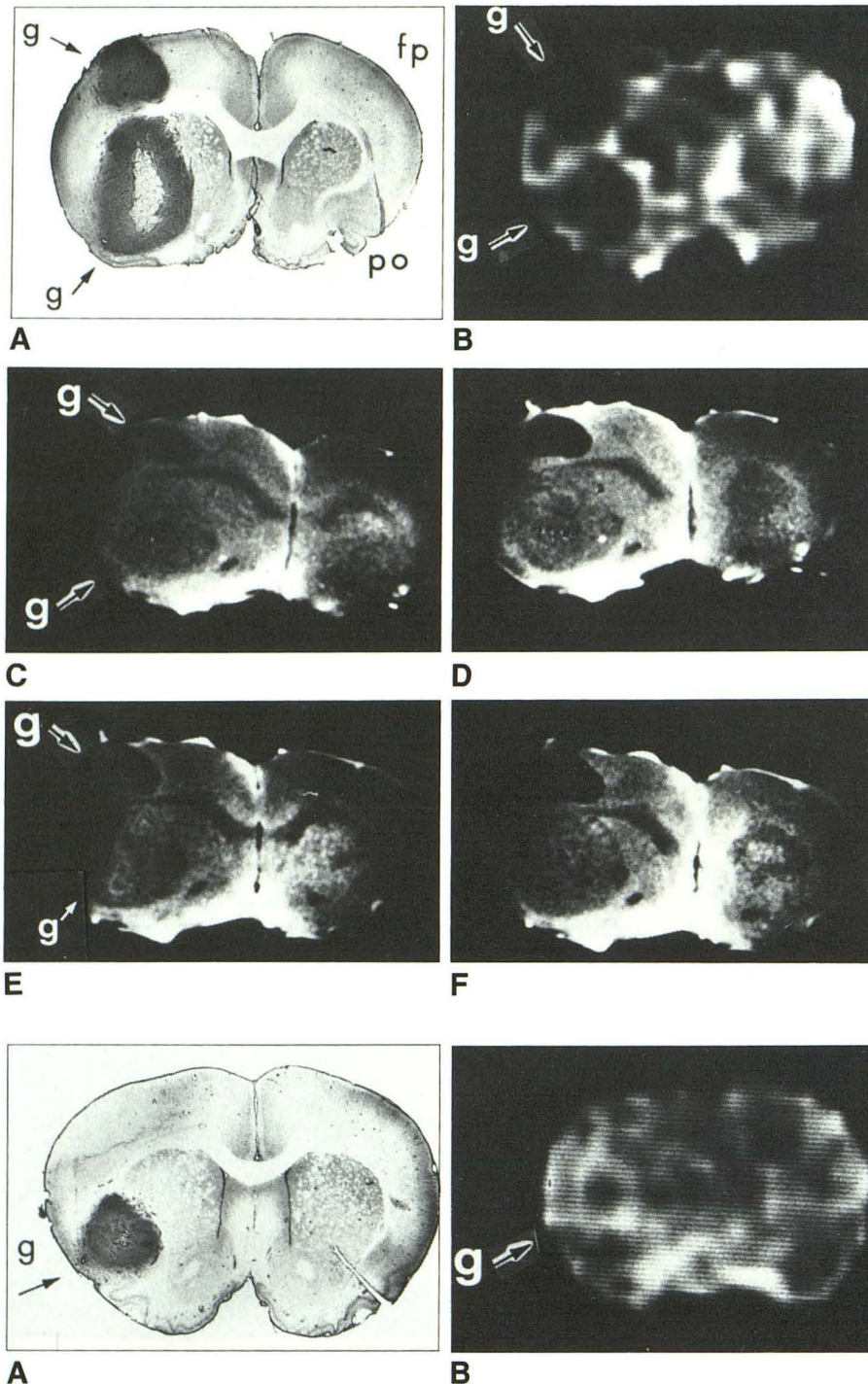


Fig. 3.—Rat injected with 10 µg of polylysine-DTPA-Gd 7 days after intracerebral injection of glioma cells; images were acquired 3 days later.
A, Photograph of thionine-stained frozen section (40 µm thick). Central region of ventral glioblastoma (g) appears necrotic. fp = frontoparietal cortex; po = primary olfactory cortex.

B, 1.5-T MR image, 400/20, 3-mm-thick slice. Ventral and medial margins of dorsal glioblastoma and dorsal and medial surfaces of ventral glioblastoma have markedly increased signal intensity.

C and D, 9.4-T MR images, 3000/16, 500-µm-thick slices. Dorsal tumor exhibits lower signal intensity than ventral tumor. **C** is caudal to **D**. Ventral surfaces of two gliomas in **C** and entire margin of both tumors in **D** have signal intensities higher than that of surrounding normal brain.

E and F, 9.4-T MR images, 3000/24, of 125-µm-thick slices through same cortical regions as **A–D**. Thin, tortuous curves of high signal intensity represent microvessels.

Fig. 4.—Rat injected with 1 µg of polylysine-DTPA-Gd 7 days after intracerebral injection of glioma cells; images were acquired 3 days later.
A, Photograph of thionine-stained frozen section (40 µm thick). Microvessels at margin between tumor and normal brain are seen as dark lines or dots. g = glioblastoma.

B, 1.5-T MR image, 400/20, 3-mm-thick slice. Dorsal and medial surfaces of glioblastoma have markedly increased signal intensity.

C, 9.4-T MR image, 3000/16, 500-µm-thick slice. One glioblastoma site with elevated signal intensity is seen on ventrolateral surface of glioma.

consistent with regions of internal necrosis (Fig. 3). When the same tumor region is examined at a thickness of 500 µm, the detail is less clear. The threadlike vascular elements in the tumor may be identified but with less certainty.

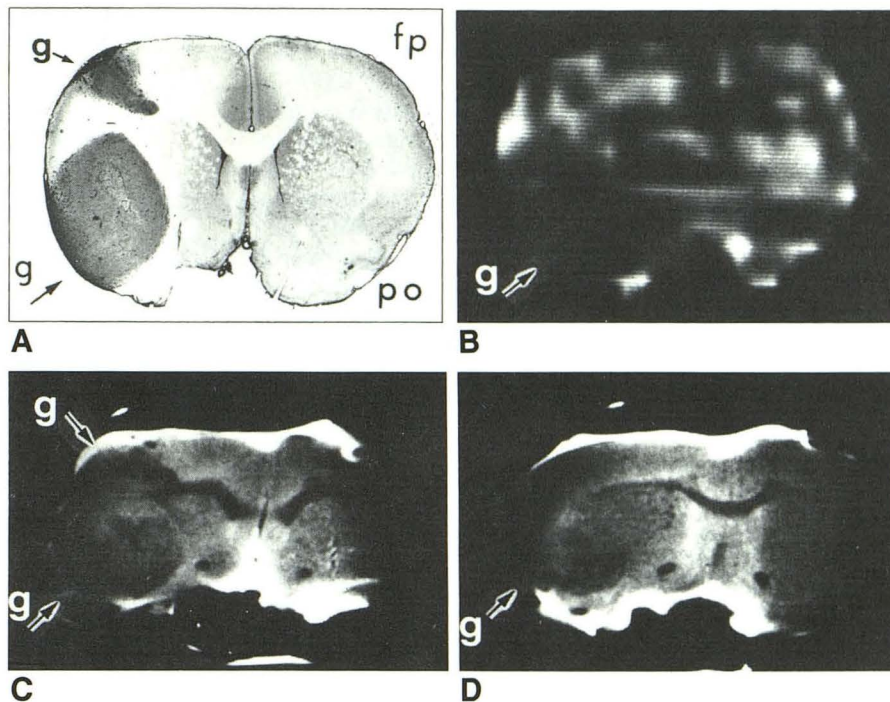
Images of the C6 glioblastoma in the brains that were not exposed to polylysine-DTPA-Gd (group 4) reveal a central dark low-signal-intensity region, an enlarged left hemisphere, and a reduced ventricular space (Fig. 5). The margin between

Fig. 5.—Rat implanted with C6 tumor but not injected with polylysine-DTPA-Gd before imaging 10 days after implantation.

A, Photograph of thionine-stained frozen coronal section (40 μ m thick) through frontoparietal cortex (fp). Two glioblastoma (g) sites are revealed: (1) ventrally near putamen and primary olfactory cortex (po); (2) more dorsally, protruding from parietal cortex.

B, 1.5-T MR image, 400/20, 3-mm-thick slice. There are no sharp demarcations between edge of tumor and surrounding brain.

C and D, 9.4-T MR images, 3000/16, 500- μ m-thick slices. C is caudal to D. There is a suggestion of tumor.



the tumor and the brain was not readily observed and the contrast change between the tumor mass and normal brain was gradual. No unusual contrast was observed in the non-tumor controls in group 5 that were subsequently injected with polylysine-DTPA-Gd.

Histology of the C6 Glioblastoma in the Brain of Rats

The shape, size, and location of the tumors in the rat brains, as revealed by MR, were correlated with the identification of the tumor by histologic analysis (Figs. 2–5). The images of the C6 glioblastoma in the brains that were treated with the polylysine-DTPA-Gd (Figs. 2–4) revealed a tumor shape consistent with the histology of the mass; when the tumor had multiple lobes the MR images revealed multiple lobes (Figs. 3 and 5). Whereas the images obtained at 1.5 T revealed the general shape of the tumor, the images from the 9.4-T instrument were more reflective of the precise tumor shape.

Discussion

The polylysine-DTPA-Gd imaging agent used in the present study has different properties than Gd-DTPA alone. Whereas the low-molecular-weight Gd-DTPA rapidly enters and leaves the CNS tumor area (within 40 min), the higher-molecular-weight polylysine-DTPA-Gd (12,000–20,000 d) will enter the tumor area and remain bound to tumor cells for longer than 96 hr, as observed in separate studies. Because the polylysine-DTPA-Gd complex remains in the tumor, it can provide a high signal-to-noise ratio as the blood level of the contrast agent falls.

The border region between the tumor and normal brain exhibited an increased signal intensity in all the tumor-bearing animals that were injected intraaortically with 1 μ g or more of polylysine-DTPA-Gd. This concentration is two to three orders below the toxic level of polylysine, which is reported to be 1.5 mg/100 g body weight [10, 20]. The increased signal intensity at the tumor margin observed on T1-weighted images is consistent with an enhancement in the rate of relaxation of water protons, which is caused by localization of the polylysine-DTPA-Gd complex in the tumor. The central zone of the C6 glioblastoma in the rat brain and of other nitrosourea-induced gliomas in rat brain is frequently necrotic [21], an observation consistent with the low-signal-intensity images obtained in our study.

The concentration of the polylysine-DTPA-Gd complex in the tumor was estimated in order to determine whether the increased signal intensity at the tumor margin could result from the gadolinium present. From studies with polylysine-DTPA complexes labeled with ^{153}Gd and ^{89}Zr [6], it was observed that 0.07–0.4% of the injected polylysine became localized to the tumor in vivo when 100 μ g of the labeled polylysine was injected per animal. Since the polylysines have one DTPA per 15 lysyl residues, and the total volume of the tumors approximates 15 mm^3 (tumor diameters are 3–4 mm), it can be calculated that the concentration of gadolinium in the tumor is approximately 14–28 $\mu\text{mol/l}$ after a dose of 100 μ g polylysine-DTPA-Gd has been administered. If the same percentage of polylysine-DTPA-Gd is bound by the tumor when 1 μ g of the polypeptide is injected, then the tumor would contain 0.14 $\mu\text{mol/l}$ Gd. A concentration of 0.2 $\mu\text{mol/l}$ of paramagnetic gadolinium was previously shown by us to yield a detectable MR signal at 1.5 T [19].

The MR contrast changes can result from one or a combination of factors: (1) the increased permeability of the blood-brain barrier in the tumor close to the polylysine-DTPA-Gd [22, 23], (2) the selective binding of the polylysine contrast agent to tumor cells, and (3) the increased tumor neovascularization resulting in adhesion of the polylysine-DTPA-Gd contrast agent to the interface between the tumor and endothelial cells [24]. Polylysine [22] and other polyamines [23] have been observed to increase vascular permeability on a dose- and chain length-dependent basis. Polylysines that have a molecular weight of under 25,000 ($DP > 125$) require a concentration of >1 mg/ml to effect an increase in endothelial cell permeability [22]. Since the studies reported here involve the injection of much lower concentrations of the polylysine (i.e., 1–100 μ g), its permeating activity can be considered to be negligible.

The peripheral vasculature of rat gliomas consists primarily of type III microvessels, which are sinusoidal in structure and have a tortuous course and a diverse caliber [21]. The microvessels in the C6 glioblastoma, which were revealed in the 125- μ m-thick slices at 9.4 T, had identical characteristics (Fig. 3), indicating that they were of the type III group. It is known that the blood-brain barrier in the region of the type III microvessels has an increased permeability to proteins and other large-molecular-weight materials in the blood compartment [21]. Thus, the increased permeability to the polylysine-DTPA-Gd may be one reason for the clear definition of the tumor margin.

Zagzag et al. [24] have noted that the boundary between normal brain and the VX2 brain tumor in experimental rabbits is markedly enhanced on CT imaging after injecting iohalamate meglumine. Contrast enhancement and vascular proliferation were most conspicuous at the growing tumor edge. When Zagzag et al. [24] inhibited angiogenesis in the tumor by treatment with penicillamine, the tumor did not enhance on CT, indicating that angiogenesis was required for CT imaging with iohalamate meglumine. It is likely that, in the present study, the extensive angiogenesis in the margin of the growing tumor is a second important factor explaining the increased signal intensity of the margin between normal brain and the C6 glioblastomas observed in the presence of polylysine-DTPA-Gd.

REFERENCES

1. Brant-Zawadzki M, Kelly W. Brain tumors. In: Brant-Zawadzki M, Norman D, eds. *Magnetic resonance imaging of the central nervous system*. New York: Raven 1987:151–185
2. Price AC, Runge VM, Nelson KL. CNS-neoplastic disease. In: Runge VM, ed. *Enhanced magnetic resonance imaging*. St. Louis: Mosby, 1989: 139–177
3. Runge VM, Jacobson S, Wood M, Kaufman D, Adelman L. MR imaging of rat brain glioma: Gd-DTPA versus Gd-DOTA. *Radiology* 1988;166: 835–838
4. Johnson GA, Thompson MB, Drayer BP. Three dimensional MRI microscopy of the normal rat brain. *Magn Reson Med* 1987;4:351–365
5. Sarkar S, Mattingly MA, Kline T, Greig R. 9.4 T imaging studies of human tumor xenografts in nude mice. *Invest Radiol* 1988;23:677–679
6. Kornguth S, Kalinke T, Robins HI, Cohen J, Turski P. The preferential binding of radiolabeled poly-L-lysines to C6 and U87 MG glioblastomas compared with endothelial cells in vitro. *Cancer Res* 1989;49:6390–6395
7. Ambrose EJ, Easty DM, Jones PCT. Specific reactions of polyelectrolytes with the surfaces of normal and tumor cells. *Br J Cancer* 1958;12: 439–447
8. Richardson T, Hodgett J, Lindner A, Stahmann M. Action of polylysine on some ascites tumors in mice. *Proc Soc Exp Biol Med* 1959;101:382–386
9. Ryser HJ-P, Mandel R, Hakobian A, Shen W. Methotrexate-poly(lysine) as a selective agent for mutants of Chinese hamster ovary cells defective in endocytosis. *J Cell Physiol* 1988;135:277–284
10. Sela M, Katchalski E. Biological properties of poly alpha amino acids. *Adv Protein Chem* 1959;14:391–478
11. Kornguth S, Stahmann M. Effect of polylysine on the leakage and retention of compounds by Ehrlich ascites tumor cells. *Cancer Res* 1961;21: 907–912
12. Kornguth S, Stahmann M, Anderson J. Effect of polylysine on the cytology of Ehrlich ascites tumor cells. *Exp Cell Res* 1961;24:484–494
13. Gu JM, Robinson J, Leung S. Binding of acrylic polymers to mucin epithelial surfaces: structure property relationships. *Crit Rev Ther Drug Carrier Syst* 1988;5:21–67
14. Buchanan-Davidson D, Stahmann MA, Lapresle C, Grabar P. Immunochemistry of synthetic polypeptides and polypeptidyl proteins. *J Immunol* 1959;83:552–560
15. Mauer P, Subrahmanyam D, Katchalski E, Blout ER. Antigenicity of polypeptides (poly-alpha amino acids). *J Immunol* 1959;83:193–199
16. Hnatowich DJ, Layne WW, Childs RL, Lanteigne D, Davis MA. Radioactive labeling of antibody: a simple and efficient method. *Science* 1983;220: 613–615
17. Krejcarek G, Tucker K. Covalent attachment of chelating groups to macromolecules. *Biochem Biophys Res Commun* 1977;77:581–585
18. Paik CH, Murphy PR, Eckelman WC, Volkert WA, Reba RC. Optimization of the DTPA mixed anhydride reaction with antibodies at low concentration. *J Nucl Med* 1983;24:932–936
19. Kornguth SE, Turski PA, Perman WH, et al. Magnetic resonance imaging of gadolinium-labelled monoclonal antibody polymers directed at human T lymphocytes implanted in canine brain. *J Neurosurg* 1987;66:898–906
20. de Vries A, Feldman JD, Stein O, Stein Y, Katchalski E. Effects of intravenously administered poly DL-lysine. *Proc Soc Exp Biol Med* 1953;82: 237–240
21. Nishio S, Ohta M, Abe M, Kitamura K. Microvascular abnormalities in ethylnitrosourea (ENU) induced rat brain tumors: structural basis for altered blood-brain barrier function. *Acta Neuropathol (Berl)* 1983;59:1–10
22. Needham L, Hellewell PG, Williams TJ, Gordon JL. Endothelial functional responses and increased vascular permeability induced by polycations. *Lab Invest* 1988;59:538–548
23. Koenig H, Goldstone A, Lu CY. Polyamines mediate the reversible opening of the blood-brain barrier by the intracarotid infusion of hyperosmolar mannitol. *Brain Res* 1989;483:110–116
24. Zagzag D, Goldenberg M, Brem S. Angiogenesis and blood-brain barrier breakdown modulate CT contrast enhancement: an experimental study in a rabbit brain-tumor model. *AJNR* 1989;10:529–534