

Cervical Internal Carotid Artery Injuries Due to Blunt Trauma

Solomon Batnitzky,^{1,2} Hilton I. Price,¹ Robert W. Holden,² and Edmund A. Franken, Jr.²

Blunt or nonpenetrating trauma to the head and neck occasionally results in damage to the cervical segment of the internal carotid artery. This may produce neurologic signs and symptoms that mimic acute craniocerebral injury. The mortality and morbidity associated with these injuries are alarmingly high. These injuries may be missed if one relies only on computed tomography. Angiography is still the definitive procedure to diagnose these lesions. The clinical and radiographic features as well as the pathogenesis and mechanism of injury are discussed for 21 cases of injury to the cervical internal carotid artery due to blunt trauma.

Although rare, blunt or nonpenetrating injuries to the head and neck may result in damage to the cervical segment of the internal carotid artery (ICA). This damage may produce neurologic deficits that mimic the signs and symptoms of acute craniocerebral injury. The morbidity and mortality associated with these injuries are alarmingly high.

Computed tomography (CT) has virtually replaced angiography as the definitive radiologic procedure in the diagnosis and management of craniocerebral trauma [1], but because CT is not a particularly effective imaging mode for vascular sequelae, an arterial injury may go unrecognized because of the failure to suspect it. Physicians dealing with traumatized patients should be aware of this possibility and should not attribute all neurologic signs in the traumatized patient to direct cerebral injury. Angiography is still the procedure of choice to demonstrate the vascular sequelae of head and neck trauma.

Materials and Methods

We investigated 21 cases of injuries to the cervical segment of the ICA following blunt or nonpenetrating trauma. The patients were 16 to 57 years old (mean, 28.2 years). There were 12 males and nine females. The sources of trauma were: vehicular accidents, 18; head caught in metal punch press, one; fall on head during seizure, one; and hit on neck by a chair, one.

In 15 cases there was evidence of trauma to the forehead and face consisting of abrasions, contusions, and lacerations. In two cases there was external evidence of trauma to the neck, consisting of abrasions and contusions. Four patients exhibited no external evidence of trauma to the head or neck.

In 11 cases the onset of symptoms was immediate. In 10 cases

there was a delay of from 3 hr to 4 days in the onset of neurologic symptoms after the injury.

Plain skull films were normal in all 21 patients. Two patients had fractures involving the angle of the mandible, and one patient had a depressed fracture of the sternum. Cranial CT was performed in nine patients on admission to the hospital. It was repeated in five of these patients who suffered neurologic deterioration occurring 3–24 hr later.

In two patients, the initial CT scan demonstrated diffuse bilateral cerebral edema. The CT scans in the other seven patients and those five patients who had follow-up CT scans after neurologic deterioration were normal.

Bilateral carotid angiography was performed in all 21 patients. Bilateral involvement of the cervical ICAs was demonstrated in five

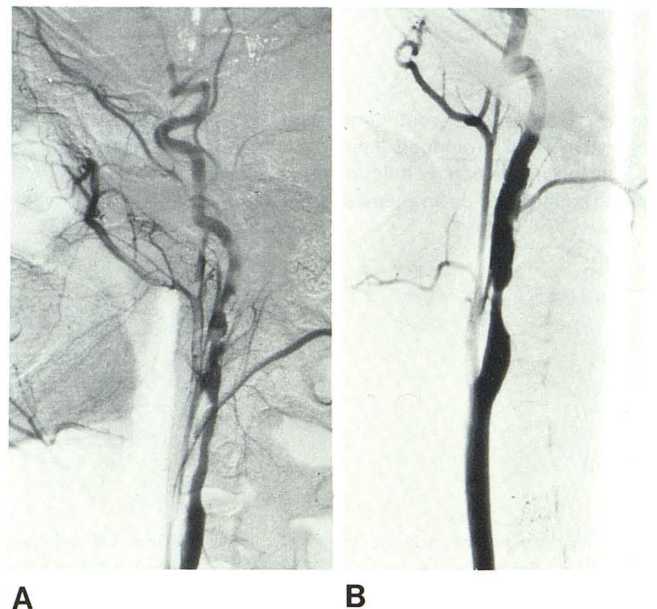
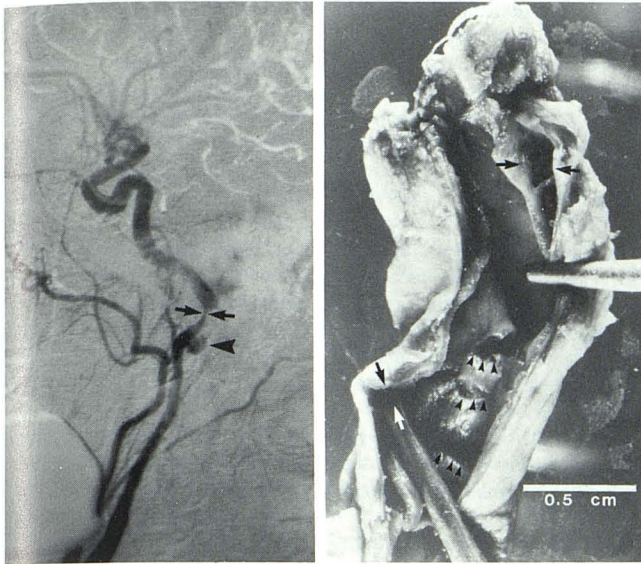


Fig. 1.—Angiography in 25-year-old woman after automobile accident. A, Left lateral carotid view. Dissecting aneurysm involves cervical segment of ICA. Extensive segment of narrowing and irregularity of lumen. B, Similar changes involve cervical segment of right ICA.

¹ Department of Diagnostic Radiology, University of Kansas College of Health Sciences and Hospital, Rainbow Boulevard at 39th Street, Kansas City, KS 66103. Address reprint requests to S. Batnitzky.

² Department of Radiology, Indiana University Medical Center, Indianapolis, IN 46202.



A **B**

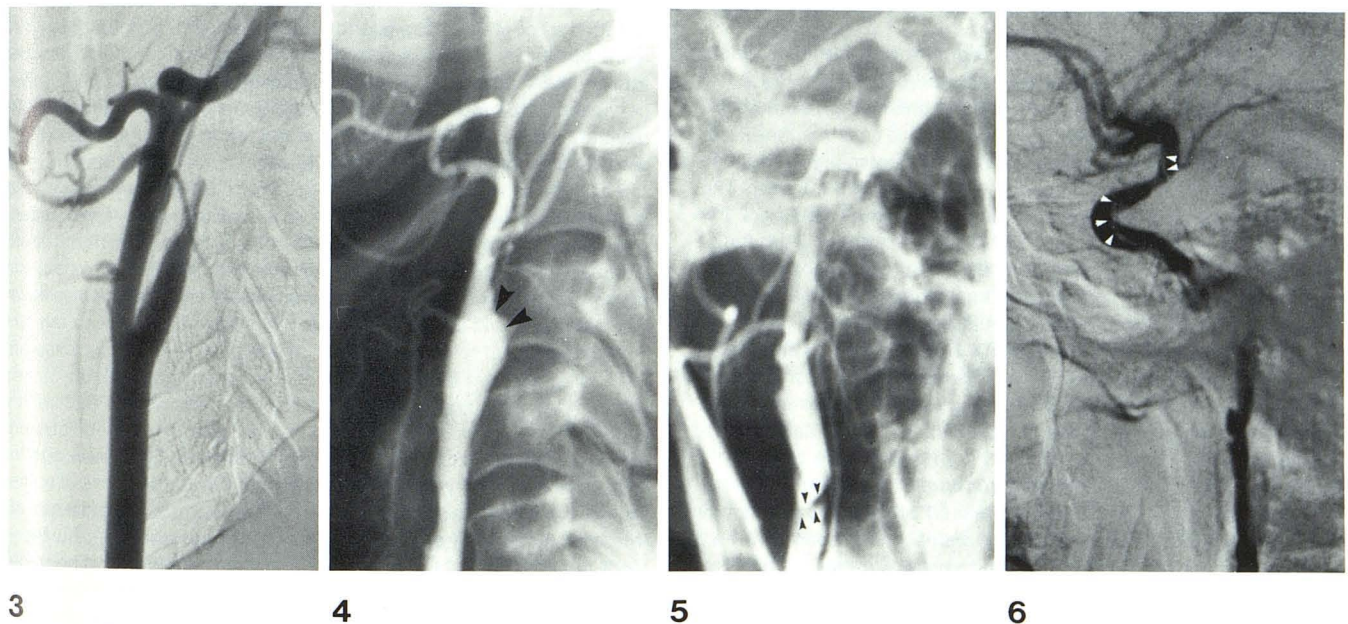
Fig. 2.—A, Left lateral carotid angiography in 40-year-old woman injured in automobile accident. Progressive intraluminal narrowing of ICA, tapering to extremely narrow diameter (*arrows*) just below carotid canal. Posteriorly situated traumatic aneurysm (*arrowhead*). Right carotid angiography demonstrated similar features of dissecting lesion in right side, but without showing traumatic aneurysm. B, Autopsy specimen of left ICA. Disruption of intima (*arrowheads*) at three levels and area of dissection (*arrows*). Traumatic aneurysm cannot be seen on this projection.

patients (figs. 1 and 2). Of these five patients, four had bilateral dissections but without total occlusion of the artery. The other patient had a dissection on one side and complete occlusion on the opposite side. One of the patients with bilateral dissecting aneurysms of the ICA exhibited an associated traumatic aneurysm on one side (fig. 2A). Fourteen patients had complete occlusion of one of their ICAs (figs. 3 and 4), and two patients showed evidence of dissection of one of their carotid arteries without total occlusion. In those cases in which complete occlusion of the cervical ICA was demonstrated, the site of occlusion occurred within the first 3 cm of the proximal ICA.

Results

Nine patients underwent surgery consisting of arteriotomy with thrombectomy or thromboendarterectomy. Of these nine patients, two died shortly after surgery. One patient improved without any residual neurologic deficit. Six patients improved slightly but still had significant residual neurologic deficits at the time of discharge, which persisted in follow-up examinations conducted up to 1 year postinjury. Five of the group of 12 patients who did not have any surgery died. Six were left with a moderate to severe neurologic deficit, and one patient recovered completely.

Autopsies were performed in five of the patients who died. (Four were from the group who did not have any surgery.) In all five cases, there was evidence of one or more intimal tears of the cervical ICA at the level of C1 and C2 (fig. 2B). Extensive intraluminal antemortem thrombus was present in all five cases, and three cases showed evidence of intramural dissection.



3 **4** **5** **6**

Fig. 3.—Left lateral carotid angiography in 17-year-old boy after motorcycle accident. Complete occlusion of internal carotid artery 3 cm distal to its origin.

Fig. 4.—Left carotid angiography in 57-year-old hypertensive and diabetic man hit on his neck by a chair. Complete occlusion of ICA at its origin (*arrowheads*). Atherosclerotic changes involve common carotid artery.

Fig. 5.—Anteroposterior view of right carotid angiography in 42-year-old man injured in automobile accident. Irregular narrowing of lumen of upper

cervical ICA due to dissecting lesion. Linear filling defect (*arrowheads*) within opacified vessel which represents intimal flap.

Fig. 6.—Lateral carotid angiography in 23-year-old man injured in automobile accident. Dissecting aneurysm of cervical segment of ICA. Characteristic irregularity and narrowing of lumen of vessel. Dissection extends distally into petrous and cavernous segments of artery. Spiral filling defect (*arrowheads*) within opacified vessel represents intima between false and true lumen of vessel.

Discussion

Traumatic ICA occlusion after blunt trauma was first reported by Verneuil over a hundred years ago [2]. Reports of posttraumatic changes in these vessels have been relatively frequent since the automobile age [3-7]. In the overwhelming majority of cases, trauma to the ICA is the result of penetrating injuries to the vessel. Nonpenetrating or blunt injuries of the cervical ICA account for only 3%-10% of all cervical carotid artery trauma [6, 7]. Nonpenetrating or blunt trauma to the cervical ICA may result in partial or complete thrombotic occlusion and/or aneurysm formation. These injuries are associated with a high incidence of severe neurologic complications and significant mortality [4].

Pathogenesis and Mechanisms of Injury

Nonpenetrating or blunt trauma to the cervical ICA may be caused by: (1) indirect trauma caused by hyperextension of the neck; (2) direct blunt trauma to the neck; (3) intraoral trauma; or (4) fractures through the base of the skull.

Closed head trauma, particularly in auto accidents, is often accompanied by forced hyperextension of the head and neck. The ICA is tensioned and stretched over the bony mass of the first and second cervical vertebrae, tearing the intima in one or more places [8-12]. In some cases, the inner layer of the media may also be torn. This is the probable mechanism of injury in most cases. In reviewing 52 cases in the literature, Yamada et al. [4] found an intimal tear in 62% of cases in which the pathology was definitely known.

Sudden stretching of the femoral artery has been shown experimentally to produce an intimal tear [13]. This is followed by the rolling up of the ruptured intimal layer by the flow of the blood. Thrombosis at the site of the intimal rupture results in occlusion of the artery. These changes are similar to the changes that occur in the carotid artery with hyperextension.

Lacerations, contusions, and abrasions on the forehead, face, and jaw were found in many of the reported cases [10, 12]. In 15 of our cases these signs indicated that hyperextension of the head occurred at the time of injury.

Contralateral rotation of the head at the time of injury may cause further stretching and compression of the ICA [9, 10, 12]. The combination of hyperextension and contralateral rotation of the head may be the mechanism involved in unilateral ICA trauma. However, the bilateral nature in five of our cases and in other reported cases [11, 14, 15] argues against the rotational element as a major factor in the production of the intimal tear.

Boldrey et al. [8] postulated fixation of the ICA to the lateral process of the atlas as a result of previous pharyngeal infections. This could increase the probability of injury at this level from sudden and severe hyperextension of the head.

One patient in our series who had a total occlusion of the right cervical ICA also had an associated fracture of the sternum. Hughes and Brownell [9] showed that depressed sternal fractures may tether the innominate artery so that the distal common carotid artery and ICA are more susceptible to sudden stress injuries. This may be a factor in some patients.

The intimal tear may act as a nidus for thrombus formation [12]. There may be antegrade and/or retrograde propagation of the thrombus. In most cases, total occlusion of the ICA is present [4, 5]. This occurred in 15 of our 21 patients. The thrombus may also serve as a source of emboli. The release of tiny emboli from the ICA thrombus into the cerebral circulation may result in neurologic deterioration.

Less often, a dissecting aneurysm may develop [10, 11, 16]. Passage of blood through the intimal tear into the media may result

in intramural dissection with a resultant narrowing and compromise of the vascular lumen. The resultant stenosis of the lumen may lead to thrombotic occlusion of the vessel and the complications of emboli. The tendency for thrombus formation is increased by the presence of perivascular edema or hematoma, vasospasm, hypotension, and the increased adhesiveness of platelets after major trauma [12].

The most common site of ICA injuries is the upper cervical internal carotid artery at the level of C1 and C2 [4, 10, 11]. A number of reports have suggested that the most frequent site of injury is the cervical ICA 1-3 cm above the bifurcation of the common carotid artery [12, 17]. However, the proximal propagation of the thrombus from the upper cervical ICA toward the bifurcation of the common carotid artery may lead to the erroneous impression that the site of arterial injury is nearer the bifurcation of the common carotid artery.

Cervical ICA aneurysms due to blunt trauma are extremely rare but may occur if there is disruption of the media and/or the adventitia, as well as the intima at the time of injury [11, 18]. Rupture of these aneurysms is rare, but complications secondary to embolism and thrombosis are relatively common.

Direct blows to the neck, particularly in older patients, are more likely to damage an atheromatous artery with dislodgment of the atheromatous plaque, which may form an obstructing flap with associated thrombus formation [4, 19]. Two patients in our series had external evidence of trauma to the neck on the affected side. One of these patients, aged 57 years, had a history of hypertension and diabetes. Angiography in this patient showed the occlusion of the cervical ICA on the side of the neck abrasion and demonstrated generalized atherosclerotic changes in the ipsilateral common carotid artery, the contralateral common carotid bifurcation, the aorta, and the femoral arteries (fig. 4). Even more rarely, blunt trauma to the neck may cause bleeding into the soft tissues around the carotid arteries, and this may produce extrinsic constriction and occlusion of the carotid artery [20].

Batzdorf et al. [11] showed that forces applied to the angle of a mandible that may or may not fracture the mandible itself can be transmitted to the ICA, or could compress the artery against the cervical spine and thus injure the artery. Two of our patients with unilateral total occlusion of the cervical ICA had fractured mandibles on the same side as the arterial occlusion.

Thrombosis of the ICA resulting from intraoral trauma to the peritonsillar area has been reported in children who have fallen while sucking on a hard object such as a lollipop, pencil, or stick [21, 22]. Also, basal skull fractures may contuse or tear the petrous portion of the internal carotid artery, which may in turn result in thrombosis [4, 17, 23].

Clinical Features of ICA Trauma

These lesions occur mainly in young patients. The mean age in our series was 28.2 years. The greater mobility of the cervical spine in younger individuals may account for the increased frequency of this type of injury in patients under 50 years of age [11]. Furthermore, in older patients, the vessels lose their elasticity and become tortuous and hardened. This makes the vessels more resistant to tearing and diminishes the possibility of a stretch injury to the ICA.

The clinical course and features of traumatic injury to the cervical ICA vary considerably from patient to patient, and the prognosis depends on the adequacy of collateral circulation and the presence or absence of embolic phenomena. Also, because of adequate collateral circulation from the contralateral carotid artery, total occlusion of a single carotid artery may be well tolerated in most young individuals. However, the patient may deteriorate neurologically if complicating factors such as hypoxia, hypotension, distal

propagation of the clot, and/or embolization into the intracranial vessels occur.

The development of symptoms and signs may follow a lucid interval, which can vary from 1 to more than 24 hr after the trauma. This in turn may simulate an epidural hematoma, which may direct the physician's attention to the cranium as the cause for the neurologic deficit. There are also instances where the latent period between the time of injury and the development of the clinical picture may extend to a few days or even a few weeks. The clinical picture may be aggravated by associated intracranial injuries. Bilateral cerebral edema was present in two of our patients.

The development of focal neurologic deficits with essentially no change in the level of consciousness suggests a posttraumatic vascular lesion and may be an important sign to differentiate a vascular injury from an intracranial mass lesion [7, 24]. Patients with traumatic intracranial mass lesions generally become obtunded by the time focal neurologic signs appear. (However, this was not a feature in our 10 patients who deteriorated after a latent period. In all 10 patients, mental blunting accompanied the development of focal neurologic deficits.)

Yamada and others [4, 5, 11, 25] have shown that there is a high incidence of morbidity and mortality if surgical treatment consisting of thromboendarterectomy is not prompt once neurologic signs have appeared. There was a 14% mortality in the operated group that he reviewed (21 cases), compared with a 55% mortality in the nonoperated group (31 cases). Among the survivors of the operated group, 10% were left with moderate or slight neurologic deficits, and 18% had no neurologic deficits. The survivors in the nonoperated group were so disabled as to be unable to work. The mortality and morbidity in our series are similar to those reported in other series [4, 5, 11, 25].

Radiographic Features of ICA Trauma

Initially, CT is relatively ineffective in the diagnosis of the sequelae of carotid artery trauma; however, delayed serial CT scans may demonstrate the evolution of infarction in these cases. In a study by French et al. [24], the earliest positive scan to show infarction occurred 11 hr after the onset of neurologic deficits.

Carotid angiography is the definitive radiologic procedure to demonstrate these lesions. Bilateral carotid angiography, to include both the neck and intracranial vessels, should be performed in all cases of suspected arterial trauma. Angiography will demonstrate the arterial injury and the sites of cerebral emboli, and will evaluate collateral circulation. If the clinical situation suggests posterior fossa involvement, vertebral angiography should also be performed. In most cases angiography will also demonstrate total occlusion of the cervical ICA 1–3 cm distal to the bifurcation of the ICA. In other cases, varying degrees of stenosis of the artery may be seen. The intimal tear or flap may be seen as a linear or spinal lucency within the opacified vessel (fig. 5).

The characteristic features of a dissecting aneurysm (consisting of marked irregularity and narrowing of the arterial lumen) may also be seen. If the false lumen of the dissection joins the normal lumen of the vessel at both ends of the lesion, angiography may opacify both the true and false lumina of the vessel. The intima and that part of the tunica media central to the dissection will appear as a spiral bandlike filling defect between the two lumina (fig. 6). A false aneurysm may be demonstrated typically in the upper cervical segment of the ICA, but this is rare.

REFERENCES

- Kishore PRS, Lipper MH. Craniocerebral trauma. In: Lee SH, Rao KCVG, eds. *Cranial computed tomography*. New York: McGraw-Hill, 1983:479–504
- Verneuil J. Contusions multiples, delire violent. Hemiplegie à droite signes de compression cerebrale. *Bull Acad Natl Med (Paris)* 1872;36:46–56
- Schneider RC, Lemmen LJ. Traumatic internal carotid artery thrombosis secondary to nonpenetrating injuries to the neck. *J Neurosurg* 1952;495–507
- Yamada S, Kindt GW, Youmans JR. Carotid artery occlusion due to nonpenetrating injury. *J Trauma* 1967;7:333–342
- Fleming JFR, Petrie D. Traumatic thrombosis of the internal carotid artery with delayed hemiplegia. *Can J Surg* 1968;11:166–172
- Unger SW, Tucker S, Mrdeza A, Wellons HA, Chandler JG. Carotid arterial trauma. *Surgery* 1980;87:477–487
- Krajewski LP, Hertzner NR. Blunt carotid artery trauma. *Ann Surg* 1980;191:341–346
- Boldrey E, Maass L, Miller E. The role of atlantoid compression in the etiology of internal carotid thrombosis. *J Neurosurg* 1956;13:127–139
- Hughes JT, Brownell B. Traumatic thrombosis of the internal carotid artery in the neck. *J Neurol Neurosurg Psychiatry* 1968;31:307–314
- New PJ, Momose KJ. Traumatic dissection of the internal carotid artery at the atlantoaxial level secondary to nonpenetrating injury. *Radiology* 1969;93:41–49
- Batzdorf U, Bentson JR, Machleder HI. Blunt trauma to the high cervical carotid artery. *Neurosurgery* 1979;5:195–201
- Burrows PE, Tubman DE. Multiple extracranial arterial lesions following closed craniocervical trauma. *J Trauma* 1981;21:497–498
- Bergan F. Traumatic intimal rupture of the popliteal artery with acute ischemia of the limb in cases with supracondylar fractures of the femur. *J Cardiovasc Surg (Torino)* 1963;4:300–302
- Friedenberg MJ, Lake P, Landau S. Bilateral incomplete traumatic occlusion of internal carotid arteries. *AJR* 1973;118:546–549
- Yashon D, Johnson AB, Jane JA. Bilateral internal carotid artery occlusion secondary to closed head injuries. *J Neurol Neurosurg Psychiatry* 1964;27:547–552
- Friedman WA, Day AL, Quisling RG, Syper GW, Rhoton AL. Cervical carotid dissecting aneurysms. *Neurosurgery* 1980;3:207–214
- Zilkha A. Traumatic occlusion of the internal carotid artery. *Radiology* 1970;97:543–548
- Busuttilli RW, Davidson RK, Foley KT, Livesay JT, Barker WF. Selective management of extracranial carotid arterial aneurysms. *Am J Surg* 1980;140:85–91
- Gurdjian ES, Hardy WG, Lindner DW, Thomas LM. Closed cervical cranial trauma associated with involvement of carotid and vertebral arteries. *J Neurosurg* 1963;20:418–427
- Mandelbaum I, Kalsbeck JE. Extrinsic compression of internal carotid artery. *Ann Surg* 1970;171:434–437
- Pitner SE. Carotid thrombosis due to intraoral trauma. *N Engl J Med* 1966;274:764–767
- Woodhurst WB, Robertson WD, Thompson GB. Carotid injury due to intraoral trauma: report and review of the literature. *Neurosurgery* 1980;6:559–563
- Janon EA. Traumatic changes in the internal carotid artery associated with basal skull fractures. *Radiology* 1970;96:55–59
- French BN, Cobb CA, Dublin AB. Cranial computed tomography in the diagnosis of symptomatic indirect trauma to the carotid artery. *Surg Neurol* 1981;15:257–267
- Dragon R, Saranchak H, Lakin P, Strauch G. Blunt injuries to the carotid and vertebral arteries. *Am J Surg* 1981;141:497–500