

# NMR Imaging in the Evaluation of Orbital Tumors

R. C. Hawkes,<sup>1</sup> G. N. Holland,<sup>1,2</sup> W. S. Moore,<sup>1</sup> S. Rizk,<sup>3</sup> B. S. Worthington,<sup>4</sup> and D. M. Kean<sup>4</sup>

The application of nuclear magnetic resonance (NMR) imaging to the diagnosis of orbital space-occupying lesions was studied in a group of 28 patients with a wide range of pathology. The NMR findings in six patients are illustrated. The results of the NMR scans are compared with the information that can be derived from conventional neuroradiologic procedures, including computed tomography. The value of the multiplanar facility of NMR is emphasized. It provides accurate volumetric information and establishes the precise topographical relationships of tumors to normal structures. The muscle cone and the optic nerve can be identified in the axial, coronal, and sagittal planes. Current limitations of the method and possible future developments to improve diagnostic precision are discussed.

Proton nuclear magnetic resonance (NMR) imaging has undergone a rapid evolution. Technical advances now allow production of images with quality rivaling that of the earlier generations of computed tomographic (CT) scanners. NMR also reveals tissue properties hitherto inaccessible to study. These capabilities, together with the total avoidance of ionizing radiation and the absence of any demonstrable hazard, make it an especially attractive imaging technique. The multiplanar facility is particularly valuable in the study of orbital disease, avoiding as it does the time and radiation dose penalty of reformatting techniques.

## Materials and Methods

Using a Picker resistive NMR unit, we studied a series of 24 patients who presented with unilateral proptosis, and four patients with intraocular tumors (melanoma). Among the 24 there were nine cases of dysthyroid proptosis, three of intraconal tumors, six of extraconal tumors, five of tumors invading the orbit, and one periorbital lesion. The scans were obtained in a steady-state free-precession sequence. Each section took 2 min to produce and was 1 cm thick.

## Results and Discussion

In NMR as in CT, orbital examinations display the orbits, extraocular muscles, and optic nerves contrasted against the high signal of the retrobulbar fat. Disadvantages of NMR imaging are that calcification is not seen, and that the margins of cortical bone are only

defined where it interfaces with soft tissue. In transverse sections in a normal subject looking left and right, the change in size of the medial and lateral recti and the movement of the optic nerve are clearly shown (fig. 1).

In a few patients, unilateral proptosis may be due to an intracranial cause. The first patient we examined by NMR had a large parasellar aneurysm, causing proptosis, which was associated with nerve III palsy and retrobulbar pain [1]. Occasionally, giant pituitary tumors may encroach on the orbit; we had one case where this was clearly depicted on coronal sections.

More frequently, the extraorbital cause of proptosis is to be found in the paranasal sinuses or nasopharynx, and is usually the result of tumor, infection, or mucocele. In a case of Ewing sarcoma arising from the ethmoidal sinuses the tumor encroachment on the orbit was demonstrated together with the consequent lateral dislocation of the orb.

Encroachment on the orbit by an intrinsic abnormality of the bone forming its boundaries is a rare cause of proptosis, but one in which NMR proved most useful. In a patient with fibrous dysplasia, gross bone thickening precluded an adequate examination of the orbital contents by CT; however, as the abnormal bone is practically invisible on NMR, a more satisfactory examination was therefore possible using this technique.

Another important practical problem is the identification of those patients with dysthyroid disease, the most common cause of proptosis. Although most cases can be recognized clinically and the diagnosis confirmed by immunologic tests, there is a minority for which diagnosis is unclear. These patients must be separated from those who have palpable tumors in the muscle cone causing axial proptosis. In NMR as in CT, the thickened rectus muscles are clearly shown in all three planes, but the coronal plane shows the extraocular muscles most completely, and is the most useful for distinguishing cases of dysthyroid proptosis from tumor-caused proptosis.

Occasionally (as in the patient shown in fig. 2) there is selective involvement of the muscles, and a discrepancy is visible between the enlarged inferior rectus muscle and the normal superior rectus muscle. Both NMR and CT can take the diagnosis beyond the indication of the presence of an orbital mass by identifying the site of origin of the mass, and, in particular, whether it is intraconal or extraconal. The shape and sharpness of the boundaries of the mass and its density provide important diagnostic features. Tumors associated with the optic nerve (both intrinsic and sheath tumors) can be clearly identified as arising from the nerve. For example, in our

<sup>1</sup>Department of Physics, University of Nottingham, England.

<sup>2</sup>Present address: Picker International, Highland Heights, OH 44143.

<sup>3</sup>Department of Ophthalmology, University of Nottingham, England.

<sup>4</sup>Department of Academic Radiology, Queen's Medical Centre, University of Nottingham, Nottingham, NG7 2UH, England. Address reprint requests to B. S. Worthington.

study an intraconal neurilemoma had a sharp image with well defined margins that closely matched its CT appearance. We have also observed in patients with papilledema a thickening of the optic nerve that parallels the features seen on CT.

Tumors and other expanding processes within the orbit present a more difficult challenge than those outside it, both in their demonstration and in their precise characterization. The role of CT in the primary investigation of these cases is firmly established [2-4]. Orbital hemangiomas are the most frequent benign tumors occurring in the orbit. Typically, they present as a solitary tumor with well defined margins, situated within the muscle cone lying inferolateral to the optic nerve (fig. 3).

The knowledge of other typical presentations can be extremely important when using NMR for diagnostic purposes. In figure 4, despite the high NMR density of the tumor, which rendered discrimination from the adjacent retrobulbar fat difficult, a correct diagnosis of a dermoid cyst was made, because these cysts are most commonly found in the superolateral quadrant of the orbit.

Metastatic disease should be considered in any elderly patient presenting with proptosis. Figure 5 shows the transverse NMR scan of a patient with an extraconal metastatic deposit in the superolateral quadrant of the orbit. We have only had the experience of one patient with dilated orbital veins (in a case of Mason-Wyburn syndrome) in which case there were an orbital angioma and a thalamic angioma. Dilated veins were seen as a group of tubular low-density structures in the upper part of the orbit.

The majority of intraocular tumors are adequately assessed by funduscopy with further evaluation with sonography. Where the

presence of a vitreous opacity makes examination of the fundus impossible, or where there is a retinal detachment, NMR scanning may be of assistance. The patient whose scan is shown in figure 6 had excision of the orb following diagnosis of melanoma. There was a close correspondence between the transverse NMR scan and the pathologic section.

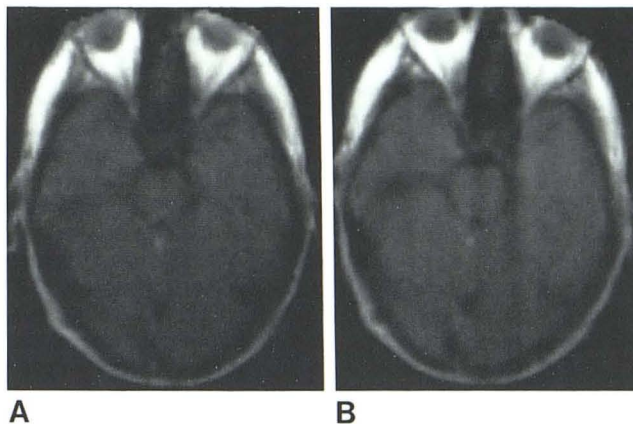


Fig. 1.—Axial transverse NMR scans of normal subject. A, Looking right. B, Looking left. Alteration in position of optic nerves and change in thickness of medial recti are well shown.

Fig. 2.—Parasagittal NMR scan in patient with dysthyroid proptosis. Selective involvement of inferior rectus muscle is shown.

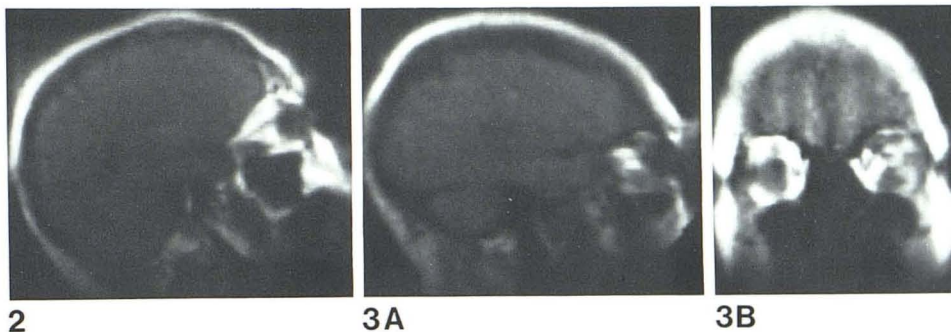
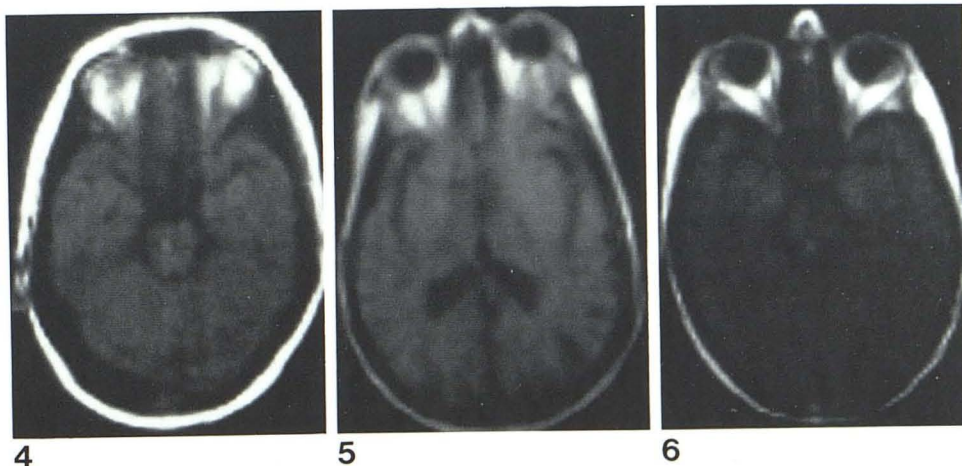


Fig. 3.—NMR scans with an intraconal hemangioma inferior to optic nerve. A, Parasagittal view. B, Coronal view.

Fig. 4.—Axial transverse NMR scan in patient with dermoid cyst in superolateral quadrant of left orbit. Tumor gives high signal, which makes it difficult to distinguish from retrobulbar fat. Bulging of posterolateral wall of orbit is just discernible.

Fig. 5.—Axial transverse NMR scan in patient with metastatic deposit in superolateral quadrant of left orbit.

Fig. 6.—Axial transverse NMR scan showing melanoma in posterolateral quadrant of left orb.



### Conclusions

We believe that with thinner sections, high-resolution scanning, and the use of spin sequences based on individual parameters, NMR imaging will come to rival the diagnostic capability of CT in orbital disease. The multiplanar facility and avoidance of ionizing radiation may then make it the preferred method of primary investigation.

### REFERENCES

1. Hawkes RC, Holland GN, Moore WS, Worthington BS. Nuclear magnetic resonance (NMR) tomography of the brain: a preliminary assessment with demonstration of pathology. *J Comput Assist Tomogr* **1980**;5:577-586
2. Ambrose JAE, Lloyd GAS, Wright JE. A preliminary evaluation of fine matrix computerized tomography in the diagnosis of orbital space occupying lesions. *Br J Radiol* **1974**;47:747-751
3. Lloyd, GAS. The impact of CT scanning and ultrasonography on orbital diagnosis. *Clin Radiol* **1977**;28:583-593
4. Forbes GS, Earnest F, Waller RR. Computed tomography of orbital tumors, including late generation scanning techniques. *Radiology* **1982**;142:387-394