

Intradural Metastases of Chordoma

George Krol,¹ Gordon Sze,¹ Ehud Arbit,² Ralph Marcove,³ and Narayan Sundaresan⁴

Metastatic spread of chordoma usually occurs in an advanced stage of the disease. The common sites of metastases are lungs, bones, skin, and lymph nodes. A review of the literature revealed no previous reports of chordoma metastasizing to the subarachnoid space from a distant primary focus.

Case Reports

Case 1

A 59-year-old man with sacral chordoma had several resections of locally recurring disease during a 6-year period following diagnosis. The present hospital admission of the patient, now 65, was prompted by several weeks of pain in the right buttock and progressive difficulty in walking. A tender soft-tissue mass in the right buttock area, weakness and muscle atrophy of both lower extremities, and decreased sensation in the distribution of the fourth lumbar root bilaterally were noted on physical examination. CT showed a large posterior pelvic mass with destruction of the sacrum extending up to the L4 vertebra. MR revealed a sacral mass, confined to the pelvis and lower lumbar spine, but no abnormalities above the L4 level. Multiple intradural nodular lesions were demonstrated in the lumbar sac on metrizamide myelography (Fig. 1).

A palliative surgical procedure and laminectomy up to the L1 level were carried out. The main tumor mass was debulked and multiple intradural tumor nodules were resected from the lumbar arachnoid sac. Pathology revealed chordoma. The patient's condition improved significantly after surgery, but he returned with similar symptoms 6 months later.

Case 2

A 41-year-old man was operated on for clival chordoma. At surgery, the tumor was noted to invade the dura. The following year, the tumor recurred in the cervical spine and resection was carried out. The present admission of the patient, now 43, was prompted by progressive difficulty in walking, noticed over a period of several months. On examination, there was weakness of the lower extremities and a sensory deficit in the distribution of L2–L4 roots bilaterally. Myelography demonstrated several nodular filling defects within the lumbar subarachnoid space. There was progression of the process

on follow-up examination 5 months later, with an increase in the number and size of the nodules. MR of the lumbar spine revealed nodular areas of abnormal intensity within the canal (Fig. 2).

Discussion

Chordomas constitute approximately 2% of all malignant bone tumors [1]. They originate from remnants of the notochord and occur most commonly in older males, with predominant involvement of the sacrum (50%), base of skull (35%), and vertebrae (15%) [2]. Very aggressive locally [3], these lesions have a high rate of recurrence that seems to be related to the completeness of resection (up to 65%) [4]. Metastatic potential of these tumors is considered to be low. The first case of distant metastases of chordoma (to the muscles and scapula) was mentioned by Stewart in 1922 [5], 65 years after the tumor was described as a separate entity by Luschka in 1857 [6]. A number of cases have been reported since then, with an incidence of 3–43% reported [2, 7–11]. Metastatic lesions most commonly involve lungs, lymph nodes, liver, and bones [7, 8]. Involvement of heart and pericardium, muscle, skin, and subcutaneous tissue is also relatively common [7, 11, 12]. Cases with generalized spread constitute less than 10% of all metastases. The central location of chordomas accounts for a high incidence of extension of these lesions into the canal. The epidural space is typically involved [13, 14], and the dura is also commonly invaded [15].

Metastatic seeding to the leptomeninges from chordomas located at a remote site has not been described. A brief note mentions one case of "extensive seeding of the spinal cord" in a series reported by Firooznia et al. [16], and two cases of tumor "filling the spinal canal" are reported by Fox and associates [17]. Although subarachnoid lesions in our patients were distant from the primary foci, invasion of the dura was present in both. The mode of dissemination of the tumor into the subarachnoid space was not clear, but it probably was not hematogenous. Detachment of tumor cells after the transgression of dura is a more likely possibility.

Received May 13, 1987; accepted after revision August 9, 1987.

¹ Department of Medical Imaging, Memorial Sloan-Kettering Cancer Center, 1275 York Ave., New York, NY 10021. Address reprint requests to G. Krol.

² Department of Neurosurgery, Memorial Sloan-Kettering Cancer Center, New York, NY 10021.

³ Department of Orthopedic Surgery, Memorial Sloan-Kettering Cancer Center, New York, NY 10021.

⁴ Department of Neurosurgery, St. Luke's Medical Center, New York, NY 10025.

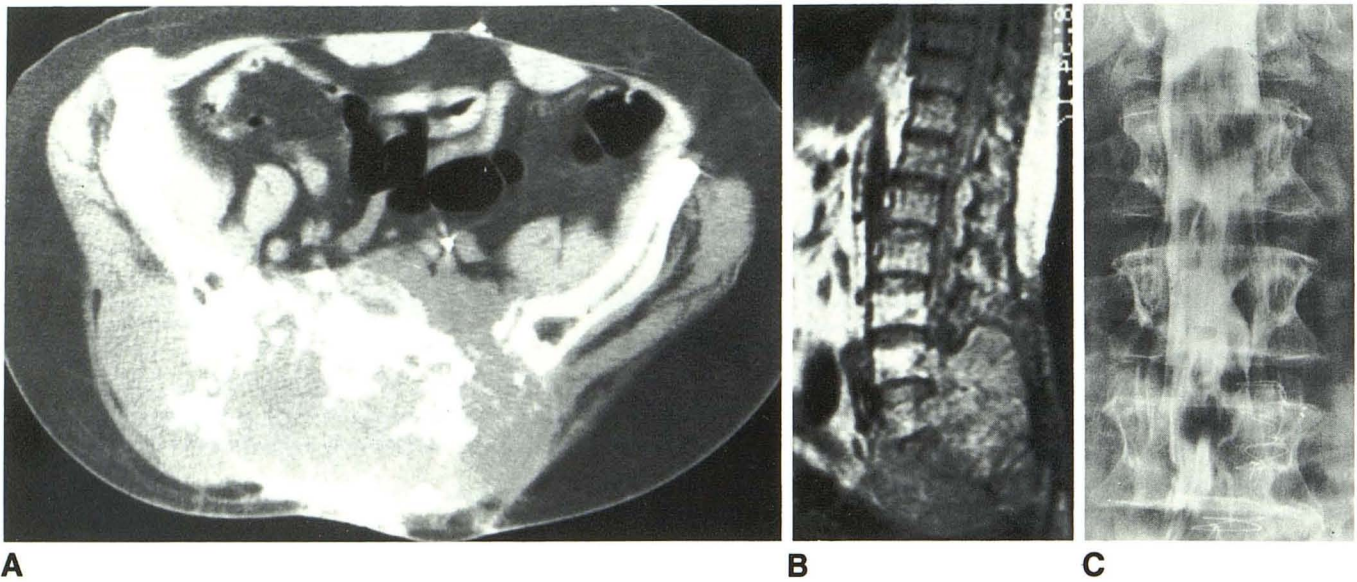


Fig. 1.—Case 1. Recurrent sacral chordoma.
A, Axial CT section reveals destruction of sacrum and a large soft-tissue mass.
B, Sagittal MR image, 1600/32 (TR/TE), of lower lumbosacral spine. The tumor is well outlined along the periphery. There is no apparent abnormality of spinal canal above L4 vertebra.
C, Metrizamide myelogram demonstrates multiple tumor nodules on frontal projection.

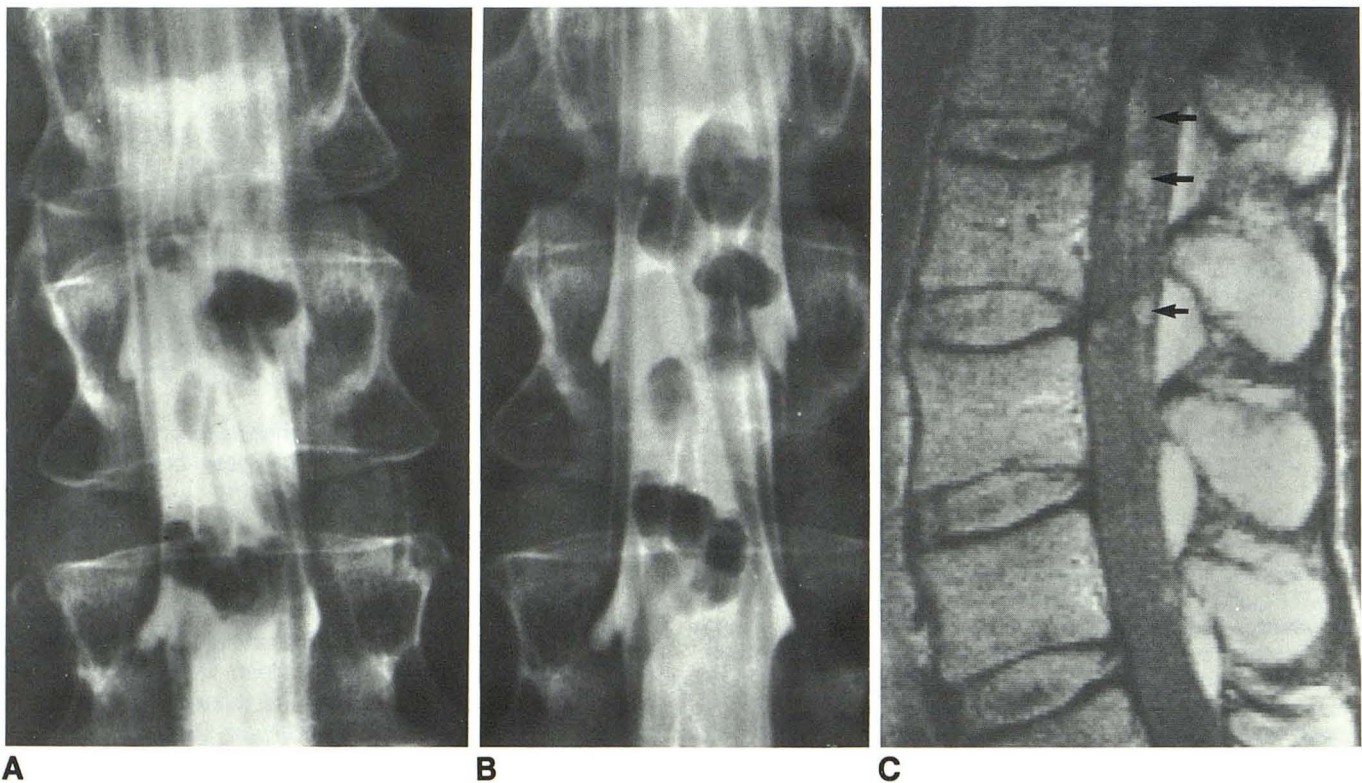


Fig. 2.—Case 2. Metastatic chordoma, clival origin.
A, Initial metrizamide myelogram reveals several nodular filling defects within upper lumbar subarachnoid space.
B, Follow-up myelogram. Note increase in size and number of lesions.
C, Sagittal spin-echo MR image, 1000/40 (TR/TE), of lower thoracic upper lumbar spine. Discrete nodular areas of hyperintensity are seen within canal (arrows).

Radiographically, chordomas are best evaluated by CT and MR. Destructive bone changes accompanied by a large soft-tissue mass are characteristic of the primary lesion [13, 14, 18].

The radiographic diagnosis of tumor involvement of meninges is usually made on myelography. Multiple, nodular, or irregular filling defects; longitudinal striations; and various degrees of obstruction of the flow may be demonstrated [19]. However, the myelographic appearance of neoplastic infiltration of the membranes is not specific, with many tumor types sharing the same features [19, 20]. Subarachnoid lesions may be seen on MR as discrete areas of increased intensity; however, the sensitivity of MR in detecting subarachnoid metastases is low [21]. Even high-degree obstruction of the spinal canal due to subarachnoid space involvement may not be appreciated by MR [21, 22]. The ability to depict these lesions by MR at present seems to be related to the resolution capability of the equipment and to the selection of imaging sequences. The subarachnoid lesions may be obscured on both T1- and T2-weighted images because of loss of contrast between the lesions and CSF [23]. Sequences with intermediate TR/TE intervals may be most suitable for the detection of the subarachnoid nodules, although the subject requires further investigation.

REFERENCES

- Dahlin DC. *Bone tumors: general aspects and data on 6221 cases*, 3rd ed. Springfield: Charles C Thomas, 1978:329-343
- Higinbotham N, Philips R, Farr H, Hustu O. Chordoma—thirty-five-year study at Memorial Hospital. *Cancer* 1967;11(20):1141-1149
- Dahlin DC, McCarthy CS. Chordoma: a study of fifty-nine cases. *Cancer* 1952;5:1170-1178
- Keiser T, Pritchard D, Unni K. Clinicopathologic study of sacro-coccygeal chordoma. *Cancer* 1984;53:2574-2578
- Stewart MJ. Malignant sacrococcygeal chordoma. *J Pathol* 1922;25:40
- Friedman I, Harrison P, Bird ES. The fine structures of chordoma with particular reference to the physaliphorous cell. *J Clin Pathol* 1962;15:116-125
- Chambers PW, Schwimm CP. Chordoma—a clinicopathologic study of metastases. *Am J Clin Pathol* 1979;72(5):765-776
- Gray SW, Sighabhandi B, Smith RA, et al. Sacrococcygeal chordoma: report of a case and review of literature. *Surgery* 1975;78:573-582
- Gentil F, Coley BL. Sacrococcygeal chordoma. *Ann Surg* 1948;127:432-455
- Sundaresan N, Galicich J, Chu F, Huvos A. Spinal chordomas. *J Neurosurg* 1979;50:312-319
- Littman L. Sacrococcygeal chordoma—review of 168 cases. *Ann Surg* 1953;137:80-90
- Yarom R, Horn Y. Sacrococcygeal chordoma with unusual metastases. *Cancer* 1970;25:659-662
- Krol G, Sundaresan N, Deck M. Computed tomography of axial chordomas. *J Comput Assist Tomogr* 1983;7(2):286-289
- Sundaresan N, Galicich J, Chu F, Huvos A. Spinal chordomas. *J Neurosurg* 1979;50:312-319
- Popper J, King A. Chordoma: experience with thirteen cases. *J Neurosurg* 1952;9:139-163
- Firooznia H, Pinto R, Lin J. Chordoma: radiologic evaluation of 20 cases. *AJR* 1976;127:797-805
- Fox J, Batsakis J, Owano L. Unusual manifestations of chordoma. *J Bone Joint Surg [Am]* 1968;50:1618-1628
- Rosenthal D, Scott J, Mankin H, et al. Sacrococcygeal chordoma: magnetic resonance imaging and computed tomography. *AJR* 1985;145:143-147
- Kim KS, Ho SU, Weinberg PE, Lee C. Spinal leptomeningeal infiltration by systemic cancer: myelographic features. *AJR* 1982;139:361-365
- Stanley P, Senac M, Segall H. Intraspinal seeding from intracranial tumors in children. *AJR* 1985;144:157-161
- Heier L, Krol G, Sundaresan N, et al. MRI in the evaluation of epidural lesions: comparison with myelography. *Radiology* 1985;15:150 (abstr)
- Krol G, Heier L, Becker R, et al. MRI features of high degree and complete block of the spinal canal. Presented at the XIII Symposium Neuroradiologicum, Stockholm, June 1986
- Barloon T, Yuh W, Yang C, et al. Spinal subarachnoid tumor seeding from intracranial metastases: MR findings. *J Comput Assist Tomogr* 1987;11(2):242-244