

# Radiodense Dural Sinuses: New CT Sign in Patients at Risk for Hypoxic Insult

M. D. Nelson, Jr.<sup>1</sup>  
J. R. Thompson  
D. B. Hinshaw, Jr.  
A. N. Hasso

The observation of apparent dural sinus opacification in a polycythemic patient with cerebral infarction prompted a review of 300 computed tomographic scans for the significance of dense dural sinuses. Fifteen patients, including 11 neonates, were identified; each of them had dense dural sinuses and elevated hematocrit or red blood cell indices or both. With only one exception, computed tomography also showed various low attenuation parenchymal abnormalities. A typical cerebral infarction pattern was seen in six and parenchymal hemorrhage in one. Nonthrombotic dural sinus opacification is a sign of increased blood viscosity in patients with congenital heart disease, hemoconcentration states, polycythemia of the newborn, and polycythemia rubra vera. These patients are at high risk for hypoxic cerebral insult, which can be detected by cranial computed tomography.

Polycythemic blood may be expected to show computed tomographic (CT) attenuation values 15–20 Hounsfield units (H) above brain attenuation, according to New and Aronow [1], who showed a linear relation between x-ray attenuation and hemoglobin concentration. Twenty Hounsfield units represents a 2% attenuation difference, which is well above the low contrast density resolution of most CT scanners. We observed striking dural sinus visualization in a 5-day-old infant who was incorrectly thought to have received intravenous contrast material but was discovered to have a hematocrit of 61%. Hyperviscosity resulting from polycythemia has been reported to cause cerebral vascular complications including hydranencephaly, parenchymal hemorrhage, and infarction [2–4]. This prompted a retrospective study of patients with nonenhanced cranial CT findings of dense dural sinuses and of patients with increased blood viscosity in order to determine the diagnostic validity and the clinical significance of the radiodense dural sinus.

Four conditions were chosen in which patients appeared to be at risk: neonatal idiopathic polycythemia; polycythemia rubra vera; secondary polycythemia with congenital heart disease; and chronic obstructive pulmonary disease.

Dense dural sinuses were suspected if the torcular Herophili and sagittal and lateral sinuses were abnormally dense on different scan sections. With hematocrits above 60%, the great vein of Galen, internal cerebral veins, circle of Willis, and main branches of the internal carotid artery have also been observed to be radiodense as if "enhanced."

## Materials and Methods

The cranial CT scans of neonates studied during a 4 year period were reviewed for dense dural sinuses and cerebral hypoxic insult. The scans of patients with the diagnosis of either congenital heart disease or polycythemia (primary or secondary) were also reviewed, and their hematocrit and blood indices (mean corpuscular volume, mean corpuscular hemoglobin, and mean corpuscular hemoglobin concentration) were obtained from clinical records. Each scan was given an arbitrary value of 1+ to 4+ according to the

Received March 19, 1981; accepted after revision May 19, 1981.

Presented at the annual meeting of the American Society of Neuroradiology, Chicago, IL, April 1981.

<sup>1</sup> All authors: Department of Radiation Sciences, Section of Neuroradiology, Loma Linda University Medical Center, Loma Linda, CA 92350. Address reprint requests to J. R. Thompson.

*AJNR* 2:545–548, November/December 1981  
0195–6108/81/0206–0545 \$00.00  
© American Roentgen Ray Society



TABLE 1: Dense Dural Sinuses: Laboratory and CT Findings

Case No.	Age	HCT/HGB	MCV	MCH	MCHC	Dural sinus	Arteries	Brain Insult/Clinical Diagnosis
1	5 days	61.6/20.6	110	36.9	33.7	4+	1+	Infarction/seizure disorder
2	16 days	60.1/19.8	121	39.6	33.0	3+	...	Central low attenuation/meconium aspiration
3	15 months	59.1/19.7	77	27.9	34.2	4+	3+	Infarction/congenital heart lesion
4	2 days	57.0/19.1	112	27.5	33.3	3+	...	Diffuse bilateral cerebral infarction in utero
5	2 days	56.9/18.8	121	39.5	32.9	3+	...	Patchy low attenuation/PDA
6	19 days	54.6/18.5	112	39	35.1	1-2+	...	Infarction/dehydration, NEC
7	1 day	54.2/18.4	111	37.6	33.9	2+	...	Central and diffuse low attenuation/meconium aspiration
8	2 weeks	52.4/17.7	107	35.9	33.7	1+	...	Central low attenuation
9	82 years	50.5/17.1	98	34.8	30.7	2+	...	Infarction/severe COPD
10	3 days	50.0/17.6	111	38.3	34.7	2-3+	...	Subependymal hemorrhage, patchy low attenuation/septic, premature
11	78 years	49.0/17.2	71	27.8	32.3	2+	...	Infarction/VSD with CHF
12	60 years	48.1/16.9	100	36.7	34.9	2+	...	Lung CA
13	24 days	48.0/16.6	108	37.1	34.4	2+	...	Infarction/high flow cranial AV/malformation
14	24 days	43.1/14.8	106	36.6	34.2	2+	...	Central low attenuation/hyperbilirubinemia
15	3 days	41.6/13.8	102	34.0	34.4	2+	...	Patchy low attenuation/premature, RDS

Note.—Normal laboratory values are: hematocrit (HCT), 42%–52% (adult), 37%–47% (neonate); hemoglobin (HGB), 14–16.5 g/dl; mean corpuscular volume (MCV), 85–97 fl; mean corpuscular hemoglobin (MCH), 27–31 pg; and mean corpuscular hemoglobin concentration, 32–36 g/dl. PDA = patent ductus arteriosus, NEC = necrotizing enterocolitis, COPD = chronic obstructive pulmonary disease, VSD = ventricular septal defect, CHF = chronic heart failure, CA = carcinoma, AV = arteriovenous, and RDS = respiratory distress syndrome. Arbitrary grades of 1+–4+ were assigned to CT scans based on the relative intensity of the dural sinuses.

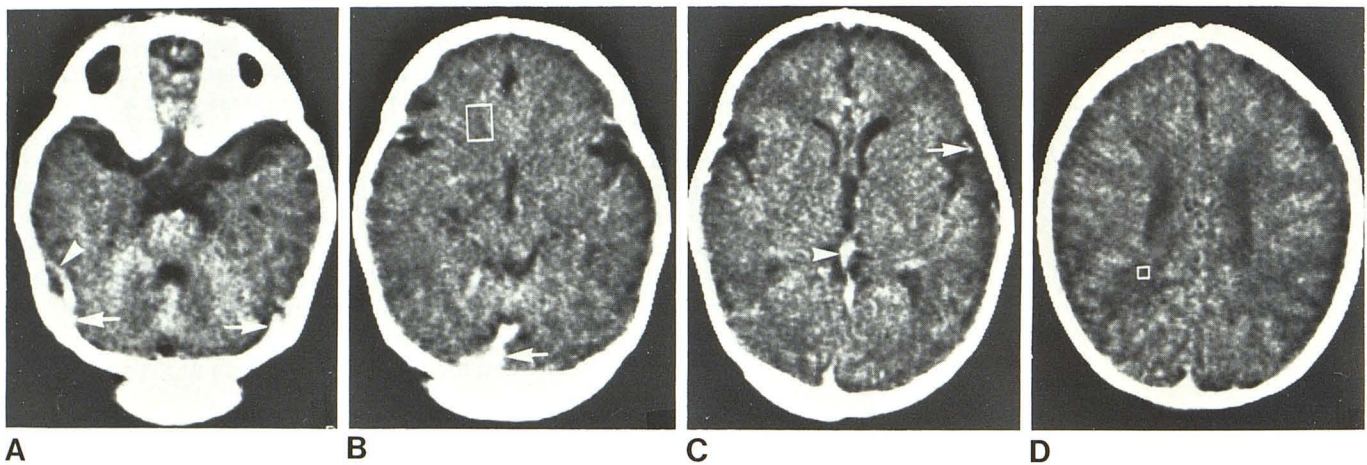


Fig. 1.—Case 1. A, Lateral sinuses (arrows) and vein of Labbé (arrowhead) radiodense without contrast material. B, Radiodense torcular Herophili (arrow) reduced brain attenuation to 23 H (region of interest box). C, Vein of Galen (arrowhead) and middle cerebral artery branch (arrow). D, Radiodense superior sagittal sinus. Central infarction with attenuation 6 H below average brain.

relative intensity of the dural sinuses. To serve as a control, the charts of 30 randomly selected patients without dural sinus opacification were reviewed for comparison of the blood factors.

**Results**

A total of 300 nonenhanced cranial CT scans were reviewed. We identified 15 with dense dural sinuses. They are

listed in table 1 according to hematocrit, blood indices, and the presence or absence of hypoxic insult. The hematocrits ranged from 41.0% to 61.6% and all patients had elevated mean corpuscular volume and hemoglobin with normal hemoglobin concentration indices. Cerebral infarction was seen in seven patients, parenchymal hemorrhage in one, developing hydranencephaly in one, and patchy or central low attenuation in seven neonates. Four of the patients died. Autopsies were done on two and showed no evidence of



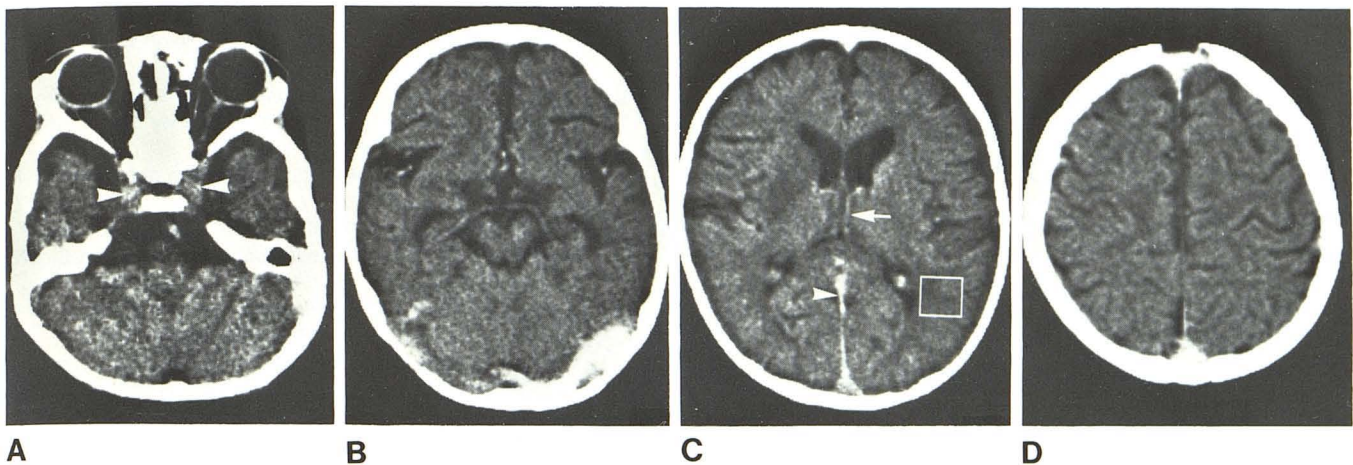


Fig. 2.—Case 3. **A**, Radiodense cavernous sinuses (*arrowheads*). **B**, Marked radiodensity of lateral sinuses and major cerebral arteries. **C**, Straight

sinus (*arrowhead*) and internal cerebral veins (*arrow*). Infarction of right basal ganglia. **D**, Radiodense superior sagittal sinus.

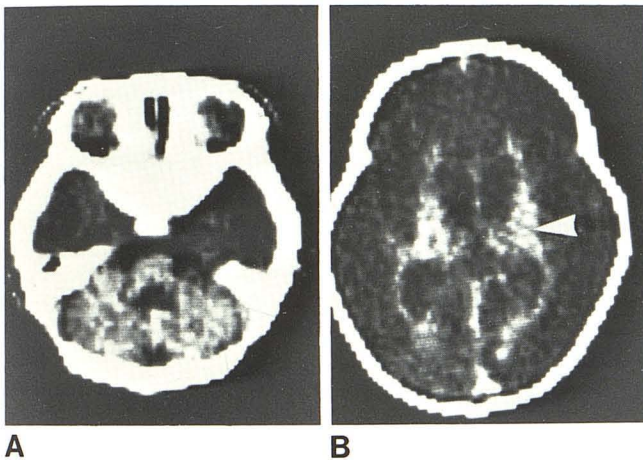


Fig. 3.—Case 4. Diffuse cerebral infarction. Cerebellum and periventricular brain matter (*arrowhead*) of more normal attenuation.

venous sinus thrombosis, an alternate explanation for the density of the dural sinuses.

The hematocrit in the 30 patients without the radiodense dural sinus sign was 25.2%–52% (mean, 38.3%). The mean corpuscular volume and hemoglobin indices were elevated in eight cases.

### Discussion

The appearance of radiodense dural sinuses is a reflection of the increased attenuation of the patient's blood within the venous sinuses of the brain. This was verified in our study as the sinuses became increasingly dense with progressively elevated hematocrit levels. The four patients (cases 1–4) with hematocrit values above 57% showed dramatic visualization of the venous sinuses and major arteries at the base of the brain. Two are shown in figures 1 and 2. Three of the four cases had radiographically

significant ischemic cerebral damage. The other 11 patients (cases 5–15) had mid to high normal-range hematocrits with markedly elevated mean corpuscular volumes and hemoglobins. The sinuses were not as dense as in the first four cases, reflecting the lower hemoglobin concentrations. All these patients had macrocytic red blood cells that had lost their deformability. Newborn erythrocytes have been found to be intrinsically less deformable than adult erythrocytes [5]. These factors may contribute significantly to increasing the viscosity of the blood [6]. Indeed, five of the 11 cases had CT evidence of infarction or hemorrhage, complications that could have resulted from unsuspected hyperviscosity.

On initial inspection, several disease processes may mimic the dense dural sinus. Clotted blood also results in increased attenuation; therefore, dural sinus thrombosis must be considered [1]. Clinically, these patients show signs of increased intracranial pressure. Obstruction of the cerebral veins leads to hypoxia of cerebral tissue and frequently hemorrhage [7]. Sinus thrombosis may result from hyperviscosity and numerous other causes, and differentiation requires careful clinical evaluation.

Subarachnoid hemorrhage in the posterior fossa or occipital areas of neonates may simulate opacification of the torcular Herophili and lateral sinus. Differentiation can usually be made by observing the normal sagittal and sigmoid sinuses. In some neonates with small head size, the vasculature is normal but may appear dense when the cerebral tissue is of low attenuation.

Patients with dense sinuses often have hypoxic complications. A direct cause and effect relationship is difficult to document because of concurrent processes. However, as the blood viscosity increases, sludging occurs, causing impairment of tissue oxygenation and a tendency to form microthrombi [8–10]. This may be an important factor in the genesis of cerebral infarction, parenchymal hemorrhage, venous thrombosis, and hydranencephaly, which are frequent complications in neonates. Of our 15 cases, 14 may be interpreted to show evidence of ischemic insult (table 1),

one with developing encephalomalacia due to diffuse infarction (fig. 3). We suspect that the CT appearance of central, patchy low attenuation represents some degree of irreversible cellular damage, but this has not been documented by us or by others. The seven patients with infarction listed in table 1 demonstrate the usually accepted CT criteria for that diagnosis.

Increased dural sinus radiodensity on CT is a sign of increased blood viscosity in patients with hyperviscous states, usually resulting from primary or secondary polycythemia. These patients are at high risk for hypoxemic cerebral insult, which can be detected by cranial CT.

#### REFERENCES

1. New FJ, Aronow S. Attenuation measurements of whole blood and blood fractions in computed tomography. *Radiology* **1976**;121:635-640
2. Henriksson P. Hyperviscosity of the blood and haemostasis in the newborn infant. *Acta Paediatr Scand* **1979**;68:701-704
3. Nelson D, Fazekas JF. Cerebral blood flow in polycythemia vera. *Arch Intern Med* **1956**;98:328-331
4. Koffler H, Keenan WJ, Sutherland JM. Hydranencephaly following elevated hematocrit values in a newly born infant. *Pediatrics* **1974**;54:770-772
5. Gross GP, Hathaway WE. Fetal erythrocyte deformability. *Pediatr Res* **1972**;6:593-599
6. Schmid-Schoenbein H, Wells R, Goldstone J. Influence of deformability of human red cells upon blood viscosity. *Circ Res* **1969**;25:131-143
7. Taveras JM, Wood EH. *Diagnostic neuroradiology*, 2d ed. Baltimore, MD: Williams & Wilkins, **1976**:909-911
8. Ditenfass L. Blood viscosity, internal fluidity of the red cell, dynamic coagulation and the critical capillary radius as factors in the physiology and pathology of the circulation and microcirculation (review). *Med J Aust* **1968**;1:688-696
9. Gross GP, Hathaway WE, McGaughey HR. Hyperviscosity in the neonate. *J Pediatr* **1973**;82:1004-1012
10. Gahi RA, Muster AJ, Cole RB, Paul MH. Neonatal polycythemia with transient cyanosis and cardiorespiratory abnormalities. *J Pediatr* **1966**;69:1063-1072