

# Carotid-Cavernous Fistulas: Intraarterial Treatment

Alex Berenstein<sup>1</sup>  
Irvin I. Kricheff<sup>1</sup>  
Joseph Ransohoff<sup>2</sup>

The intraarterial treatment of carotid-cavernous fistulas can be carried out rationally by considering a number of different factors. These include the site of the fistula, its size, its supply, its clinical presentation, associated vascular injuries, and the tolerance to carotid occlusion by a direct intraarterial balloon test. Careful attention to these features and familiarity with a variety of catheter systems, detachable balloons, and tissue adhesives will allow the operator to select the best treatment for each patient. Seven patients are described to illustrate these considerations.

Carotid-cavernous fistulas usually originate from the cavernous segment of the internal carotid artery and rarely from the external carotid artery or from the vertebrobasilar circulation [1, 2]. The intravascular treatment of this difficult therapeutic problem has received increased acceptance and specific techniques have been reported with encouraging results [3-8]. We used different embolization techniques to successfully treat these lesions by an intravascular approach, placing detachable balloons in the fistula with preservation of the arterial flow, balloon catheters at the fistula site without preservation of the arterial flow, and the injection of isobutyl-2 cyanoacrylate (IBCA) (Ethicon, Sommerville, N. J.), a tissue adhesive, in lesions involving the external carotid artery. The technique selected depended on the anatomic factors such as the site of the fistula, its vascular supply, associated vascular injuries, and the clinical presentation. The operator must be skilled in the use of various transarterial techniques so that he may choose the appropriate catheter, balloon, and/or tissue adhesive for the specific problem.

## Subjects and Methods

In seven patients, clinical, anatomic, and hemodynamic features of the fistulas dictated the use of different therapeutic techniques or modifications. Five of the seven were successfully treated without complications by the intraarterial approach. In one (case 1) the fistula could not be reached by the balloon but a trapping procedure was successful. A second patient who did not tolerate arterial occlusion by the balloon required occlusion of the internal and external carotid arteries to effect a clinical cure. No complications occurred after the intraarterial approach. Blindness developed in one patient treated by the trapping procedure.

Received September 28, 1979; accepted after revision March 6, 1980

Presented at the annual meeting of the American Society of Neuroradiology, Toronto, Canada, March 1979.

<sup>1</sup> Department of Radiology, Section of Neuro-radiology, Bellevue Hospital, and New York University Medical Center, 550 First Ave., New York, NY 10016. Address reprint requests to A. Berenstein.

<sup>2</sup> Department of Neurosurgery, Bellevue Hospital, and New York University Medical Center, New York, NY 10016.

*AJNR* 1:449-457, September/October 1980  
0195-6108/80/0104-0449 \$00.00  
© American Roentgen Ray Society



## Case Reports

### Case 1

A 67-year-old woman sustained a right occipito-temporal fracture after falling backwards in her home. She lost consciousness for 6 hr, after which she was confused and amnesic and 6 weeks later she developed horizontal diplopia. Admission physical examination revealed episcleral and conjunctival injection bilaterally, worse on the right. A bruit was heard over both eyes, louder on the right. A right sixth nerve palsy was present.

Angiography demonstrated a right carotid-cavernous fistula with drainage into the superior and inferior divisions of the right ophthalmic vein and cross-filling to the left through the anterior coronary sinus and into the left ophthalmic vein. Marked atheromatous changes were in the cavernous and supraclinoid segments of the internal carotid artery. The Matas test during angiography showed good tolerance to manual right carotid compression and good cross-filling from left to right.

*First operation.* The right common, external, and internal carotid arteries were exposed in the neck. A 3 French Fogarty balloon catheter (Edwards Labs, Santa Ana, Cal.) was introduced into the internal carotid lumen via an arteriotomy. The catheter was manipulated until its tip stopped at the proximal part of the cavernous carotid artery about 11 mm proximal to the fistula. Carotid artery tortuosity prevented further advance and correct placement of the balloon at the fistula site. The balloon was inflated with Conray 60. The bruit decreased over the right eye and disappeared over the left eye. The balloon catheter was left in that position. Both the internal carotid and external carotid arteries were ligated in the neck. The catheter at its proximal end was bent, clipped, and anchored to the carotid sheath. The patient tolerated this procedure well. In the postoperative period, there was an initial improvement of the eye symptoms; however, at a 3-week follow-up examination, all the right eye findings had recurred. The balloon deflated spontaneously after 9 days.

*Second operation.* The trapping of the right carotid artery was completed 5 months later. The intracranial carotid artery was hard and atherosclerotic and multiple adhesions were present at the trauma site. The artery was clipped between the posterior communicating artery and the ophthalmic artery, effectively isolating the internal carotid artery. The bruit and episcleral injection disappeared; however, the patient lost central vision in the right eye. Her vision was unimproved 1½ years later, but no signs or symptoms of the fistula were present.

*Comment.* This case represents our first attempt to treat carotid-cavernous fistulas through an intravascular approach. At that time the only balloon catheter available to us that could accomplish closure of a fistula was a single-lumen small-diameter Fogarty 3 French endarterectomy catheter [7]. This case illustrates the limitations of this relatively rigid catheter in attempting to negotiate tortuous vessels and the necessity for other catheter designs that could deal with this problem. Since the bruit decreased on the ipsilateral side and disappeared on the contralateral side when the balloon was inflated, we decided to leave the inflated balloon in place since it might result in amelioration of symptoms. Intracranial trapping of the internal carotid artery could still be done if the fistula persisted or recurred, as it did in this case. The loss of central vision was due to isolation of the ophthalmic artery in the trapping procedure combined with the external carotid artery ligation in the neck. These occlusions prevented collateralization to the fistula through the inferolateral trunk of the cavernous carotid artery and also decreased collateral supply to the ophthalmic system [9, 10].

### Case 2

A 54-year-old woman sustained a fall and subsequently developed left eye proptosis, chemosis, and a dilated nonreactive pupil. A diagnosis of left carotid-cavernous fistula was made and treated by common carotid ligation. Her eye findings did not improve and she was referred for further therapy. On admission the patient had a 20/30 visual acuity in the left eye with high intraocular pressure. Angiography demonstrated 60% stenosis of the common carotid artery at the ligature site, and a small low-flow fistula in the proximal cavernous segment of the internal carotid artery with a small aneurysmal dilatation of the anteroinferior compartment of the cavernous sinus and drainage to the superior division of the ophthalmic vein. Manual left carotid compression was well tolerated and good cross-filling from right to left was shown during left carotid angiography.

*Operation.* The internal and external carotid arteries were exposed in the neck under local anesthesia, an arteriotomy was performed on the internal carotid artery, and a 3 French Fogarty catheter was manipulated up to the fistula. When the balloon was inflated the patient immediately became aphasic and hemiplegic, but these findings completely cleared 1–2 min after deflating the balloon. The catheter was removed. During repair of the arteriotomy, temporary occlusion of the internal carotid artery was well tolerated for 20 min. The internal carotid artery was ligated and a Selverstone clamp was placed on the external carotid artery. The clamp was closed over a 3 day period without ill effects. The proptosis, intraocular pressure, and chemosis significantly improved and the patient was asymptomatic 1 year later.

*Comment.* Preoperative manual compression of the carotid artery in the neck (Matas test) was misleading, for at the time of balloon inflation during the operation a neurologic deficit developed. However, proximal internal carotid ligation and slow progressive occlusion of the external carotid artery were well tolerated. It is possible that at catheter placement and balloon inflation, a temporary ligature on the external carotid artery had compromised external carotid collateral flow to the left hemisphere to an extent that internal carotid occlusion was not tolerated. *At present we test tolerance to carotid occlusion in a direct way with a double lumen balloon catheter in the internal carotid artery during angiography* (Mediatech). This maneuver is reliable and easy to perform and also permits easy localization of the fistula site by stopping the flow in the diseased vessel while filming the slow injection of contrast material through the distal lumen [11]. In this patient, ligation of the internal carotid and external carotid arteries in the neck brought relief of the symptoms consistent with the reported 20%–50% cure rate reported after ligation of the common carotid artery [12]. Most good results from carotid ligation occur in small, low-flow fistulas.

### Case 3

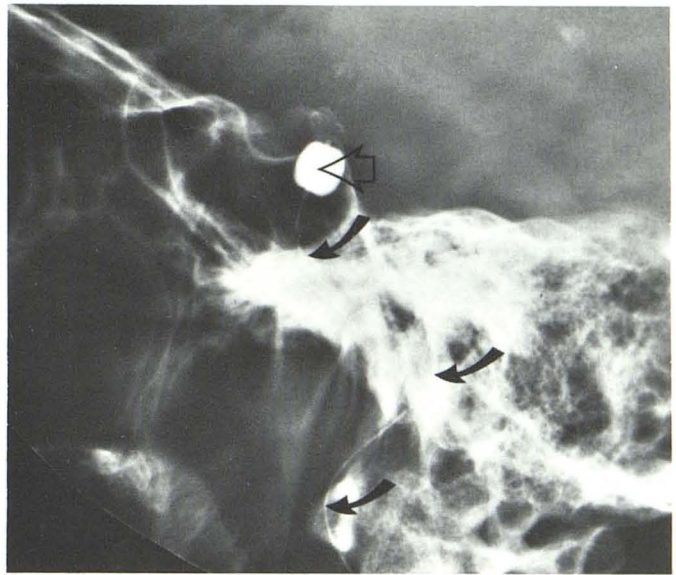A 30-year-old man had severe head trauma 1½ months before admission. At the time of injury he had been unconscious for 12 hr, after which he developed a pulsatile exophthalmos of the right eye associated with ptosis, conjunctival chemosis, and diplopia secondary to a right sixth nerve paresis. He complained of a noise inside his head. A loud bruit could be heard over the right eye. A transfemoral right cerebral angiogram demonstrated a high flow internal carotid-cavernous sinus fistula with drainage into the superior and inferior divisions of the ophthalmic vein anteriorly and into the inferior petrosal sinus posteriorly. An associated traumatic aneurysm of the right petrous internal carotid artery was also demonstrated (fig. 1A). No direct supply from the external carotid artery or other vessels was seen. Right carotid artery occlusion was well





A

Fig. 1.—Case 3. A, Lateral subtraction angiogram. High-flow internal carotid-cavernous sinus fistula with drainage into superior and inferior divisions of ophthalmic vein anteriorly and inferior petrosal sinus posteriorly. Associated traumatic aneurysm of petrous internal carotid artery (arrow). B,



B

After balloon placement in carotid artery at fistula site (open arrow). Catheter shaft (curved arrows) was bent, clipped, and anchored to carotid sheath in neck; internal carotid artery was ligated.

tolerated with good cross-filling through the circle of Willis during left carotid angiography.

**Operation.** An attempt to occlude the fistula via the internal jugular-inferior petrosal sinus was unsuccessful. The patient was treated by placement of a 3 French Fogarty catheter through an arteriotomy in the cervical internal carotid artery which was then advanced to the fistula site (fig. 1B). The balloon, inflated with contrast material (Reno-M-60) occluded the fistula. The balloon-inflation was well tolerated and the cervical internal carotid artery was ligated at the end of the procedure. The catheter was bent at its proximal end, secured with a silver clip, and anchored to the carotid sheath with 4-0 silk. The bruit disappeared immediately and the eye findings disappeared after 12 hr. The patient was clinically cured 1½ years later. The balloon deflated spontaneously in 3 weeks.

**Comment.** The treatment of choice in isolated carotid-cavernous fistulas seems to be obliteration of the fistulous communication with preservation of carotid artery flow. However, an associated traumatic pseudoaneurysm of the carotid artery (fig. 1A) is a contraindication to such therapy because closure of the fistula with preservation of carotid flow carries the risk of aneurysm rupture. Originally, we planned to occlude the fistula from the venous site (inferior petrosal to posterior cavernous sinus) and stereotaxic obliteration of the aneurysm. However, the inferior petrosal sinus could not be catheterized.

#### Case 4

A 27-year-old man suffered severe head trauma with numerous facial bone fractures 7 years before admission. There were no eye symptoms until 9 months before admission, when he developed right-sided chemosis, proptosis, ptosis, and diplopia on both medial and lateral gaze. The chemosis and proptosis resolved spontaneously 3 weeks after onset, but he developed severe headaches

in the right frontal area. A loud bruit synchronous with his pulse could be heard over the right eye and a right third nerve palsy was present. Angiography at another institution demonstrated a large fistulous communication from the right internal carotid artery to a bilobed aneurysmal dilatation of the cavernous sinus that produced elevation of the horizontal segment of the right middle cerebral artery. The venous drainage was toward superficial cortical veins. There was no filling of the ophthalmic vein or the petrosal sinus (fig. 2A). The exact fistulous communication could only be demonstrated with a double lumen balloon catheter occluding the right internal carotid artery, and the slow hand injection of contrast material (fig. 2B) [11]. There was no direct supply from the external carotid artery or any other vessels to the fistula. Tolerance to right carotid occlusion was tested with inflation of the balloon catheter. A left carotid angiogram (fig. 2C) with the balloon inflated demonstrated excellent cross-filling and the upper extent of the fistula.

**Operation.** The right common carotid artery was percutaneously catheterized and a Debrun detachable balloon catheter (Ingenor, Paris, France) was flow-guided into the venous side of the fistula with immediate disappearance of the bruit when the balloon was inflated with contrast material [3, 4]. A control angiogram showed occlusion of the arteriovenous shunt and preservation of carotid flow. The balloon was then deflated, and reinflated with silicone fluid. After allowing the silicone to vulcanize, the balloon was detached and the catheter assembly removed (fig. 2D). Follow-up angiography showed preservation of carotid flow and complete occlusion of the fistula (fig. 2E) [13]. All of the patient's signs and symptoms disappeared and he was discharged on postoperative day 4. On postoperative day 7, the patient complained of frontal headaches and diplopia to lateral gaze. The signs and symptoms completely resolved in 2 weeks. The patient was clinically asymptomatic 11 months later.

**Comments.** This case illustrates the ease of precise localization of a large arteriovenous communication with a double-lumen cath-



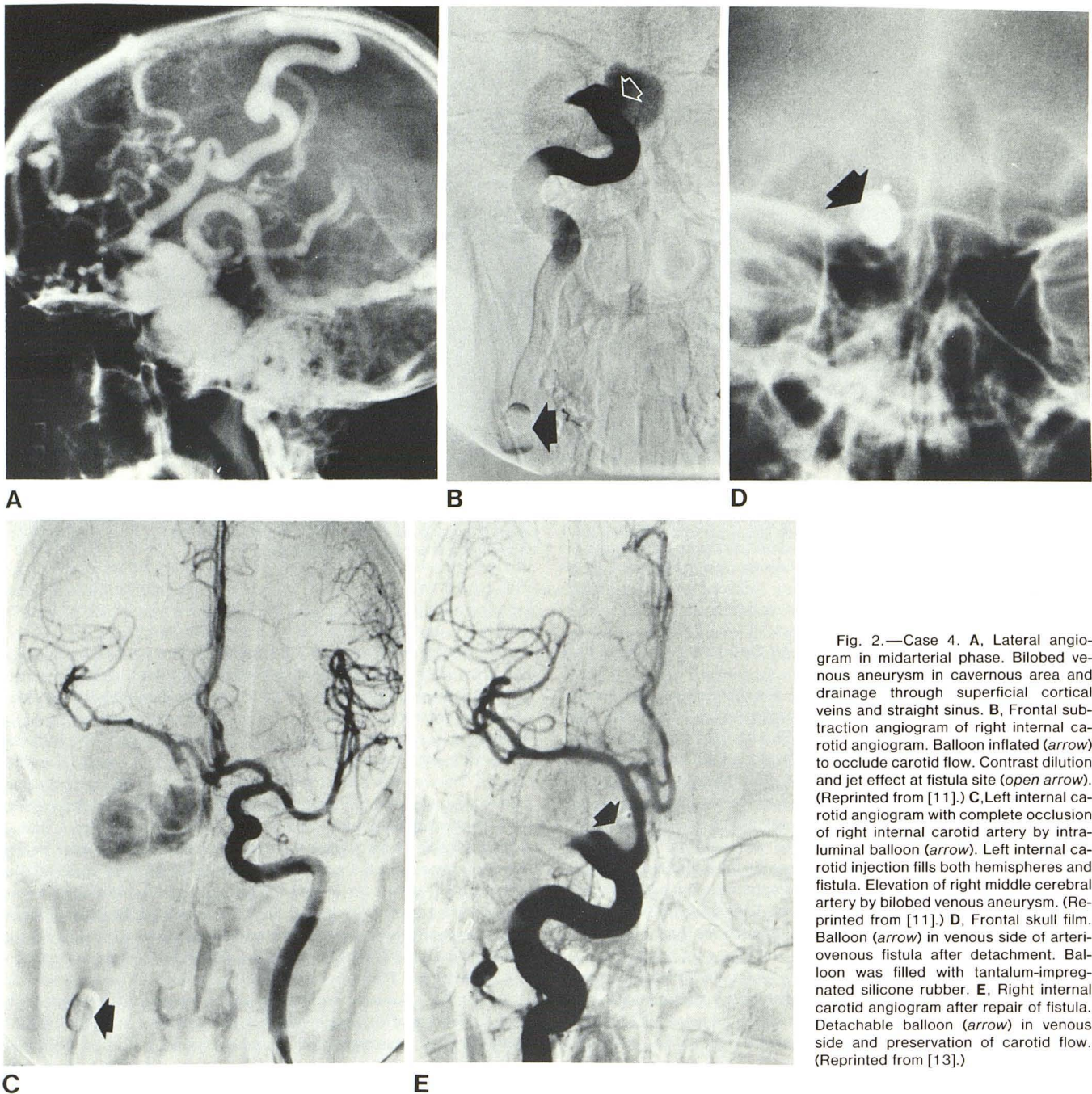


Fig. 2.—Case 4. **A**, Lateral angiogram in midarterial phase. Bilobed venous aneurysm in cavernous area and drainage through superficial cortical veins and straight sinus. **B**, Frontal subtraction angiogram of right internal carotid angiogram. Balloon inflated (arrow) to occlude carotid flow and jet effect at fistula site (open arrow). (Reprinted from [11].) **C**, Left internal carotid angiogram with complete occlusion of right internal carotid artery by intraluminal balloon (arrow). Left internal carotid injection fills both hemispheres and fistula. Elevation of right middle cerebral artery by bilobed venous aneurysm. (Reprinted from [11].) **D**, Frontal skull film. Balloon (arrow) in venous side of arteriovenous fistula after detachment. Balloon was filled with tantalum-impregnated silicone rubber. **E**, Right internal carotid angiogram after repair of fistula. Detachable balloon (arrow) in venous side and preservation of carotid flow. (Reprinted from [13].)

eter that also tests tolerance to carotid occlusion (figs. 2B and 2C). In this patient, with no other lesions or associated clinical problems, we believe the treatment of choice is occlusion of the fistula with a detachable balloon and preservation of the carotid artery flow. The transient postoperative diplopia and headaches possibly were caused by shrinkage of the large venous aneurysm and retraction of the dura or direct pressure on the abducens nerve that lies within the cavernous sinus.

#### Case 5

A 51-year-old woman was admitted to another institution after 5 months of spontaneous onset of diplopia to upward gaze, left retroorbital pain, periorbital swelling, partial ptosis, conjunctival

chemosis, tinnitus, and partial decreased sensation on the left side of the face. No bruit could be heard. Angiography showed a fistula from the left middle meningeal artery and the accessory middle meningeal artery to the cavernous sinus. The internal carotid artery did not supply the fistula. The venous drainage was through the superior division of the ophthalmic vein. The patient underwent percutaneous Gelfoam embolization with good postembolization results and disappearance of her signs and symptoms. Left jaw pain was present for 15 days and then disappeared spontaneously.

She was readmitted 3 weeks later because of recurrence of symptoms. Repeat angiography showed recanalization of the middle meningeal artery and filling of the fistula (fig. 3A). The patient was transferred to our medical center complaining of orbital tension, left retroorbital pain relieved only by Demerol, and numbness of the



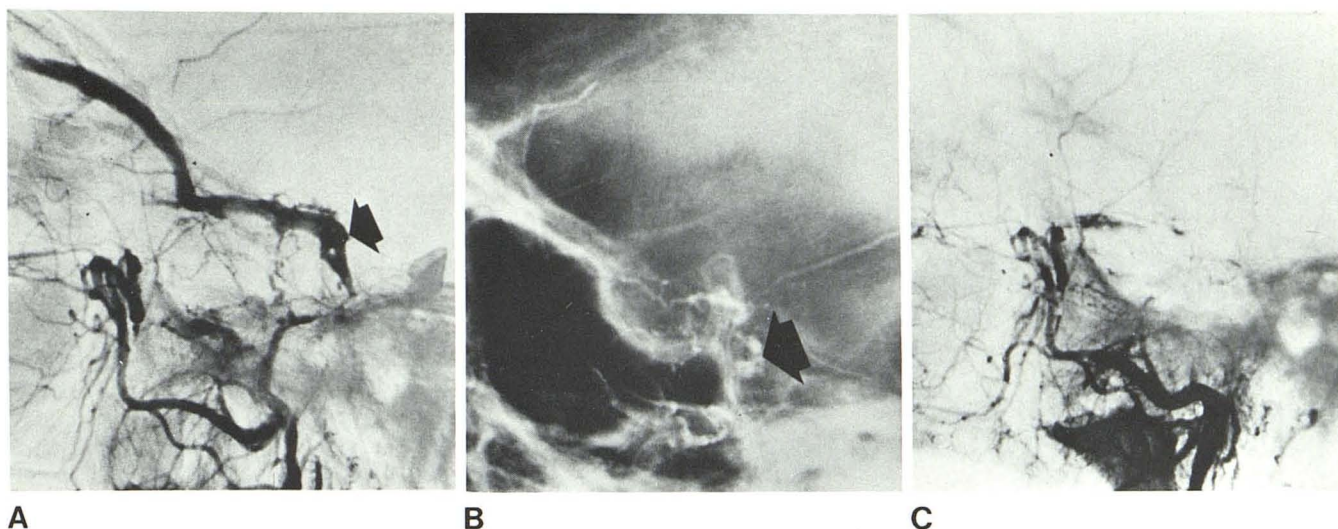


Fig. 3.—Case 5. A, Lateral subtraction angiogram of distal left external carotid artery. Fistula between left middle meningeal artery and cavernous sinus (arrow). Filling of superior division of ophthalmic vein. B, Lateral skull

film after embolization. Tantalum-oxide-impregnated IBCA at fistula site (arrow). C, Lateral subtraction angiogram in late arterial phase after embolization. No filling of fistula.

left side of her face. The left eye was tender to palpation with some fullness and conjunctival injection; a mild sensory V2 deficit on the same side was noted. No bruit was heard.

**Operation.** Superselective catheterization of the left middle meningeal artery was accomplished via percutaneous puncture of the left common carotid artery. Isobutyl-2 cyanoacrylate (IBCA), a tissue adhesive mixed with tantalum oxide was injected into the fistula, which was completely obliterated (figs. 3B and 3C). The patient's symptoms, with the exception of the sensory V2 deficit, disappeared within 3 hr. She was discharged on the postoperative day 4. At 10 months follow-up, she was asymptomatic except for her unchanged V2 deficit.

**Comments.** When the supply to the fistula is from the external carotid artery, balloon catheters will not reach the fistula and reabsorbable embolic agents tend to allow recanalization with recurrence of the fistula. To insure closure of the arteriovenous communication a nonbiodegradable embolic agent must occlude the fistula itself and not merely occlude the feeding vessel (fig. 3B). For this situation we consider that a fluid agent with tissue adhesive properties should be used to prevent migration of emboli to the dilated venous channels [14, 15]. The fluid agent is mixed with tantalum powder for radiopacity (to prevent skin discoloration, white tantalum oxide is used in white patients and black tantalum powder is used in black patients) [14].

When embolizing the middle meningeal artery, care must be taken to determine whether a meningolacrimal branch, which represents an anastomosis between the external carotid system and the ophthalmic system is present. Embolization of this artery may cause blindness. If the meningolacrimal artery is visualized, a nonbiodegradable solid embolic agent such as polyvinyl alcohol foam (Unipoint Lab, High Point, N. C.) cut in particles larger in diameter (200–400  $\mu$ ) than the meningolacrimal branch may be used for embolization. By avoiding excessive injection pressures and relying on the preferential flow toward the lesion, the procedure can be carried out safely. In addition, occlusion of the petrous branch of the middle meningeal artery, which arises near the foramen spinosum and is the main arterial pedicle to the peripheral facial nerve in 25% of the cases, may produce a facial palsy. Small particles and liquid agents must be introduced in a manner that avoids this vessel if technically possible. Placement of the catheter tip 15 mm

distal to the foramen spinosum will avoid the petrous branch. Technically, this is difficult to accomplish; preferential flow is relied upon to carry the emboli beyond the petrous branch.

#### Case 6

A 13-year-old boy fell from a cliff and sustained a fractured jaw, a left petrous bone fracture with injury to the left seventh nerve, a right sixth nerve palsy, and loss of vision in the right eye. Angiography performed at that time (unavailable for review) was interpreted as normal. At age 17, he was admitted to our center for reconstructive plastic surgery for proptosis of the right eye and mild hypertelorism.

His vision was 20/200 in the right eye and 20/20 in the left eye. A right sixth nerve palsy was noted. A bruit synchronous with the pulse was present over both eyes, but more prominent on the left. Complete angiographic investigation revealed a large left carotid-cavernous sinus fistula with filling of a large midline venous aneurysm (fig. 4). Venous drainage was toward the opposite ophthalmic vein, the cortical veins, and to the superior sagittal sinus. Tolerance to carotid occlusion and exact localization of the fistula site was determined with a double-lumen balloon catheter [11].

**First operation.** After percutaneous puncture of the left internal carotid artery, a 3 French Fogarty catheter was introduced, but could not be negotiated to the site of the fistula due to marked arterial tortuosity (fig. 4C). The catheter assembly was withdrawn and the carotid artery compressed.

**Second operation.** A percutaneous puncture of the left internal carotid artery was performed again about 1 week later. The introducer catheter could not be advanced into the carotid lumen, probably due to fibrosis caused by the previous procedure. Percutaneous puncture of the right femoral artery was performed and selective catheterization of the left internal carotid artery was accomplished. A Kerber calibrated-leak microballoon catheter (Cook, Bloomington, Ind.) was introduced and flow-directed into the fistula (fig. 4D). Two injections of IBCA with tantalum oxide were made into the fistula; however, the rapid flow in the fistula prevented the acrylate from polymerizing at the arteriovenous communication (fig. 4E). The patient was discharged in the hope that the foreign body



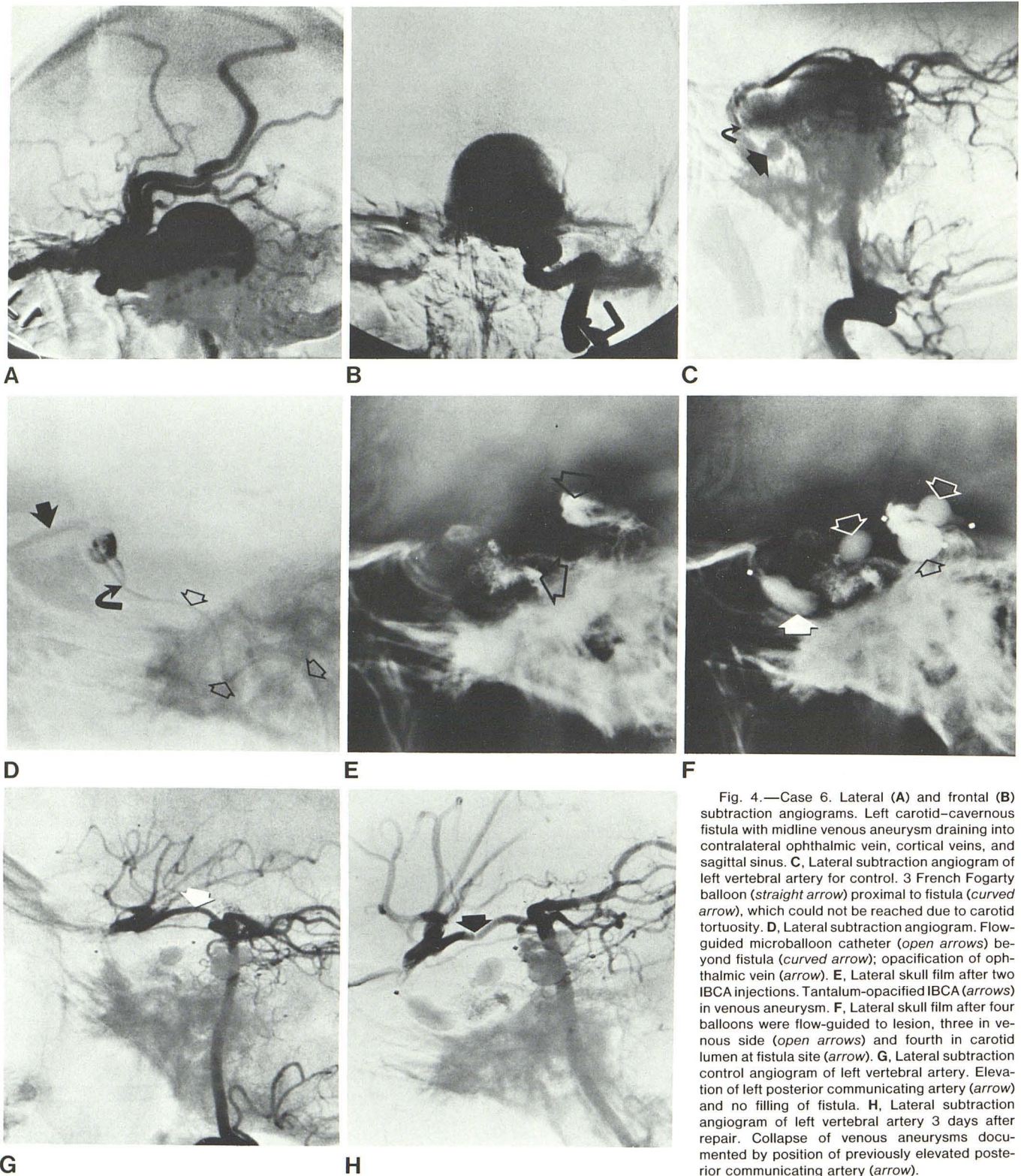


Fig. 4.—Case 6. Lateral (A) and frontal (B) subtraction angiograms. Left carotid-cavernous fistula with midline venous aneurysm draining into contralateral ophthalmic vein, cortical veins, and sagittal sinus. C, Lateral subtraction angiogram of left vertebral artery for control. 3 French Fogarty balloon (straight arrow) proximal to fistula (curved arrow), which could not be reached due to carotid tortuosity. D, Lateral subtraction angiogram. Flow-guided microballoon catheter (open arrows) beyond fistula (curved arrow); opacification of ophthalmic vein (arrow). E, Lateral skull film after two IBCA injections. Tantalum-opacified IBCA (arrows) in venous aneurysm. F, Lateral skull film after four balloons were flow-guided to lesion, three in venous side (open arrows) and fourth in carotid lumen at fistula site (arrow). G, Lateral subtraction control angiogram of left vertebral artery. Elevation of left posterior communicating artery (arrow) and no filling of fistula. H, Lateral subtraction angiogram of left vertebral artery 3 days after repair. Collapse of venous aneurysms documented by position of previously elevated posterior communicating artery (arrow).

(IBCA) within the venous aneurysm would promote thrombosis of the fistula. The bruit and proptosis were unchanged 3 weeks later.

*Third operation.* The left internal carotid artery was surgically exposed in its cervical part 1 month later. A Debrun detachable balloon catheter assembly was introduced via an arteriotomy and

the balloon was flow-guided into the fistula and inflated. The fistula remained patent. A total of four balloons was used, three of which were detached in the cavernous sinus. The fistula was closed by inflating the last balloon with Conray 60 in the internal carotid artery at the fistula site (fig. 4F). The bruit disappeared immediately. A



control left vertebral angiogram showed no filling of the fistula, but the left posterior communicating artery was still elevated by the venous aneurysm (fig. 4G). The catheter was left in place, bent, clipped, and anchored to the carotid sheath. The internal carotid artery was ligated in the neck (having the internal carotid artery exposed and the carotid lumen occluded, we opted for ligating the cervical internal carotid artery). During percutaneous balloon occlusion, when the carotid flow is not preserved, the catheter can be anchored subcutaneously.

The postoperative course was uneventful until postoperative day 3 when the patient felt a sharp midline headache while doing push-ups and sit-ups. No bruit could be heard. A left vertebral angiogram showed no filling of the fistula; collapse of the venous aneurysm was documented by the position of the left posterior communicating artery (fig. 4H). The headache resolved completely in 3 weeks and CT scan 2 weeks later showed no filling of the fistula (fig. 5). At 5 months the collapsed aneurysm had calcified and there was no filling of the fistula.

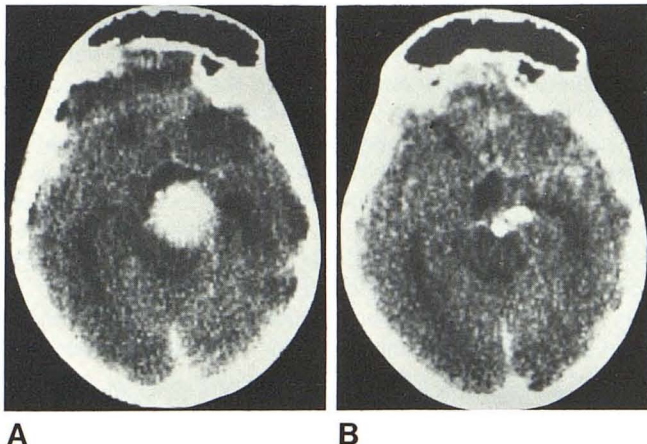


Fig. 5.—Case 6. Contrast-enhanced scans. **A**, Before repair. Opacification of circle of Willis and venous aneurysm. **B**, After repair. Good visualization of circle of Willis but no filling of venous aneurysm. Two balloons.

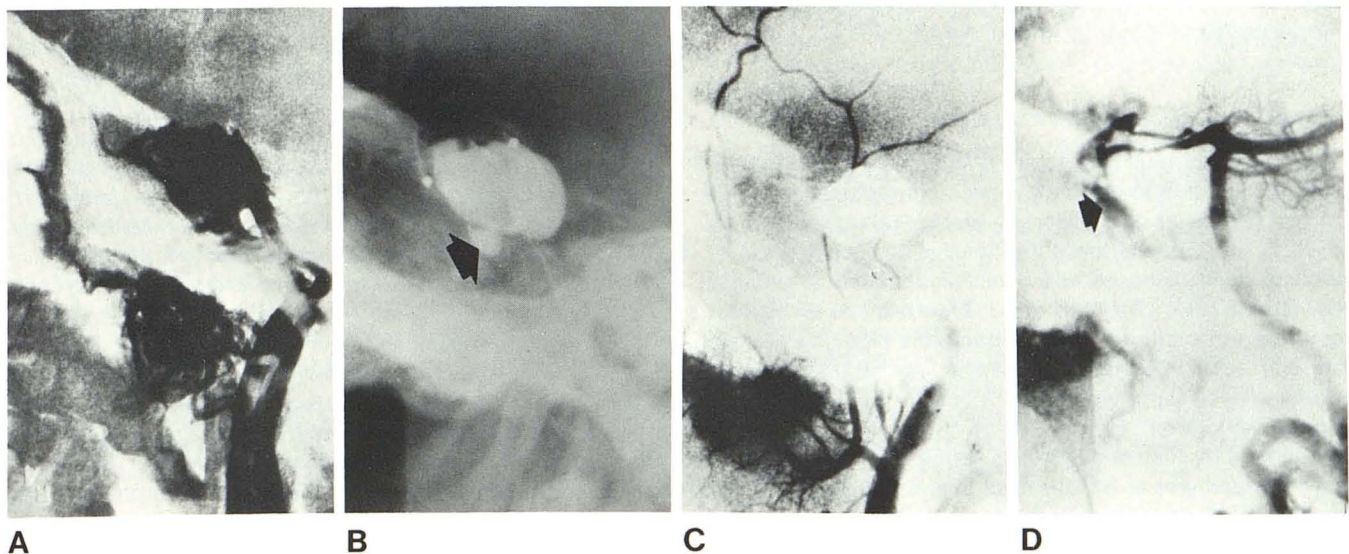


Fig. 6.—Case 7. **A**, Right internal carotid angiogram. Fistula drains to inferior petrosal sinus and the pterygomaxillary plexus. **B**, Lateral skull film. Two inflated and one deflated balloon in cavernous sinus; fourth balloon filled with radiopaque silicone is partly in cavernous sinus and partly in carotid

*Comments.* In a patient with contralateral blindness in whom the hemodynamic balance of the intracranial and ophthalmic circulations is well compensated, a safe approach would be to occlude the arteriovenous communication and the internal carotid flow with preservation of the external carotid circulation. Therefore, we started with a Fogarty catheter, for the long-term fate of the detachable balloon is still unclear. Debrun (Debrun G, unpublished data) has demonstrated balloon shrinkage and asymptomatic "aneurysms" at the site of vascular repair, secondary to balloon shrinkage. The aneurysms later diminished and no ill effects from these postembolization pouches were noted. However, the follow-up is relatively short and the theoretical possibility exists that these "aneurysms" may become the site for thrombus formation.

The limitations of a Fogarty and similar catheters in tortuous vessels is again demonstrated. A tissue adhesive such as IBCA does not seem to be a suitable occlusive agent in high-flow fistulas with large venous aneurysms, although Kerber et al. [16] treated some internal carotid-cavernous sinus fistulas with this technique. We do not know the size of the venous component in his cases or the flow rate. Finally, this case illustrates that more than one balloon may be necessary in large fistulas. The headaches in this case and in Case 3 possibly represented dural retraction secondary to shrinkage of the cavernous sinus.

Case 7

A 61-year-old woman, with a right maxillary sinus carcinoma with extension to the right orbit and sphenoid sinus, underwent resection of the tumor and exenteration of the right eye at another institution. Toward the end of the operation, brisk arterial bleeding was encountered, which stopped only after packing of the sphenoid sinus. A bruit could be heard over the right eyelid and the patient complained of a continuous murmur in her head. Angiography of the right internal carotid artery showed a right carotid-cavernous fistula with drainage to the inferior petrosal sinus and to the pterygomaxillary venous plexus (fig. 6A). No supply from other vessels could be demonstrated. An attempt to place a Swan-Ganz flow-directed catheter at the arteriovenous communication was unsuccessful. The patient was then referred to our hospital.



*First operation.* After percutaneous catheterization of the common carotid artery, two flow-directed Debrun detachable balloon catheters were negotiated to the venous side of the fistula. The first was inflated and detached without occlusion of the fistula. The second was placed in the fistula, occluding the internal carotid lumen and 90% of the fistula with disappearance of the bruit and murmur. This balloon was left inflated with contrast material, detached, and the catheter assembly removed. The patient had recurrence of her murmur 2 hr after embolization. A plain skull film showed deflation of the second balloon.

*Second operation.* Repeat angiography 1 week later showed the fistula to be patent. After percutaneous cervical carotid catheterization, two more balloons were needed to occlude the fistula. The last one was inflated with silicone fluid, which was allowed to vulcanize before detachment. The silicone-inflated balloon was partly in the fistula and partly in the carotid artery lumen (fig. 6B) producing complete occlusion of carotid flow (fig. 6C) and 90% occlusion of the fistula (fig. 6D). No neurologic signs ensued. The packing was removed from the sphenoid sinus on postoperative day 4, and the patient was asymptomatic from her fistula 4 months later.

*Comments.* In this case the relatively rigid Swan-Ganz catheter used in another insitution could not reach the site of the fistula. An area of atherosclerotic narrowing of the precavernous carotid artery was present at angiography. Flow-guided catheters were successful in negotiating the stenosis and tortuosity. More than one balloon was necessary to occlude the arteriovenous communication. An important technical consideration illustrated in this case is that if a balloon is to be detached, it should be in the venous side of the communication. If after the first procedure the balloon that deflated had been pointing intracranially, the risk of cerebral embolization would have been high. If the balloon cannot be directed to the venous side, it should be bent, clipped, and anchored subcutaneously, or the internal carotid artery may be ligated at the end of the operation to prevent the theoretical possibility of vessel recanalization when the balloon deflates. Latex balloons (versus silicone balloons) are liable to deflate [13, 14]. At our present state of knowledge, silicone balloons act as semipermeable membranes, and when inflated with an iso-osmotic contrast agent such as Amipaque, stay inflated for more than 2 weeks [17, 18]. This apparent advantage with silicone balloons is balanced against the lesser distensibility of silicone (4:1) versus latex (7:1).

## Discussion

Carotid-cavernous fistulas are unique lesions due to their anatomic location and hemodynamic characteristics. They are recognized as a challenging therapeutic problem [12, 19–22]. The risks of the untreated lesion include loss of vision in 25% of cases and visual impairment in another 20% [23]. Sattler [24] reported 3% mortality as a result of hemorrhage from the nose or intracranial bleeding and we saw one such occurrence. However, spontaneous cures have also been reported in 6% [23] to 10% [25] of patients.

In his monograph, Hamby [12] reviewed various surgical approaches to this condition and stated: "our experiences with the treatment of 37 cases of this condition led to the conclusion that this principle [carotid ligation] is incorrect and that the adoption of principle 3, simultaneous obstruction of all of the arterial components of the complex is the safest most effective method." He also states: "in the case of carotid cavernous fistulas, attempts at such operations

within the cavernous sinus are not routinely feasible." Parkinson [21] showed that it is surgically possible to repair these fistulas and preserve the carotid flow; however, this is a complex and major surgical technique. Morley [19] and Stern et al. [26] showed that the operative mortality and cerebral morbidity in the surgical approach to carotid-cavernous fistulas has been distressingly high.

In a recent publication, Mullan [20] reported 33 fistulas treated by a variety of ingenious approaches through the venous side, using thrombogenic techniques, with apparent good results. Intraoperative angiography is mandatory. In the description of his surgical techniques, it is clear that great skill and experience are necessary. The transjugular-inferior petrosal approach to lesions located in the posterior superior compartment described by Mullan [20] is not technically easy. We tried this once (case 3) but failed to catheterize the inferior petrosal sinus. In the cases of Mullan, he was able to catheterize the posterior cavernous sinus twice and failed twice. In the one patient in whom he occluded the fistula, the patient required balloon deflation because of trigeminal pain; however, the fistula was cured. In two of our cases, the venous return was toward cortical veins. In case 4 the fistula was in the posterior superior aspect of the C4 segment of the internal carotid artery with no drainage to the ophthalmic or petrosal systems. In case 6, the fistula opening was anteromedial with drainage to cortical veins and the opposite ophthalmic system, which would have prevented catheterization by the venous site.

In 1931, Brooks [27] was the first to show that an intraarterial approach is possible. In 1969, Prolo and Hanbery [7] used a balloon catheter to successfully treat a carotid-cavernous fistula; and in 1974, Serbinenko [22] was the first to use flow-guided detachable balloons for the treatment of arteriovenous fistulas with preservation of the carotid flow. However, not until Debrun et al. [3] published the technique of balloon detachment did it become clear that, due to favorable conditions in the hemodynamics of the fistula, the intraarterial route introduced by Brooks [27] was perhaps the ideal approach to carotid-cavernous fistulas. This is augmented by the development of percutaneous catheter techniques. Transarterial occlusion of the fistula may afford no significant morbidity; recovery is measured in hours to days and the procedure can be repeated with little risk or cost when compared with a direct surgical approach. Furthermore, the treatment is definitive in that the fistula itself, rather than vessels at a distance from the lesion, is obliterated. Elimination of the fistula precludes recurrence via collateralization.

One single transluminal technique is insufficient to treat the variety of anatomic, hemodynamic, or clinical presentations of carotid-cavernous fistulas. Versatility in techniques, with various materials and with balloon and nonballoon catheters of different design is necessary. The use of tissue adhesives in fistulas of the external carotid circulation, where communications are small, expands the capabilities of intraarterial treatment.

We believe that in the internal carotid circulation, occlusion of the fistula with a flow-guided balloon catheter is the transarterial technique of choice. Debrun et al. [4] success-



fully occluded 17 carotid-cavernous fistulas with preservation of carotid flow in 12. All patients were cured except for a temporary third-nerve palsy in one patient. Flow-guided detachable balloon catheters can bypass marked tortuosity (case 6) or stenosis (case 7) which impede more rigid catheters. In most cases, preservation of the internal carotid flow should be attempted by detaching balloons on the venous side, thereby occluding the fistula. However, when an associated aneurysm (case 3) or contralateral blindness (case 6) is present this may not be the treatment of choice. In such instances, careful clinical judgment should be used to select the best and safest treatment for the particular patient.

The physician involved in embolization techniques should consider transarterial treatments as a new and promising approach for difficult hemodynamic problems. The use of double-lumen balloon catheters during the investigation can provide the anatomic, hemodynamic, and clinical information necessary for better treatment planning.

#### ADDENDUM

Since acceptance of this manuscript, two other patients with carotid-cavernous fistulas have been successfully treated with preservation of the carotid flow. One patient was treated with a detachable balloon. The other was treated by the jugular-inferior petrosal approach, with the insertion of a 3 French Fogarty catheter that was left in the posterosuperior compartment of the cavernous sinus.

#### ACKNOWLEDGMENTS

We thank Linda Michaels, Barbara Lombardi, and Diana Aretino for assistance in manuscript preparation; Sinicio Gonzalez and Philip Fontana for technical assistance; and the Department of Photodiagnosis, New York University Medical Center and Bellevue Hospital.

#### REFERENCES

1. Edwards MS, Connolly ES. Cavernous sinus syndrome produced by communication between the external carotid artery and cavernous sinus. *J Neurosurg* 1977;46:92-96
2. Houser OW, Baker HL Jr, Rhoton AL Jr, et al. Intracranial dural arteriovenous malformations. *Radiology* 1972;105:55-64
3. Debrun G, Lacour P, Caron JP, et al. Inflatable and released balloon technique. Experimentation in Dog—application in men. *Neuroradiology* 1975;9:267-271
4. Debrun G, Lacour P, Caron JP, et al. Detachable balloon and calibrated leak balloon technique in the treatment of cerebral vascular lesions. *J Neurosurg* 1978;49:635-649
5. Laitiner L, Servo A. Embolization of cerebral vessels with inflatable and detachable balloon. *J Neurosurg* 1978;48:307-308
6. Picard L, Lepoivre J, Mantaut J, et al. Endarterial occlusion of carotid-cavernous sinus fistulas using a balloon tipped catheter. *Neuroradiology* 1974;8:5-10
7. Prolo DJ, Hanbery JW. Intraluminal occlusion of a carotid-cavernous sinus fistula with a balloon catheter. Technical note. *J Neurosurg* 1971;35:237-242
8. Prolo DJ, Burres KP, Hanbery JW. Balloon occlusion of carotid-cavernous fistula: introduction of a new catheter. *Surg Neurol* 1977;7:209-214
9. Lasjaunias P, Moret J, Mink J. The anatomy of the inferolateral trunk (ILT) of the internal carotid artery. *Neuroradiology* 1977;13:215-220
10. Margolis MT, Newton TH. Collateral pathways between the cavernous portion of the internal carotid and external carotid arteries. *Radiology* 1969;93:834-836
11. Berenstein A, Kricheff II. Balloon catheters for investigating carotid cavernous fistulas. *Radiology* 1979;132:762-764
12. Hamby W. *Carotid cavernous fistula*. Springfield, IL: Thomas, 1966:71-106
13. Berenstein A, Kricheff II. Catheter and material selection for transarterial embolization. I. Catheters. *Radiology* 1979;132:619-630
14. Berenstein A, Kricheff II. Catheter and material selection for transarterial embolization. II. Materials. *Radiology* 1979;132:631-639
15. Zanetti P, Sherman F. Experimental evaluation of a tissue adhesive as an agent for the treatment of aneurysms and arteriovenous anomalies. *J Neurosurg* 1972;36:76-79
16. Kerber CW, Bank WO, Cromwell LD. Calibrated leak balloon microcatheter: a device for arterial exploration and occlusive therapy. *AJR* 1979;132:207-212
17. White RI Jr, Ursic TA, Kaufman SL, Barth KH, Kim W, Gross GS. Therapeutic embolization with detachable balloons. Physical factors influencing permanent occlusion. *Radiology* 1978;126:521-523
18. DiTullio MV Jr, Rand RW, Frish E. Detachable balloon catheter. Its application in experimental arteriovenous fistulae. *J Neurosurg* 1978;48:717-723
19. Morley RP. Appraisal of various forms of management in 41 cases of carotid cavernous fistulas. In: Morley RP, ed. *Controversies in neurosurgery*. Philadelphia: Saunders, 1976:223-236
20. Mullan S. Treatment of carotid-cavernous fistulas by cavernous sinus occlusion. *J Neurosurg* 1979;50:131-144
21. Parkinson D. Carotid cavernous fistulas: direct repair with preservation of the carotid artery. Technical note. *J Neurosurg* 1973;38:99-106
22. Serbinenko FA. Balloon catheterization and occlusion of major cerebral vessels. *J Neurosurg* 1974;41:125-145
23. Hamby W. *Carotid cavernous fistulas*. Springfield, IL: Thomas, 1966:63-70
24. Sattler CH. *Pulsierendis Exophthalmus, Handbuch der gesamten Augenheilkund*. Berlin: Springer, 1920
25. Dandy WE, Follis RH. On the pathology of carotid cavernous aneurysms (pulsating exophthalmos). *Am J Ophthalmol* 1941;24:365-385
26. Stern WE, Brown WJ, Alksne JF. The surgical challenge of carotid cavernous fistulas: the critical role of intracranial circulatory dynamics. *J Neurosurg* 1967;27:290-308
27. Brooks B. Discussion Noland L., and Taylor A.S. *Trans South Surg Ann* 1931;43:176-177