
Pituitary Hemorrhage as a Complication of Hantaviral Disease

Dae Chul Suh, Jung Sik Park, Su-Kil Park, Ho Kyu Lee, and Kee Hyun Chang

Summary: We report the case of a 27-year-old man with hemorrhagic fever with renal syndrome who demonstrated pituitary hemorrhage followed by atrophic change seen on follow-up MR.

Index terms: Pituitary gland, hemorrhage; Pituitary gland, magnetic resonance; Viruses

Hemorrhagic fever with renal syndrome (HFRS) is an acute viral disease caused by viruses that belong to the genus *Hantavirus*. Hantaviruses produce a spectrum of illness characterized by fever, circulatory collapse, hemorrhages, and renal failure. Necrosis and hemorrhage in the anterior lobe of the pituitary gland have been observed in autopsy materials in the acute stage of HFRS (1–3). Pituitary atrophy was observed by computed tomography scan of the sella turcica in the late stage of or after recovery from HFRS (4). These findings suggest that patients in the acute stage of severe HFRS may have pituitary apoplexy (5, 6) and subsequent permanent residual pituitary hypofunction.

We report the magnetic resonance (MR) features of pituitary hemorrhage followed by pituitary atrophy, mainly involving the anterior pituitary gland, in a patient with HFRS who showed selective anterior pituitary hypofunction.

Case Report

A 27-year-old man had been well until 7 days before admission, when sudden fever and myalgia developed, followed by nausea, vomiting, epigastric pain, and decreased urine volume. He was brought to a community hospital on the seventh day of illness and received a diagnosis of HFRS. A serologic test for antibody to hantaviruses (indirect immunofluorescent antibody test) was positive with high titers (1:1280). He was referred to our hospital on the same day.

There was no history of tuberculosis, syphilis, sarcoidosis, trauma, surgery, or radiation therapy. Blood pressure was 130/100 mm Hg, pulse rate 102 beats per minute, and body temperature 36.0° C. On physical examination, he was drowsy and irritable. His face showed a sunburned appearance with slight puffiness. There were several petechiae on the hard palate and in both axillae. Neurologic examination was negative.

The hematocrit was 30.1%, the white cell count 14,100/mL, and the platelet count 64,000/mL. During the hospital course, hemodialysis was done three times until diuresis started on the 15th day of illness. Even after diuresis, severe asthenia developed. On the 17th day of illness, a sudden generalized seizure developed and brain computed tomography findings at that time were normal. The basal 8 AM levels of hormonal studies done on the 20th day of illness were: liothyronine sodium uptake, 0.30; liothyronine sodium, 53 ng/L; levothyroxine sodium, 2.7 ng/L; thyrotropin (thyroid-stimulating hormone), 0.08 mIU/L; corticotropin (adrenocorticotropic hormone), 31.2 pg/mL; and cortisol, 15 µg/dL.

He was discharged 1 month after admission. To evaluate pituitary function 3 months later, a combined pituitary stimulation test, consisting of the simultaneous intravenous administration of 0.1 U/kg of regular insulin, 400 µg of thyrotropin-releasing hormone and 100 µg of luteinizing hormone-releasing hormone revealed no response to thyrotropin-releasing hormone, insulin-induced hypoglycemia, or luteinizing hormone-releasing hormone. After daily treatment with 5 mg of prednisolone and 0.1 mg of thyroxine, pituitary function and symptoms improved. There were no symptoms of posterior pituitary gland hypofunction.

The first sellar MR imaging was performed on the 19th day of illness. Sagittal T1- and T2-weighted images showed high signal intensity in the anterior pituitary gland and low signal intensity in the central portion of the pituitary gland between the high signal intensity of the anterior pituitary gland and the high signal intensity of the posterior pituitary gland (Fig 1A and B). After gadopentetate dimeglumine administration, the pituitary gland, including the central portion of low signal intensity, showed enhancement (Fig 1C). The second sella MR done 3 months later

Received October 18, 1993; accepted after revision February 3, 1994.

From the Departments of Diagnostic Radiology (D.C.S., H.K.L.) and Internal Medicine (J.S.P., S.-K.P.), Asan Medical Center, University of Ulsan College of Medicine, and the Department of Radiology, College of Medicine, Seoul National University (K.H.C.), Seoul, Korea.

Address reprint requests to Dae Chul Suh, MD, Department of Diagnostic Radiology, Asan Medical Center, University of Ulsan College of Medicine, 388-1 PoongNap-Dong, SongPa-Ku, Seoul 138-040, Korea.

AJNR 16:175–178, Jan 1995 0195-6108/95/1601-0175 © American Society of Neuroradiology




Fig 1. Three-millimeter midline sagittal images obtained at 1.5 T.

A, T1-weighted image (600/20/1 [repetition time/echo time/excitations]) shows a high signal intensity revealing hemorrhage in the anterior pituitary gland. A low signal intensity is noted in the central portion of the pituitary gland (*arrow*). A high signal intensity in the posterior pituitary gland represents a normal bright spot.

B, T2-weighted image (2500/80/1) shows an intermediate signal intensity of the anterior portion and a low signal intensity of the central portion of the pituitary gland (*arrows*), which is larger than that of the T1-weighted image (A, *arrow*) because of the increased susceptibility.

C, T1-weighted image (600/20/1). The pituitary gland enhances homogeneously after intravenous administration of gadopentetate dimeglumine. Note swelling at the origin of the infundibulum (*arrow*).

D through F, Follow-up sagittal MR images 3 months later. D, T1-weighted image (600/20/2) shows decreased pituitary gland height sparing the posterior pituitary gland (*black arrow*). E, T2-weighted image (2500/80/1) reveals a low signal intensity in the anterior lobe of the pituitary gland (*arrow*). F, Gadopentetate dimeglumine-enhanced T1-weighted image (600/20/2) shows a defect in the central portion of the pituitary gland without enhancement (*large arrow*). Note atrophic change at the origin of the infundibulum (*small arrow*).

showed atrophy of the pituitary, mainly in the anterior pituitary gland (Fig 1D and F).

Discussion

HFRS is an acute febrile disease prevalent in Europe and Asia. HFRS was previously known as "epidemic hemorrhagic fever" or "Korean hemorrhagic fever." The causative agent is any one of several closely related viruses of the genus *Hantavirus*, family *Bunyaviridae* (7). Han-

taviruses are enveloped particles with a diameter of 90 to 120 nm and a single negative-stranded RNA genome (8). Four distinct hantaviruses have been identified: Hantaan, Seoul, Puumala, and Prospect Hill. The prototype is Hantaan virus, originally isolated from *Apodemus agrarius* field mice in the endemic region of Korea. A growing number of new but related viruses have been isolated from different species of rodents and occasionally from

acutely ill patients. Hantaviruses had been isolated in the United States: Seoul virus from *Rattus norvegicus* (Norway rat) and Prospect Hill virus from *Microtus pennsylvanicus* (meadow vole) (9, 10). All hantaviruses are most likely transmitted by rodents, with the major route of transmission to man via aerosol from rodent urine, saliva, and feces.

Hantaviruses produce a spectrum of illnesses, with specific manifestations depending on the particular virus involved. Hantaan virus causes the most severe disease and Puumala virus the least severe (11). Seoul virus typically produces disease of intermediate severity that is associated with more findings of hepatic involvement than are noted for other hantaviruses (12). Antibodies of Seoul virus have been associated with hypertensive end-stage renal disease in patients in Baltimore, Md (10). Prospect Hill virus has not been identified as a human pathogen (13). The new strain, recently identified in the United States and initially dubbed the Four Corners strain, differs from other hantaviruses: Its effects are more rapid and more lethal and it destroys the lungs rather than the kidney (14).

Most HFRS patients recover completely, except for those with rare neurologic sequelae (15, 16). HFRS is manifested clinically by the triad of fever, hemorrhage, and renal failure (13). The disease progresses through the characteristic five phases: febrile, hypotensive, oliguric, diuretic, and convalescent. The central physiologic derangement in HFRS is vascular dysfunction, manifested by impaired vascular tone and increased vascular permeability (13). Hemorrhage seems to be a consequence of vascular injury and a deficit of functional platelets, which are both compounded by uremia (13). Hemorrhage and necrosis in the anterior lobe of the pituitary gland develop in 50% to 100% of fatal cases and death can occur as a serious complication after the hypotensive phase (1-3). The anterior pituitary gland was one of the most common sites of hemorrhage in 29 autopsied humans in conjunction with the renal medulla and the right atrium of the heart (17).

Since Mayer described the clinical panhypopituitarism following HFRS, a few more reports have been documented (18). According to previous reports, most hypopituitarism occurred after recovery from the acute phase of illness and manifested in panhypopituitarism after recovery. Microscopically, the anterior lobe

showed the typical focuses of necrosis in 31 of 40 autopsies extending into the infundibulum, where it was associated with hemorrhage according to the severity of the disease (2). In a few cases, the hypothalamus revealed focuses of hemorrhage in the mammillary body and at the origin of the infundibulum. The areas of necrosis were located generally in the central portion near the fibrovascular stalk of the infundibulum in 39 autopsies of 42 fatal cases (1). The mechanism of the necrosis and hemorrhage of the pituitary gland is still unknown, but vasospasm accompanied by shock was suggested (17, 19). There was no evidence of vascular occlusion (2).

The MR scan in the case presented here revealed areas of three different intensities in the pituitary gland. The most anteriorly located high signal intensity in the anterior pituitary gland on T1-weighted image suggested that the hemorrhage occurred at least 1 week before MR examination, because hemorrhage after 1 week on 1.5-T MR image appears as a high signal intensity on T1-weighted image because of methemoglobin in the hemorrhage (20). However, it remains unclear whether the hemorrhage exists as intracellular or extracellular methemoglobin, because the area showed only a faint high signal intensity on T2-weighted image. Such a finding suggests that the hemorrhage occurred between 1 and 2 weeks before MR imaging, because high signal intensity on both T1- and T2-weighted image can be observed 2 weeks after hemorrhage (20). According to the previous pathology reports (1, 2) and MR findings in this case, the changes of the anterior pituitary gland in our patient represented hemorrhage in a subacute stage and seemed to develop during the acute phase of the HFRS. The second abnormal signal intensity was found in the central portion of the pituitary gland, showing a low signal intensity on both T1- and T2-weighted images and enhancement after gadopentetate dimeglumine administration. The time of hemorrhage appeared to be within 1 week before MR imaging, because low signal intensity on both T1- and T2-weighted image can be observed within 1 week after hemorrhage (20).

The central portion of the pituitary gland, showing low signal intensities especially on T2-weighted images, was suggestive of hemorrhagic necrosis, because the central portion of the pituitary gland appeared as an area of low

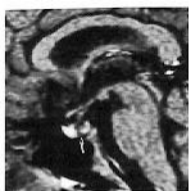signal intensity without enhancement on follow-up MR but still showed dark signal intensities on T2-weighted image as a sequela of hemorrhage. Such MR features may suggest the variable signal intensities of the hemorrhagic area, depending on the location and stage of the hemorrhage and the severity of the disease. The change of the MR features in the central portion of the pituitary gland might be explained by changes in the chemical composition of the heme iron in a necrotic cavitylike lesion. The third area of the bright signal intensity in the posterior lobe was definitely related to a functionally intact posterior lobe and remained intact on follow-up MR.

The pituitary gland height was decreased on the follow-up MR examination 3 months later. In addition to an area of central necrosis without gadopentetate dimeglumine enhancement, the atrophic change appeared mainly in the anterior lobe and infundibulum, corresponding to areas of pituitary hypofunction. There were low levels of pituitary secretory hormones and target gland hormones on the 20th day of illness and on follow-up studies. The atrophic change and necrosis of the anterior pituitary gland in the late stage of our case were considered similar to those described in previous reports showing progressive pituitary atrophy on sequential follow-up sellar computed tomography (4) and hemorrhagic necrosis on pathology (1, 2). The involvement of the posterior pituitary gland tended to be less severe than that of the anterior lobe, although the development of posterior pituitary hypofunction such as diabetes insipidus may occur rarely (5).

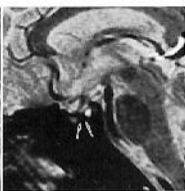References

1. Lukes RJ. Pathology of thirty-nine fatal cases of epidemic hemorrhagic fever. *Am J Med* 1952;16:639-650
2. Hullinghorst RL, Steer A. Pathology of epidemic hemorrhagic fever. *Ann Intern Med* 1953;38:77-101
3. Steer A. Pathology of hemorrhagic fever: a comparison of findings 1951 and 1952. *Am J Pathol* 1955;31:201-221
4. Lim TH, Chang KH, Han MC, et al. Pituitary atrophy in Korean hemorrhagic fever. *AJNR Am J Neuroradiol* 1986;7:633-637
5. Lee JS, Ahn C, Oh HY, Kim S, Lee M, Kim YI. Panhypopituitarism and central diabetes insipidus as a complication of hemorrhagic fever with renal syndrome. *Seoul J Med* 1986;27:53-58
6. Lee JS, Han JS, Kim S, Chang KH. Panhypopituitarism in the acute stage of hemorrhagic fever with renal syndrome: a case report. *Arch Virol* 1990;(suppl 1):95-100
7. Schmaljohn CS, Hasty SE, Dalrymple JM, et al. Antigenic and genetic properties of viruses linked to hemorrhagic fever with renal syndrome. *Science* 1985;227:1041-1044
8. Niklasson BS. Haemorrhagic fever with renal syndrome, virological and epidemiological aspects. *Pediatr Nephrol* 1992;6:201-204
9. Yanagihara R. Hantavirus infection in the United States: epizootiology and epidemiology. *Rev Infect Dis* 1990;12:449-457
10. Glass GE, Watson AJ, LeDuc JW, Kelen GD, Quinn TC, Childs JE. Infection with a ratborne hantavirus in US residents is consistently associated with hypertensive renal disease. *J Infect Dis* 1993;167:614-620
11. Lee HW. Korean hemorrhagic fever. *Prog Med Virol* 1982;28:96-113
12. Byun KS, Seo JB, Lee MS, et al. A clinical study of hemorrhagic fever with renal syndrome caused by Seoul viral infection. *Korean J Infect Dis* 1986;18:11-18
13. Cosgriff TM. Mechanism of disease in Hantavirus infection: pathophysiology of hemorrhagic fever with renal syndrome. *Rev Infect Dis* 1991;13:97-107
14. News and comment. Hantavirus outbreak yields to PCR. *Science* 1993;262:832
15. Lee JS. Korean hemorrhagic fever: hemorrhagic fever with renal syndrome. *Inje Med J* 1985;6:23-26
16. Lee M. *Korean Hemorrhagic Fever: Hemorrhagic Fever with Renal Syndrome*. 2nd ed. Seoul, Korea: Seoul National University Press, 1986
17. Kim YI. Korean hemorrhagic fever-pathologic approach and its problems. *Korean J Intern Med* 1976;19:384-391
18. Mayer CF. Epidemic hemorrhagic fever of the Far East or endemic hemorrhagic nephrosonephritis: morphology and pathogenesis. *Lab Invest* 1952;1:291-311
19. Kim YI. Pathologic studies on epidemic hemorrhagic fever. *Korean J Intern Med* 1972;15:161-166
20. Chaney RK, Taber KH, Orrison WW, Jr, Hayman LA. Magnetic resonance imaging of intracerebral hemorrhage at different field strengths: a review of reported intraparenchymal signal intensities. *NCNA* 1992;2(1):25-51

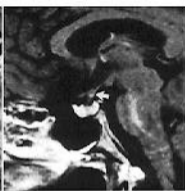
Please see the commentary on page 179 in this issue.



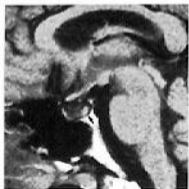A



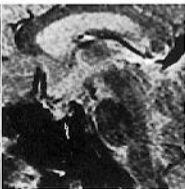
B



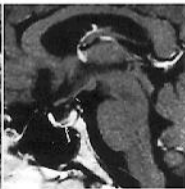
C



D



E



F