

MR Imaging of Perinatal Brain Damage: Comparison of Clinical Outcome with Initial and Follow-up MR Findings

Noriko Aida, Gen Nishimura, Yuriko Hachiya, Kiyoshi Matsui, Maho Takeuchi, and Yasufumi Itani

BACKGROUND AND PURPOSE: The purpose of our study was to determine whether MR studies in the neonatal period are predictive of the neuroradiologic sequelae and clinical outcome in premature and term infants with perinatal brain injury.

METHODS: Thirty subjects (15 premature and 15 term infants) with abnormalities revealed by initial MR studies were reexamined approximately 1 year after birth with both MR imaging and a neurologic assessment. All initial MR studies were performed between 35 and 45 weeks corrected age in premature infants and within 28 days of life in term infants. The initial MR studies were evaluated for deep gray matter involvement, hemispheric parenchymal change, intracranial hemorrhage, and periventricular signal and/or morphologic changes. These MR findings were compared with the follow-up MR findings and with the neurologic outcome.

RESULTS: The development of cerebral palsy in premature infants was related to the following initial MR findings: subependymal hemorrhage associated with parenchymal destruction, periventricular signal alteration with irregularity of the ventricular wall, and widespread cerebral infarction. These MR findings were predictive of the subtypes of cerebral palsy. In term asphyxiated infants, T2 signal alterations of the deep gray matter rather than T1 shortening and diffuse involvement of the hemispheres were predictive of an unfavorable outcome. Both in term and premature infants, focal hemispheric parenchymal lesions alone (including infarction and intracerebral, subdural, intraventricular, and subarachnoid hemorrhage) did not produce poor outcomes.

CONCLUSION: MR studies performed at or near term in either premature or term infants with perinatal brain damage are effective in predicting both late neuroradiologic and clinical outcome.

The accurate prediction of clinical outcome after neonatal brain damage, including intrapartum hypoxic-ischemic cerebral insult, is difficult because of the inability to determine the severity, timing, tempo, and duration of the insult. Early evaluation and diagnosis of neonatal brain injuries have been facilitated by the application of new imaging techniques, as suggested in several reports on the usefulness of MR imaging (1–11). However, premature infants with perinatal brain damage are often clinically unstable and diffi-

cult to image with MR shortly after birth. Thus, few reports discuss the results of early MR studies obtained in premature infants at or before 40 weeks corrected age (9–11). MR imaging is readily applicable for the assessment of term infants with perinatal brain damage (5–8), but the accurate prediction of clinical outcome is not an easy task even in this group of affected infants. The relationship among MR findings in the neonatal period, MR findings on subsequent follow-up studies, and the infants' clinical outcome remain to be more thoroughly elucidated. The purpose of this study was to examine these relationships in both premature and term infants with perinatal brain damage and to compare those findings with the neurologic clinical evaluation obtained at least 1 year after birth.

Methods

Thirty neonates (15 premature and 15 term infants) met all study criteria and were selected for detailed review. Entry criteria included an initial clinical suspicion of perinatal hy-

Received August 4, 1997; accepted after revision June 1, 1998.

Presented in part at the annual meeting of the American Society of Neuroradiology, Seattle, June 1996, and Toronto, May 1997.

From the Departments of Radiology (N.A., G.N., Y.H., M.T.) and Neonatology (K.M.), Kanagawa Children's Medical Center, Yokohama, and the Department of Radiology, School of Medicine, Dokkyo University (G.N.), Tochigi, Japan.

Address reprint requests to Noriko Aida, MD, Department of Radiology, Kanagawa Children's Medical Center, 2-138-4, Mut-sukawa Minami-ku Yokohama, 232-0066 Japan.

TABLE 1: Clinical and Radiologic Findings of Premature Infants with Perinatal Brain Damage

Patient	Clinical information			Outcome			Initial MR Imaging	
	Gestational Age at Birth (wk)/ Birth Weight (g)	Apgar Score (1/5)	Symptoms or Diagnosis	CP	EPI	DD	Age (wk) at Scan: PCA (CA)	Abnormalities of Deep Gray Matter
1	24/715	6/7	Apnea, hyperkalemia	Diplegia	—	—	39 (14)	...
2	26/930	3/4	Twin, NEC	Mild diplegia	—	—	43 (17)	...
3	27/990	1/4	Pulmonary hemorrhage	...	—	—	40 (13)	...
4	27/1020	1/6	RDS, PDA, apnea, hyperkalemia	Diplegia	—	+	41 (14)	...
5	27/1150	4/8	RDS, sepsis	...	—	+	45 (18)	...
6	28/1050	6/9	RDS	Diplegia	+	+	40 (12)	...
7	28/1100	7/9	Apnea, hyperkalemia, tachycardia	Diplegia	—	—	38 (10)	...
8	28/1272	7/9	RDS	Diplegia, hemiparesis	—	—	36 (8)	...
9	28/1280	5/5	RDS, hyperkalemia, PDA	Quadriparesis	+	+	39 (11)	...
10	28/1355	2/3	GBS infection, NEC	Diplegia, hemiparesis	—	—	38 (10)	...
11	29/1140	1/6	Placental detachment	Diplegia	+	—	39 (10)	...
12	30/1288	7/7	Apnea	Diplegia	+	—	37 (7)	...
13	31/1735	9/9	HIE grade I, seizure	...	—	—	36 (5)	...
14	32/1426	5/7	Death of a cotwin, DIC	Diplegia, mild hemiparesis	+	—	36 (4); 43 (11)	...
15	32/1870	9/?	Apnea, seizure	Hemiparesis	—	—	35 (22 days); 36 (31 days)	...

Note.—RDS indicates respiratory distress syndrome; PDA, patent ductus arteriosus; GBS, group B streptococcus; NEC, necrotizing enterocolitis; HIE, hypoxic-ischemic encephalopathy; CP, cerebral palsy; EPI, epilepsy; DD, developmental delay; PCA, postconceptional age; CA, chronological age; MCA, middle cerebral artery; SEH, subependymal hemorrhage; IVH, intraventricular hemorrhage; SDH, subdural hemorrhage; SAH, subarachnoid hemorrhage; PVL, periventricular leukomalacia; LV, lateral ventricle; PV, periventricular; DIC, disseminated intravascular coagulation.

poxic-ischemic injury in either premature or term infants, an early MR study showing abnormalities, and both a delayed MR study and a neurologic evaluation as outlined below. The initial clinical diagnosis of perinatal asphyxia was based on low Apgar scores and clinical symptoms suggesting hypoxic-ischemic encephalopathy, such as convulsions, lethargy, agitation, and/or respiratory problems. Infants with brain malformations, metabolic abnormalities, or perinatal infection were excluded.

Premature infants were defined as neonates less than 32 weeks gestational age. They were examined with MR imaging at approximately 40 weeks corrected age and included in the study only if the initial MR study was performed at or before 45 weeks corrected age. Detailed follow-up neurologic assessment and MR studies were performed at least 1 year after birth. Term infants were included for evaluation if they were at least 35 weeks gestational age and an initial MR study had been obtained within 28 days of birth. Again, both a detailed follow-up neurologic assessment and MR study were performed approximately 1 year later.

All initial MR examinations were performed with a 1.5-T scanner. The studies consisted of 5-mm axial and coronal spin-echo (SE) T1-weighted images (400/15/2 [TE/TR/excitations]) and axial SE T2-weighted images (3000/80–120/1). Follow-up MR studies included axial SE T1-weighted images (360–500/15/2) and T2-weighted images (3000/80–110/1), as well as coronal fast SE T2-weighted images (4000–5000/80–136; echo train length, 7–15) and/or SE T1-weighted images (450–500/15/2). Gradient-echo sequences were not performed. All MR studies were reviewed retrospectively by one neuroradiologist without knowledge of the clinical outcome.

The following four MR findings were evaluated in both premature and term infants: deep gray matter involvement; hemispheric parenchymal change; intracranial hemorrhage, in-

cluding subependymal hemorrhage (SEH); and periventricular signal alterations and/or morphologic changes. Because of the length of time between birth and the initial MR study, SEH was defined as either focal periventricular hemosiderin deposits and/or hemosiderin accumulation along the ventricular wall as evidence of intraventricular hemorrhage (IVH). Although it is controversial how periventricular leukomalacia (PVL) should be defined on MR studies, periventricular signal or morphologic alterations in premature infants have been generally presumed to be sequelae of PVL. Therefore, for this study, we tentatively considered all patients with bilateral periventricular signal alterations on the initial MR studies to have “radiologic PVL.” On follow-up MR studies, end-stage PVL was defined as T2 signal change and periventricular white matter volume loss. Periventricular T2 prolongation alone was considered to be periventricular abnormal T2 prolongation.

A detailed neurologic assessment was performed by neurologists at the time of a follow-up MR study. The assessment included a description of the type of cerebral palsy, presence of epilepsy, any EEG abnormality, and an estimate of developmental delay. Developmental delay was diagnosed when overt clinical delay in development was observed in the patient and/or when the developmental quotient score (examined by the Mother-Child Counseling Test by Cattell [adapted for Japanese children] or the Tsumori-Inage Developmental Test, Tokyo, Japan) was under 70.

Results

Premature Infants

In the 15 premature infants studied, the mean gestational age was 28 weeks and the mean birth weight

TABLE 1: Continued

Initial MR Imaging (Continued)		Radiologic PVL		Follow-Up MR Imaging	
Parenchymal Change	Type of Hemorrhage	Signal abnormality	Irregularity of LV	Age (mo) at Scan: PCA (CA)	Findings
...	...	Short T1, short T2	+	14 (18)	End-stage PVL
...	SEH	Short T1	—	20 (23)	SEH, end-stage PVL
...	SEH, IVH	Short T1, short T2	—	11 (14)	SEH, PV long T2
	ventriculomegaly				
R-frontal cortical infarction	SEH	Short T1, short T2	+, PV cyst	13 (16)	End-stage PVL, old infarction
...	SEH, IVH	...	—	44 (47)	Normal
...	...	Short T1, short T2	+, PV cyst	22 (25)	End-stage PVL
...	...	Short T1, short T2	+, PV cyst	15 (18)	End-stage PVL
...	SEH, PV cyst, IVH, ventriculomegaly	Short T1, short T2	—	12 (15)	SEH with PV cyst, end-stage PVL, ventriculomegaly
...	...	Short T1, short T2	+, PV cyst	21 (24)	End-stage PVL
...	SEH, PV cyst, IVH, ventriculomegaly	...	—	12 (15)	SEH with PV cyst, end-stage PVL, ventriculomegaly
...	...	Short T1, short T2	—	26 (28)	End-stage PVL
...	...	Short T1, short T2	+, PV cyst	11 (13)	End-stage PVL, equivocal myelination delay
...	...	Short T1, short T2	—	12 (14)	PV long T2
R-MCA hemorrhagic infarction	SDH	Short T1, short T2	+	14 (16)	End-stage PVL, old infarction
...	SEH, PV cyst, IVH, SAH, ventriculomegaly	...	—	31 (33)	SEH with PV cyst

was 1221 g. The initial MR studies were performed between 35 and 45 weeks postconceptional age or 3 to 18 weeks after birth. The average age at initial MR study was 39 weeks postconceptional age, or 10 weeks after birth, and the follow-up MR examinations were performed between 11 and 44 months postconceptional age (average, 18 months).

The clinical and radiologic features of these infants are summarized in Table 1. We did not note the presence or absence of asphyxia but described clinical symptoms, because asphyxia is difficult to assess in premature infants. We believe, however, that most of the infants had birth asphyxia. Indeed, 13 of 15 patients were neurologically abnormal at the time of final clinical assessment. Neurologic deficits included cerebral palsy (n = 12), developmental delay (n = 4), and epilepsy or EEG abnormalities (n = 5). Two patients had all three abnormalities, three had both cerebral palsy and epilepsy, and one had cerebral palsy and developmental delay. Developmental delay alone was observed in only one patient.

Of the MR imaging features evaluated, we found no evidence of deep gray matter involvement, diffuse hemispheric parenchymal changes, or intracerebral hemorrhage on the initial MR studies. Thus, the MR findings that were appreciated on the initial MR studies were SEH or subdural hemorrhage (SDH), periventricular signal alterations and/or morphologic changes (radiologic PVL), or cerebral infarctions recognized as focal hemispheric parenchymal changes. On the basis of the initial MR findings, the 15 pre-

mature infants were divided into three groups: three with SEH alone, seven with radiologic PVL alone, and three with both SEH and radiologic PVL. Two patients had additional abnormalities of cerebral infarction and/or SDH: one with radiologic PVL, infarction, and SDH, and the other with SEH, radiologic PVL, and cortical infarction of a middle cerebral artery (MCA) territory.

Follow-up MR examinations revealed only one healthy patient and 14 patients with abnormal findings. The following abnormalities were documented in the latter 14 patients: late sequelae of SEH with parenchymal destruction alone (n = 1), periventricular T2 prolongation alone (n = 1), end-stage PVL alone (n = 6), SEH and periventricular T2 prolongation (n = 1), SEH and end-stage PVL (n = 1), parenchymal destruction from SEH and end-stage PVL (n = 2), and end-stage PVL and cerebral infarction (n = 2). No patient had apparent delayed myelination; only one follow-up MR study of the patient with end-stage PVL revealed equivocal delayed myelination. Below we outline each set of the imaging findings on the basis of the initial MR studies, which are related to the follow-up MR studies and clinical outcome.

Hemispheric Parenchymal Changes.—Initial diffuse hemispheric parenchymal abnormalities were not identified in any patient, but focal cerebral infarction was found in two patients with radiologic PVL on the initial MR studies, one with disseminated intravascular coagulation showing hemorrhagic infarction of the

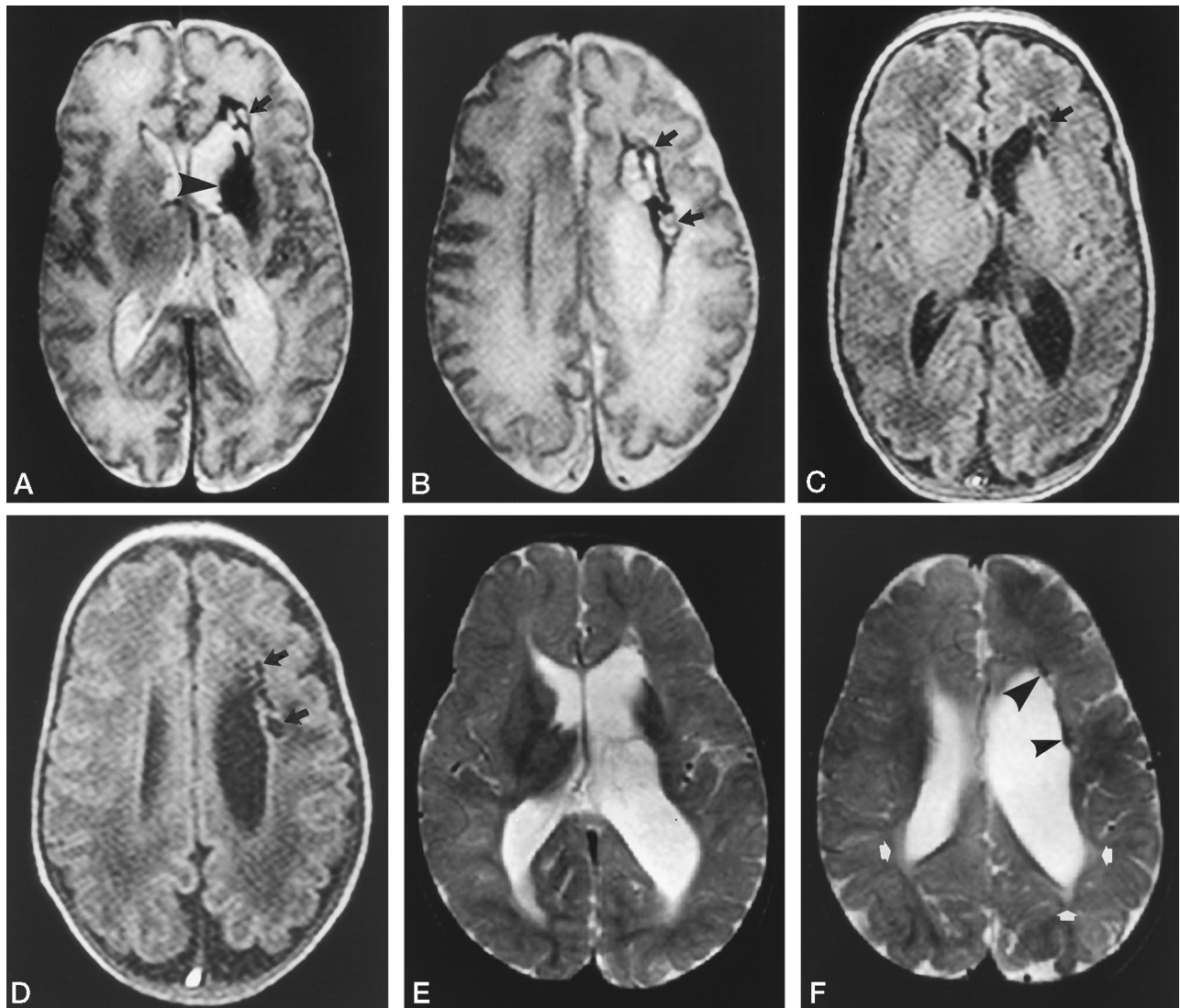


FIG 1. Patient 10: 28-week-old 1355-g infant.

Initial MR images, *A* and *B* (T2-weighted SE [3000/120/1]) and *C* and *D* (T1-weighted SE [400/15/2]), at 38 weeks corrected age show large germinal matrix region hemosiderin deposit (*arrowhead*) with adjacent multiple encephaloclastic cysts (*arrows*), diffuse hemosiderin deposition along the lateral ventricle, ventriculomegaly, and absence of periventricular parenchymal signal change.

Follow-up MR images, *E* and *F* (T2-weighted SE [3000/100/1]), at 12 months corrected age reveal right periventricular hemosiderin deposition (*arrowheads*), ventriculomegaly, and parenchymal destruction involving the left deep gray matter. Also note the periventricular T2 prolongation (*arrows*) with white matter volume loss. The infant developed a spastic diplegia with hemiparesis.

right posterior MCA territory with deep white matter involvement, SDH, and radiologic PVL with subtle irregularity of the ventricular wall, and the other with a small cortical infarction of the right MCA territory and radiologic PVL with periventricular cysts. On the follow-up MR studies, both had radiologic evidence of old infarction. The first patient was found to have end-stage PVL on follow-up imaging, with spastic diplegia associated with a mild hemiparesis and developmental delay, while the second had end-stage PVL with only spastic diplegia and epilepsy.

Intracranial Hemorrhage.—On the initial MR studies, no patient had primary intraparenchymal hemorrhage or subarachnoid hemorrhage (SAH). One had SDH, which disappeared on the follow-up MR study, accompanied by MCA infarction and radiologic PVL, as described above.

Seven had evidence of SEH, which was depicted as focal periventricular hemosiderin alone in two patients, and five had both hemosiderin deposits and IVH. Four of these five patients also had ventriculomegaly. On follow-up MR studies, the hemosiderin deposits were absent in two and less conspicuous in five patients (Fig 1). Among the four patients who initially had ventriculomegaly, two showed consistent ventriculomegaly. Associated adjoining encephaloclastic cysts were revealed in three of the seven patients with SEH on the initial MR studies, and all patients sustained tissue loss (Fig 1) and a spastic hemiparesis. However, four patients with hemosiderin deposits alone on the initial MR studies did not have spastic hemiparesis but had varied outcomes, depending on the accompanying abnormalities. One infant had periventricular T2 prolongation on the

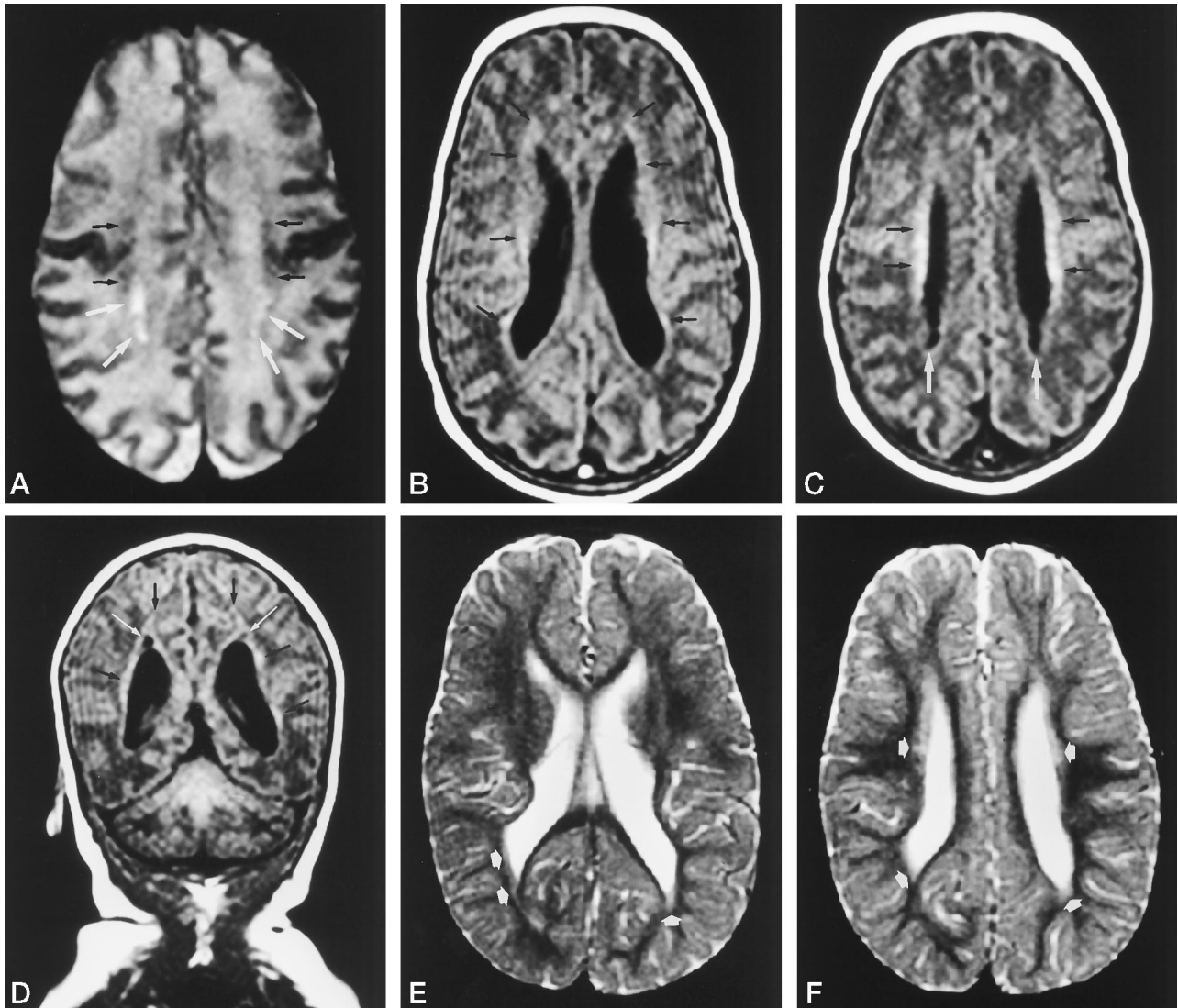


FIG 2. Patient 7: 28-week-old, 1100-g infant.

Initial MR images, A (T2-weighted SE [3000/120/1]) and B–D (T1-weighted SE [400/15/2]), at 38 weeks corrected age show multiple spots of periventricular T1 and T2 shortening (*black arrows*) with cyst formation (*white arrows*) and an irregular contour to the ventricular wall.

Follow-up MR images, E and F (T2-weighted SE [3000/100/1]), at 15 months postconceptional age reveal marked irregularity of the ventricular wall, white matter loss, and periventricular T2 prolongation (*arrows*). The infant developed a spastic diplegia.

follow-up MR study and had a normal clinical outcome, one had end-stage PVL and spastic diplegia, one had end-stage PVL with cortical infarction and spastic diplegia with developmental delay, and one had normal MR findings and developmental delay without cerebral palsy.

Periventricular Abnormalities (Radiologic PVL).—Periventricular T1 and/or T2 shortening was shown in 12 of 15 patients on the initial MR studies, meeting our radiologic criteria for suspected PVL (radiologic PVL) (Figs 2 and 3). T1 and/or T2 shortening alone was shown in five patients (Fig 3), whereas seven were associated with bilateral irregularities of the ventricular wall (five with multiple periventricular cysts [Fig 2] and two with irregularities of the ventricular wall alone). All 12 patients had periventricular T2 prolongation on the follow-up MR studies with or without white matter volume loss, and all seven with either

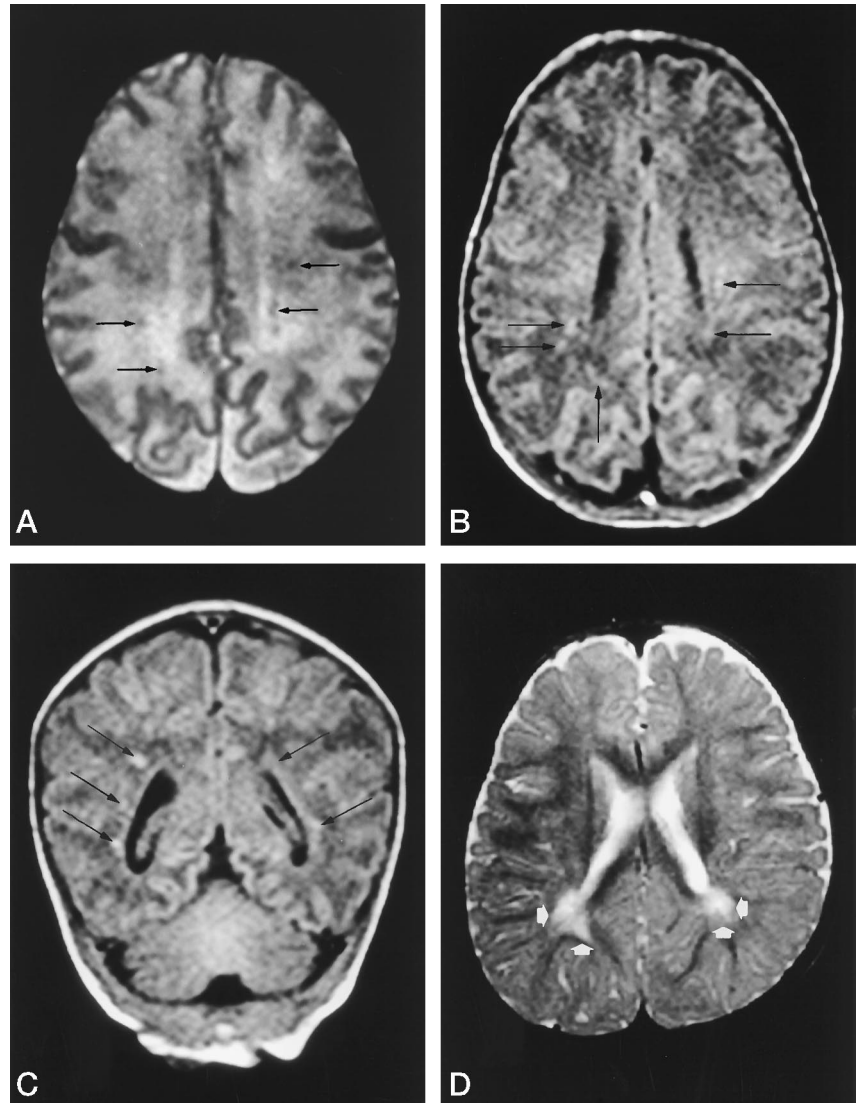
ventricular wall irregularity and/or cysts had end-stage PVL on the follow-up MR studies, with associated spastic diplegia or quadriplegia (Fig 2). Among these patients, three had epilepsy, one had developmental delay, and two had both. The five patients without initial MR evidence of periventricular white matter destruction had two outcomes: two had periventricular T2 prolongation on the follow-up MR studies despite a normal neurologic outcome (Fig 3), while three had end-stage PVL on follow-up MR studies and incurred a spastic diplegia.

A hybrid of SEH and end-stage PVL was evident in one exceptional patient, whose case we have not yet discussed. The initial MR study revealed only a prominent SEH and ventriculomegaly (Fig 1), without evidence of radiologic PVL. End-stage PVL was evident on the follow-up MR study (Fig 1), and a spastic diplegia with hemiparesis developed.

FIG 3. Patient 13: 31-week-old, 1735-g infant.

Initial MR images, *A* (T2-weighted SE [3000/120/1]) and *B* and *C* (T1-weighted SE [400/15/2]), at 36 weeks corrected age show multiple spots of periventricular T1 and T2 shortening (arrows) without abnormalities of the ventricular wall.

Follow-up MR image, *D* (T2-weighted SE [3000/100/1]), at 12 months corrected age shows peritrigonal T2 prolongation (arrows) without loss of white matter. The infant was clinically normal.



Term Infants

In the 15 term infants studied, the mean gestational age was 39 weeks (range, 35 to 42 weeks), while the mean birth weight was 2974 g (range, 1873 to 3575 g). The initial MR studies were performed an average of 12 days after birth (range, 0 to 27 days), and the follow-up clinical and MR examinations were performed between the ages of 11 months and 3 years (mean, 15 months).

The clinical and radiologic findings of these infants are summarized in Table 2. In this group, the presence of perinatal asphyxia was readily determined on the basis of clinical criteria. Follow-up neurologic assessment was abnormal in only four of 15 patients and included cerebral palsy ($n = 4$), developmental delay ($n = 3$), and epilepsy or EEG abnormalities ($n = 4$). Three patients had all three abnormalities, and one had spastic hemiparesis and epilepsy.

On the basis of the initial MR findings, the 15 patients can be divided into four overlapping groups: nine with deep gray matter abnormalities; seven with hemispheric parenchymal changes, both diffuse and

focal; four with intracranial hemorrhage; and three with periventricular signal changes.

Follow-up MR examinations showed nothing abnormal in four patients and revealed abnormalities in 11. Persistent signal alterations and atrophy of the deep gray matter were seen in three of nine patients with initial deep gray matter changes, with delayed myelination in two. Radiologic sequelae were noted in all seven patients with parenchymal injuries, but only one infant with diffuse T1 and T2 prolongation on the initial MR study developed multicystic encephalomalacia. Two of three patients with initial intracerebral hemorrhage had atrophy or hemosiderin in the affected area, and no radiologic sequelae were found in patients with SDH, SAH, or IVH. The spotty T1 and/or T2 shortening in the periventricular white matter found in three infants later evolved into T2 prolongation. Again, we detail each set of findings on the basis of the initial MR studies and relate them to the follow-up MR studies and clinical outcome.

Deep Gray Matter Involvement.—Deep gray matter involvement was identified in nine infants, with two

patterns of MR signal changes: six had T1 shortening alone (Fig 4) and three had T1 shortening and T2 signal changes, including both shortening and/or prolongation (Figs 5 and 6). The three patients with T2 signal alteration had more extensive T1 signal changes than the remaining six. On the follow-up MR studies, the group of six had normal T1 signal and normal deep gray matter volume (Fig 4). The second group of three showed persistent T1 and T2 signal abnormalities along with atrophy of the deep gray matter (Figs 5 and 6). Clinical evaluation indicated that the first group was neurologically normal, whereas the second group had cerebral palsy, developmental delay, and epilepsy.

Hemispheric Parenchymal Change.—The seven infants with hemispheric parenchymal signal changes were divided into two groups. First, four of seven patients with deep gray matter changes had hemispheric signal changes of the cortex and subcortical white matter. One of these four patients with diffuse hemispheric T1 and T2 prolongation on the initial MR studies developed multicystic encephalomalacia. In the remaining three patients, all of whom had perirolandic involvement, neurologic outcome was not related to the hemispheric lesions but rather to the associated deep gray matter signal changes. A normal neurologic outcome ensued in one patient with only basal ganglia T1 shortening, whereas cerebral palsy, developmental delay, and epilepsy developed in two patients with basal ganglia T2 signal changes (Fig 6).

Evidence of MCA infarctions without additional MR changes was found in the remaining three infants. The left MCA was affected in all, and the insult was seen on the initial MR studies as T1 and T2 prolongation with blurred border zones between the gray and white matter. Total involvement of the MCA territory, including perforators, was shown in one infant, while two had lesions restricted to the temporal region. Radiologic evidence of old infarction was found on the follow-up MR studies in all three, but the only neurologic abnormality detected at clinical examination was a mild hemiparesis and epilepsy in the patient with a total MCA infarction.

Intracranial Hemorrhage.—Evidence of both SDH and intracerebral hemorrhage in the temporal lobe, frontal lobe, or the cerebellum was detected in three infants, and one had SDH accompanied by left temporal infarction. These infants did not have deep gray matter signal abnormalities. The follow-up MR studies showed subtle intraparenchymal hemosiderin deposits with mild volume loss in two patients and no radiologic sequelae of hemorrhage in two; all patients were clinically normal.

Periventricular Signal Alterations.—On the initial MR studies, three of 15 patients (two with T1 shortening in the deep gray matter [Fig 4] and one with cerebellar hemorrhage) had spotty areas of T1 and/or T2 shortening in the periventricular white matter identical to our initial radiologic criteria for PVL in premature infants. These changes evolved into T2 prolongation on follow-up MR studies, and all three

patients were clinically normal (Fig 4). The evolution of these signal alterations was radiologically identical to those of radiologic PVL in premature infants (Fig 3), and no patient sustained white matter volume loss.

Discussion

The early recognition, prompt medical intervention, and accurate prognostic prediction of perinatal brain damage are particularly important to decrease morbidity and mortality in affected infants. Although there have been a number of imaging studies that emphasize the close relationship between late radiologic sequelae and clinical outcome (9, 12–15), very few reports have focused on early MR findings and their relationship to the radiologic sequelae and clinical neurologic assessment (5, 8). In this study, we evaluated the relationship among early initial MR findings, late follow-up MR findings, and neurologic outcomes in both premature and term infants with perinatal brain injuries and found that several MR findings closely correlated with the neurologic sequelae, including deep gray matter involvement, hemispheric parenchymal changes, intracranial hemorrhage, and PVL. We discuss each imaging finding and its clinical and radiologic implication.

Deep Gray Matter Involvement

The deep gray matter has been thought to be vulnerable to selective neuronal necrosis as a result of acute total asphyxia (16, 17). In our series, the deep gray injury was commonly found in term infants, as has been reported in the recent literature (18, 19), whereas it was not seen at all in premature infants. This may represent a selection bias of this study, which excluded premature infants with profound total asphyxia because of their early demise and severe morbidity, precluding the initial and/or late MR studies (18, 19).

On the initial MR studies, deep gray matter involvement was depicted as T1 shortening in nine patients and as T2 signal alterations in a subset of three. T1 shortening in the deep gray matter has been attributed to acute and subacute hemorrhage. In contrast, T2 signal alterations in the deep gray matter are reported to manifest as T2 shortening 6 to 10 days after hypoxic-ischemic injury, which argues against the signal change being caused by hemorrhage (18, 19). However, the T2 signal alterations in our series were inconsistent with previous reports. Among our three patients, one underwent serial MR imaging that revealed T2 shortening 0 and 3 days after injury and subsequent T2 prolongation by day 10. The remaining two patients underwent MR imaging on only one occasion, and T2 prolongation was revealed 16 and 27 days, respectively, after injury. This T2 signal evolution is consistent with microhemorrhage changing from deoxyhemoglobin to methemoglobin. Thus, the T2 signal alteration in these patients may be attributed to microhemorrhage associated with hypoxic-

TABLE 2: Clinical and Radiological Findings of Term Infants with Perinatal Brain Damage

Patient	Clinical information			Outcome			Initial MR Imaging	
	Gestational Age at Birth (wk)/Birth Weight (g)	Apgar score (1/5)	Symptoms or Diagnosis	CP	EPI	DD	Age at Scan (days)	Abnormalities of Deep Gray Matter
16	35/1873	2/5	HIE grade II	Quadriparesis	+	+	16	Short T1, short T2, long T2 in L and Th
17	36/2862	1/3	HIE grade I	...	-	-	4, 20	Short T1 in L
18	38/2800	8/?	Asphyxia	...	-	-	14	Short T1 in L
19	38/2900	7/10	Hypertonicity	...	-	-	8, 19	...
20	38/3202	3/3	Asphyxia	Quadriparesis, athetosis	+	+	27	Short T1, long T2 in L and Th
21	39/3575	1/1	HIE grade I	...	-	-	5, 11	Short T1 in L
22	40/2343	?	Thrombocytopenia	...	-	-	11	...
23	40/2862	10/?	Seizure	...	-	-	11	...
24	40/2890	7/9	Poor feeding, fever	...	-	-	10	...
25	40/3168	9/7	HIE grade I, MAS	...	-	-	11	Short T1 in L and Th
26	40/3260	8/?	Asphyxia	Quadriparesis, athetosis	+	+	0, 3, 10, 27	Short T1, short and/or long T2 in L and Th
27	40/3370	9/10	Seizure	...	-	-	13	...
28	40/3392	5/6	Asphyxia	...	-	-	6	Short T1 in L
29	42/3000	6/7	Asphyxia, PPHN, MAS	...	-	-	11	Short T1 in L and Th
30	42/3120	7/7	Seizure	R hemiparesis	+	-	6, 17	...

Note.—HIE indicates hypoxic-ischemic encephalopathy; PPHN, primary pulmonary hypertension of neonates; MAS, meconium aspiration syndrome; CP, cerebral palsy; EPI, epilepsy; DD, developmental delay; L, lenticular nuclei; Th, thalami; MCA, middle cerebral artery; ICH, intracerebral hemorrhage; SDH, subdural hemorrhage; SAH, subarachnoid hemorrhage; IVH, intraventricular hemorrhage; PV, periventricular; R, right; Lt, left.

-ischemic injury of the deep gray matter, but the number of patients in our study is too small to definitively elucidate the precise cause. The conspicuity of T1 shortening in the deep gray matter greater than T2 shortening may simply be due to the relatively low background intensity of neonatal gray matter. Rutherford et al (8) reported that the extent of T1 shortening in the deep gray matter closely corresponded to the severity of neurologic deficit at follow-up. In contrast, our three patients with T2 signal change had severe clinical and radiologic sequelae, whereas the six patients with only T1 shortening had a favorable neurologic outcome and normal findings on follow-up MR studies. We speculate that milder injuries can be detected as T1 shortening, but that T2 signal changes are present with more severe injuries, causing a devastating neurologic outcome. In fact, all three cases with T2 signal alteration had more extensive T1 signal change than the remaining six patients. Thus, in infants with T1 shortening in the deep gray matter, meticulous MR imaging interpretation is required, and follow-up MR studies may be necessary to confirm the development of T2 prolongation.

Hemispheric Parenchymal Changes

Diffuse hemispheric parenchymal changes have been attributed to severe prolonged partial asphyxia (17, 20). In our series, no premature infant had such diffuse hemispheric changes. In the term infants with asphyxia, multicystic encephalomalacia ensued only in one patient, and typical parasagittal cerebral injury did not manifest in any patients, although deep gray matter involvement was shown in most term infants with asphyxia. These findings suggest a selection bias of this study, which included only infants in whom protracted asphyxia was prevented by prompt perinatal care.

Focal hemispheric change, or cerebral infarction, was found in both premature and term infants in our series. Infarction is considered to occur as a result of arterial occlusive diseases, and the left MCA territory is usually preferentially involved, as in our series of term infants (21). Cerebral infarction did not create significant neurologic deficits in either our premature or term infants unless periventricular parenchymal involvement or total involvement of the MCA territory was present. This observation implies that focal

TABLE 2: Continued

Initial MR Imaging (Continued)			Follow-Up MR Imaging	
Parenchymal Change	Type of Hemorrhage	PV Signal Abnormality	Age at Scan (mo)	Findings
Diffuse T1, T2 prolongation	28	Long T1, T2 and atrophy in L and Th multicystic encephalomalacia, delayed myelination
...	...	Short T1, short T2	11	PV long T2
Short T1 in the perirolandic region and optic pathway	12	Long T2 in the optic pathway
...	Cerebellar ICH, SDH, ventriculomegaly	Short T1	11	Old cerebellar hemorrhage, PV long T2
Short T1, short T2, long T2 in the perirolandic region	36	Long T1, T2 and atrophy in L and Th long T1, T2 and atrophy in the perirolandic region
...	12	Normal
...	R temporal ICH, SDH, SAH	...	11	Normal
Lt temporal infarction	SDH	...	12	Old temporal infarction
...	R frontal ICH, IVH, SDH	...	16	Long T2 and volumeloss in the right frontal region
...	...	Short T1, short T2	12	PV long T2
Short T1, T2 in the perirolandic region	15	Long T2 and mild atrophy in L and Th delayed myelination
Lt temporal infarction	12	Old temporal infarction
...	16	Normal
...	11	Normal
Entire Lt MCA infarction	12	Long T2 and atrophy in Lt Th, old MCA infarction

injuries to the cerebral hemisphere tend to be functionally compensated for.

SEH and Other Intracranial Hemorrhage

SEH is one of the common sequelae in premature infants (17, 22), and was readily depicted on the initial MR studies as periventricular hemosiderin deposits and/or evidence of IVH and as areas of hemosiderin in some cases on the follow-up MR studies. The rate of occurrence of SEH may be underestimated in our series because we did not use a gradient-echo sequence, which is usually more sensitive to hemosiderin than is SE imaging.

Parenchymal encephaloclastic cysts adjacent to hemosiderin deposits as a result of SEH on the initial MR studies were considered to represent grade IV hemorrhage or hemorrhagic venous infarction (9, 22, 23). Such lesions led to parenchymal destruction and volume loss on follow-up MR studies. This combination of findings was present in three of our patients, all of whom developed a component of spastic hemiparesis, even if the affected area was small, suggesting that either the injury was more extensive than that imaged or the selective location of the injury affected the motor fibers and was easily detected clinically (22).

In our series, an unremarkable neurologic outcome was evident in all term patients with intracerebral hemorrhage at follow-up evaluation. As in cerebral

infarction, focal parenchymal damage seems to be functionally compensated for by the remaining brain. In both term and premature infants, SDH, SAH, IVH, or SEH without parenchymal destruction (hemosiderin deposit alone) did not predict unfavorable outcome.

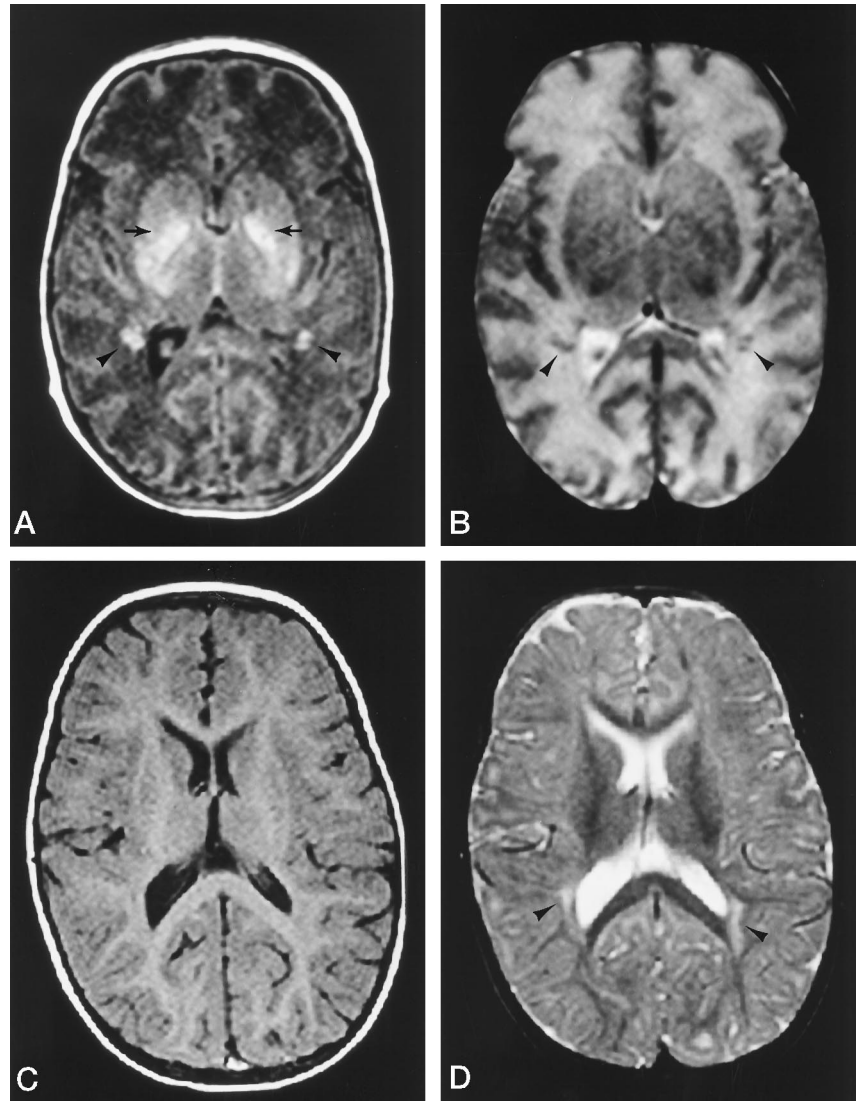
Radiologic PVL

T1 and T2 shortening in the periventricular white matter in premature infants have been reported extensively (2, 11). In our series, such MR signal changes were frequently present on the initial MR studies with or without cystic white matter injury or alteration in the contour of the ventricular wall, and we tentatively called this radiologic PVL. The precise causes of these signal changes on the initial MR studies remain unknown but may share the same causes of those in the deep gray matter. The signal changes are easily recognizable because the T1 and/or T2 shortening occurs against a background of white matter with much longer T1 and T2 values. The T1 and/or T2 shortening developed into T2 prolongation on the follow-up MR studies, occasionally without white matter volume loss or appreciable neurologic deficit. Periventricular T2 prolongation is regarded as a glial reaction, and very premature infants, especially before the third trimester, have been reported to have a limited capacity to mount a glial reaction, but rather

FIG 4. Patient 28: 40-week-old, 3392-g infant.

Initial MR images, A (T1-weighted SE [400/15/2]) and B (T2-weighted SE [3000/120/1]), at 6 days of age show bilateral T1 shortening in the lenticular nuclei (arrows) and spotty areas of T1 and T2 shortening in the periventricular white matter (arrowheads).

Follow-up MR images, C (T1-weighted SE [500/15/2]) and D (T2-weighted SE [3000/100/1]), at 16 months show normal-appearing deep gray matter but with spotty areas of T2 prolongation (arrowheads). The infant developed normally.



cavitate and destroy their white matter (17, 24). In our series, however, all infants born at or before 28 weeks gestation with radiologic PVL had some periventricular T2 prolongation rather than parenchymal destruction alone. The presence of bilateral periventricular parenchymal destruction in premature infants on the initial MR studies signified the development of end-stage PVL and a significant neurologic handicap. However, end-stage PVL also developed in infants with periventricular signal alterations alone, and even occurred in an infant who had SEH/IVH and ventriculomegaly on the initial MR study. Consequently, the initial MR findings provide significant, but limited, information in predicting the severity of a neurologic handicap associated with PVL. A drawback to our study is that we were only able to observe subacute changes of PVL even on the initial MR studies, and we may have missed early patterns of signal abnormalities that might be more predictive of outcome.

In our group of 15 term infants, three had spotty signal T1 and/or T2 shortening in the periventricular white matter on the initial MR studies, evolving into

T2 prolongation on the follow-up MR studies, typical of the MR signal changes described for PVL in premature infants. All three infants had a normal neurologic evaluation at follow-up and did not incur white matter volume loss. This spotty T1 and T2 shortening in the periventricular white matter has not come to light in previous studies on brain damage in term infants, although this finding may be identical to "patchy abnormal signal intensity within the periventricular white matter" in two asphyxiated infants with normal developmental sequelae described by Rutherford et al (8). These periventricular white matter lesions may conceivably represent "periventricular leukomalacia in term infants" as postulated by Volpe (25, 26).

The Relationship between Each MR Finding and Clinical Outcome

In the group of premature infants, four of the seven patients with SEH had evidence of PVL on the initial study, implying that SEH is often concurrent with PVL. The precise radiologic prevalence of SEH with

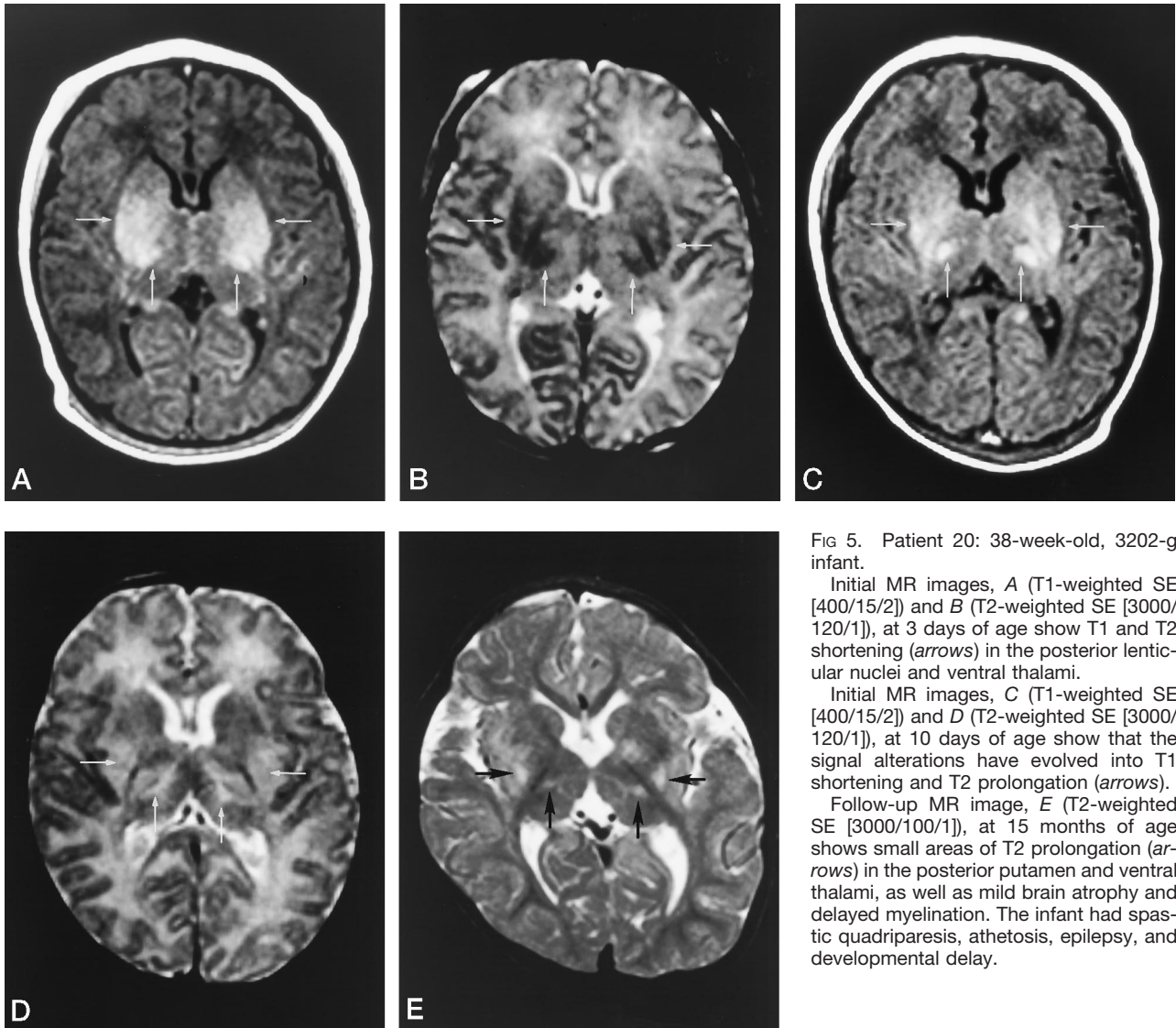


FIG 5. Patient 20: 38-week-old, 3202-g infant.

Initial MR images, A (T1-weighted SE [400/15/2]) and B (T2-weighted SE [3000/120/1]), at 3 days of age show T1 and T2 shortening (arrows) in the posterior lenticular nuclei and ventral thalami.

Initial MR images, C (T1-weighted SE [400/15/2]) and D (T2-weighted SE [3000/120/1]), at 10 days of age show that the signal alterations have evolved into T1 shortening and T2 prolongation (arrows).

Follow-up MR image, E (T2-weighted SE [3000/100/1]), at 15 months of age shows small areas of T2 prolongation (arrows) in the posterior putamen and ventral thalami, as well as mild brain atrophy and delayed myelination. The infant had spastic quadriplegia, athetosis, epilepsy, and developmental delay.

PVL is unknown to date, although the pathologic prevalence in severely affected infants has been reported in a few series (27).

In our series, poor neurologic outcome in premature infants was related to SEH associated with adjacent periventricular parenchymal destruction, PVL with periventricular volume loss, and widespread cerebral infarction. The MR findings were predictive of subtypes of cerebral palsy. As previously reported, hemorrhagic venous infarction or grade IV hemorrhage in severe cases of SEH and extensive cerebral infarction both led to spastic hemiparesis, whereas MR evidence of PVL was often associated with spastic diplegia (22, 26, 28). In addition, the patients with end-stage PVL and periventricular parenchymal destruction associated with SEH or cerebral infarction had the combination of spastic diplegia with hemiparesis. To our knowledge, the combination of two types of spastic cerebral palsy has not been well established. However, when considering the possible frequent coexistence of PVL and SEH, this combination is not surprising.

No MR findings were predictive of developmental delay or epilepsy (or EEG abnormalities) in premature infants. Patients with identical MR findings of PVL and SEH had variable outcomes. Seizures and developmental delay are thought to be caused by cortical injury (26), and although PVL and SEH primarily affect the deep white matter, small areas of cortical injury may also occur.

In our group of asphyxiated term infants, T2 signal alterations in the deep gray matter, diffuse hemispheric parenchymal changes, and extensive cerebral infarction predicted a poor neurologic outcome, including spastic quadriplegia and/or athetosis with epilepsy and developmental delay, and hemiparesis with epilepsy.

Myelination delay is a well-known finding in both term and preterm infants with perinatal brain damage (24). As noted above, the rate of occurrence of delayed myelination related to perinatal brain injury was lower than expected, particularly in premature infants.

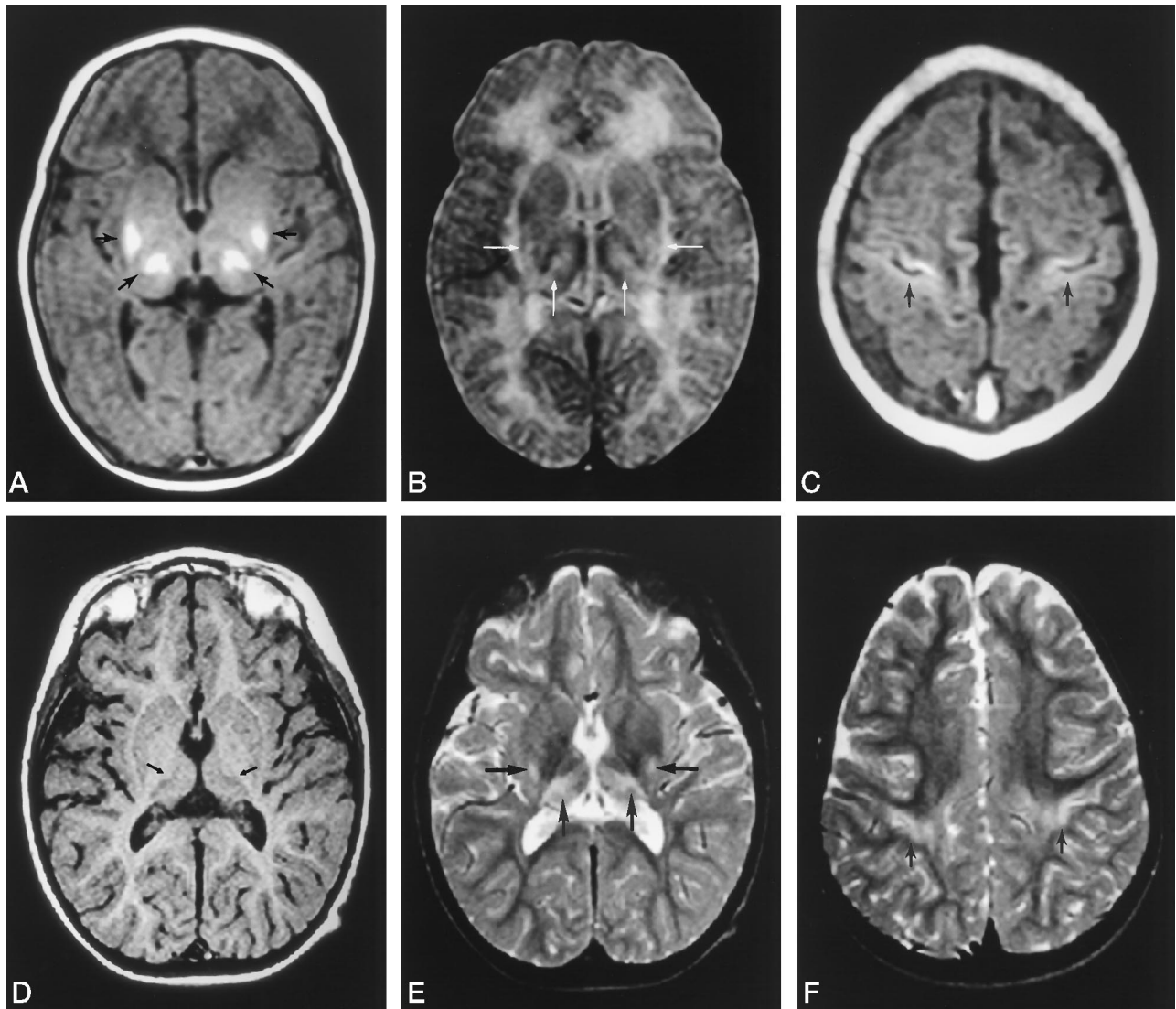


FIG 6. Patient 26: 40-week-old, 3260-g infant.

Initial MR images, *A* and *C* (T1-weighted SE [400/15/2]) and *B* (T2-weighted SE [3000/80/1]), at 27 days of age show T1 shortening (*black arrows*) and T2 prolongation (*white arrows*) in the posterior putamen and ventral thalami, with T1 shortening (*black arrows*) in the perirolandic cortices.

Follow-up MR images, *D* (T1-weighted SE [500/15/2]) and *E* and *F* (T2-weighted SE [3000/100/1]), at 3 years of age show that the signal alterations have evolved into T1 and T2 prolongation (*arrows*). The child was developmentally delayed and had spastic quadriplegia, athetosis, and epilepsy.

Conclusion

The complex constellation of early radiologic abnormalities in premature infants with CNS insults is a challenge for accurate radiologic interpretation. We found that periventricular parenchymal destruction in SEH, PVL, and MCA infarction on initial MR studies indicated not only the development of cerebral palsy but also its subtypes. Consequently, MR imaging at approximately 40 weeks corrected age may play a significant role in predicting neurologic outcomes. Some diagnostic limitations of the initial MR studies remain, particularly the development of end-stage PVL, probably because only subacute and chronic brain injuries were imaged, even with such early studies. This observation reinforces the idea that much earlier imaging may be well worth a clinical trial.

In term asphyxiated infants, T2 signal alterations of the deep gray matter, rather than T1 changes, were predictive of an unfavorable outcome. Similarly, diffuse involvement of the hemispheres on the initial MR studies was predictive of an unfavorable prognosis. The former finding is thought to represent selective neuronal necrosis of the deep gray matter as a result of total asphyxia, whereas the latter is the precursor of multicystic encephalomalacia as a result of severe protracted partial asphyxia. Thus, MR imaging at or near term is useful for predicting neurologic outcome in term infants with CNS injuries.

Acknowledgment

We thank K. J. Poskitt for his valuable comments.

References

- Keeney SE, Adcock EW, McArdle CB. **Prospective observations of 100 high-risk neonates by high-field (1.5 Tesla) magnetic resonance imaging of the central nervous system, I: intraventricular and extracerebral lesion.** *Pediatrics* 1991;87:421-430
- Keeney SE, Adcock EW, McArdle CB. **Prospective observations of 100 high-risk neonates by high-field (1.5 Tesla) magnetic resonance imaging of the central nervous system, II: lesions associated with hypoxic-ischemic encephalopathy.** *Pediatrics* 1991;87:431-438
- McArdle CB, Richardson CJ, Hayden CK, et al. **Abnormalities of the neonatal brain: MR imaging, I: intracranial hemorrhage.** *Radiology* 1987;163:387-394
- McArdle CB, Richardson CJ, Hayden CK, et al. **Abnormalities of the neonatal brain: MR imaging, II: hypoxic-ischemic brain injury.** *Radiology* 1987;163:395-403
- Baenziger O, Martin E, Steinlin M, et al. **Early pattern recognition in severe perinatal asphyxia: a prospective MRI study.** *Neuroradiology* 1993;35:437-442
- Kuenzle CH, Baenziger O, Martin E, et al. **Prognostic value of early MR imaging in term infants with severe perinatal asphyxia.** *Neuropediatrics* 1994;25:191-200
- Rutherford MA, Pennock JM, Schwieso JE, et al. **Hypoxic ischaemic encephalopathy: early magnetic resonance imaging findings and their evolution.** *Neuropediatrics* 1995;26:183-191
- Rutherford M, Pennock J, Schwieso J, et al. **Hypoxic-ischemic encephalopathy: early and late magnetic resonance findings in relation to outcome.** *Arch Dis Child* 1996;75:F145-F151
- Ford LM, Han BK, Steichen J, et al. **Very-low-birth-weight, preterm infants with or without intracranial hemorrhage: neurologic, cognitive and cranial MRI correlations at 4-8-year follow-up.** *Clin Pediatr (Phila)* 1989;28:302-310
- Barkovich AJ, Sargent SK. **Profound asphyxia in the premature infant: imaging findings.** *AJNR Am J Neuroradiol* 1995;16:1837-1846
- Schouman-Claeys E, Henry-Feugeas MC, Roset F, et al. **Periventricular leukomalacia: correlation between MR imaging and autopsy findings during the first 2 months of life.** *Radiology* 1993;189:59-64
- Flodmark O, Roland EH, Hill A, et al. **Periventricular leukomalacia: radiologic diagnosis.** *Radiology* 1987;162:119-124
- Baker LL, Stevenson DK, Enzmann DR. **End-stage periventricular leukomalacia: MR evaluation.** *Radiology* 1988;168:809-815
- Flodmark O, Lupton B, Li D, et al. **MR imaging of periventricular leukomalacia in childhood.** *AJNR Am J Neuroradiol* 1989;10:111-118
- Truit CL, Barkovich AJ, Koch TK, et al. **Cerebral palsy: MR findings in 40 patients.** *AJNR Am J Neuroradiol* 1992;13:67-78
- Myers RE. **Two patterns of brain damage and their conditions of occurrence.** *Am J Obstet Gynecol* 1972;112:246-276
- Barkovich AJ. **Destructive brain disorders of children.** In: *Pediatric Neuroimaging*. 2nd ed. New York: Lippincott-Raven; 1995:118-138
- Barkovich AL. **MR and CT evaluation of profound neonatal asphyxia.** *AJNR Am J Neuroradiol* 1992;13:959-972
- Barkovich AJ, Westmark K, Partridge C, et al. **Perinatal asphyxia: MR findings in the first 10 days.** *AJNR Am J Neuroradiol* 1995;16:427-438
- Pasternak JF. **Hypoxic-ischemic brain damage in the term infant: lessons from the laboratory.** *Pediatr Clin North Am* 1993;40:1061-1072
- Rollins NK, Morris MC, Evans D, et al. **The role of early MR in the evaluation of the term infant with seizures.** *AJNR Am J Neuroradiol* 1994;15:239-248
- Volpe JJ. **Intracranial hemorrhage: germinal matrix-intraventricular hemorrhage of the premature infants.** In: *Neurology of the Newborn*. 3rd ed. Philadelphia: Saunders; 1995:403-465
- Volpe JJ. **Brain injury in the premature infant: current concepts of pathogenesis and prevention.** *Biol Neonate* 1992;62:231-242
- Barkovich AJ, Truwit CL. **Brain damage from perinatal asphyxia: correlation of MR findings with gestational age.** *AJNR Am J Neuroradiol* 1990;11:1087-1096
- Volpe JJ. **Value of MR in definition of the neuropathology of cerebral palsy in vivo (commentary).** *AJNR Am J Neuroradiol* 1992;13:79-83
- Volpe JJ. **Hypoxic-ischemic encephalopathy.** In: *Neurology of the Newborn*. 3rd ed. Philadelphia: Saunders; 1995:211-372
- Armstrong DL, Sauls SD, Goddard-Finegold J. **Neuropathologic findings in short-term survivors of intraventricular hemorrhage.** *Am J Dis Child* 1987;141:617-621
- Menkes HJ. **Perinatal asphyxia and trauma.** In: *Textbook of Child Neurology*. 5th ed. Baltimore: Williams & Wilkins; 1995:325-378

Please see the Editorial on page 1809 in this issue.