

---

# Angiographic Demonstration of Reversible Cerebral Vasospasm in Porphyric Encephalopathy

Karen S. Black, Polly Mirsky, Peter Kalina, Rona Woldenberg Greenberg, Karl E. Drehobl, Melissa Sapan, and Eric Meikle

**Summary:** Using MR angiography and conventional angiography, we demonstrate that cerebral symptoms in porphyric encephalopathy are caused by transient vasoreactive ischemia, the result of reversible vasculopathy, reflected by vasospasm.

**Index terms:** Cerebral angiography; Metabolic disorder; Vasospasm

The porphyrias are rare inherited diseases of heme biosynthesis which can involve the central nervous system. The most frequent clinical manifestations are peripheral neuropathy and mental disturbance (1). Recent studies have proposed vasculopathy as a cause of reversible ischemia (2, 3). We report a case of reversible vasospasm in porphyric encephalopathy demonstrated by both magnetic resonance (MR) angiography and conventional angiography.

## Case Report

A 33-year-old woman with a strong family history of porphyria presented to the emergency department of an outside institution with diffuse abdominal pain. Diagnosed with a urinary tract infection, she was discharged and received antibiotics. The following day, the patient returned with persistent abdominal pain and was diagnosed with appendicitis. After undergoing an appendectomy, on postoperative day 1, she had her first seizure. Laboratory data were remarkable for hyponatremia, with a serum sodium level of 121 mEq/L. Treatment with hypertonic saline and dilantin was initiated, and the patient was discharged on postoperative day 5.

Two days later, the patient had a second seizure, associated with apraxia and confusion. At this time, because of her family history of porphyria, her urine porphobilinogen level was measured, which confirmed the diagnosis of porphyria. Transfer to our institution was arranged for further evaluation and treatment.

MR of the brain showed large regions of signal hyperintensity in the parietal cortex on the T2-weighted images. These areas of signal abnormality did not greatly enhance after intravenous contrast infusion and were thought to be ischemic in origin (Fig 1A and B). MR angiography revealed narrowing of the A1 segments of the anterior cerebral arteries bilaterally, the pericallosal arteries, and the left middle cerebral artery (Fig 1C).

Cerebral angiography was performed 3 days later to evaluate better the cerebral vasculature, and it confirmed the MR angiographic findings. On the right, there was smooth narrowing of the supraclinoid segment of the internal carotid artery, as well as the A1 (horizontal) and A2 (interhemispheric) segments of the anterior cerebral artery (Fig 1D). On the left, smooth narrowing of the supraclinoid internal carotid artery, the M1 segment of the middle cerebral artery, and the A1 segment of the anterior cerebral artery was demonstrated (Fig 1E). Tapered narrowing of the vessels, as opposed to beading or skip areas, in combination with involvement of proximal as opposed to distal vessels, favored vasospasm over vasculitis.

Hematin therapy was begun, and after 4 days the patient's neurologic symptoms markedly improved, the only residua being fine-motor difficulty. MR and MR angiography were repeated. The MR angiography revealed almost complete resolution of the vasospasm (Fig 1F). The repeat MR, however, showed parietal foci of signal hyperintensity on T2-weighted images with patchy enhancement after contrast infusion, consistent with subacute infarcts (Fig 1G and H).

## Discussion

The porphyrias are an inherited group of inborn errors of metabolism characterized by enzyme defects in heme biosynthesis (4). Excess porphyrin production results in the typical neurologic symptoms. Acute intermittent porphyria is the most common of the inducible porphyrias

---

Received August 4, 1994; accepted after revision December 5.

From the Department of Radiology, North Shore University Hospital-Cornell University Medical College, Manhasset, NY (K.S.B., P.M., P.K., R.W.G., K.E.D., M.S.); and Cornell University Medical College, New York, NY (E.M.).

Address reprint requests to Karen S. Black, MD, Department of Radiology, North Shore University Hospital-Cornell University Medical College, 300 Community Dr, Manhasset, NY 11030.

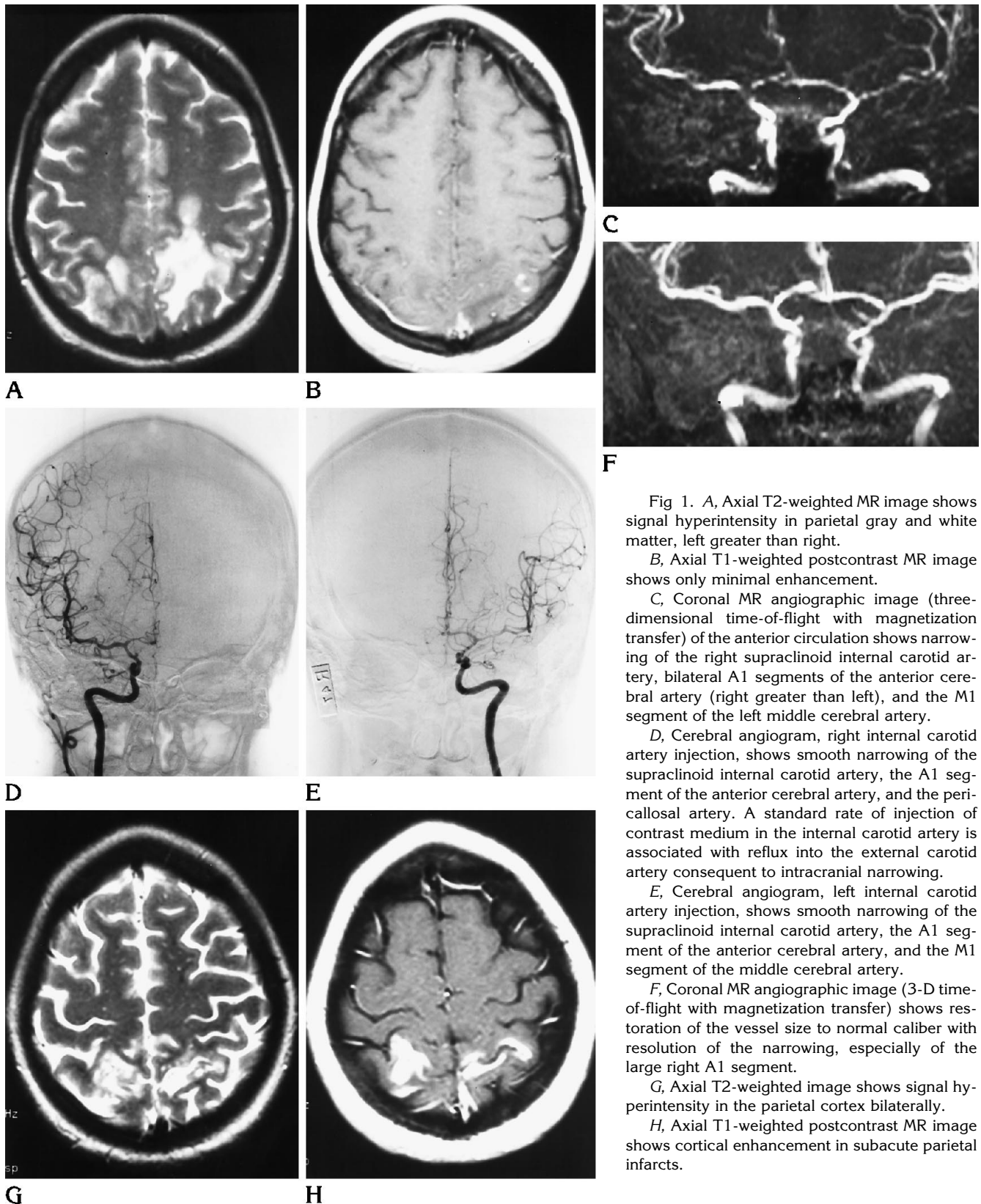


Fig 1. A, Axial T2-weighted MR image shows signal hyperintensity in parietal gray and white matter, left greater than right.

B, Axial T1-weighted postcontrast MR image shows only minimal enhancement.

C, Coronal MR angiographic image (three-dimensional time-of-flight with magnetization transfer) of the anterior circulation shows narrowing of the right supraclinoid internal carotid artery, bilateral A1 segments of the anterior cerebral artery (right greater than left), and the M1 segment of the left middle cerebral artery.

D, Cerebral angiogram, right internal carotid artery injection, shows smooth narrowing of the supraclinoid internal carotid artery, the A1 segment of the anterior cerebral artery, and the pericallosal artery. A standard rate of injection of contrast medium in the internal carotid artery is associated with reflux into the external carotid artery consequent to intracranial narrowing.

E, Cerebral angiogram, left internal carotid artery injection, shows smooth narrowing of the supraclinoid internal carotid artery, the A1 segment of the anterior cerebral artery, and the M1 segment of the middle cerebral artery.

F, Coronal MR angiographic image (3-D time-of-flight with magnetization transfer) shows restoration of the vessel size to normal caliber with resolution of the narrowing, especially of the large right A1 segment.

G, Axial T2-weighted image shows signal hyperintensity in the parietal cortex bilaterally.

H, Axial T1-weighted postcontrast MR image shows cortical enhancement in subacute parietal infarcts.

in the United States, with a gene prevalence of 1 in 10 000 to 1 in 20 000. It is most common in people of Scandinavian, British, and Irish descent (5).

The gene defect does not usually become manifest until puberty, from which time the clinical course is variable. During acute attacks, there is increased urinary excretion of the porphyrin precursors. Abdominal pain is typical and is related to autonomic nerve dysfunction. Other indications of autonomic nerve dysfunction include tachycardia, labile hypertension, and peripheral motor and sensory dysfunction. Central nervous system involvement is common and may present as irritability, behavior changes, psychosis, and hallucinations. Seizures occur in 20% of acute attacks. However, abnormal electroencephalograms may occur in the absence of seizure activity. Organic brain syndrome often develops if an attack progresses. Eventually, somnolence and coma may result (5).

King et al (3) suggested vasospasm as a cause of the neurologic complications of this disorder. In May 1994, Aggarwal et al (2) demonstrated transient cerebral cortical changes on MR, which resolved on follow-up imaging. The findings in our patient document reversible arterial narrowing, which results in ischemia and infarction. The initial MR angiogram and cerebral angiogram showed diffuse vasospasm. The

follow-up MR angiogram, performed 2 weeks later when neurologic symptoms had improved, showed essentially complete resolution of these findings. The brain MR at this time revealed subacute infarcts.

We have been able to show evidence supporting the theory proposed in earlier reports that cerebral symptoms in porphyric encephalopathy are caused by transient vasoreactive ischemia, caused by a reversible vasculopathy reflected by vasospasm. Although past reports have demonstrated reversible ischemic lesions on MR (2, 3), the extensive vasculopathy in our patient led to infarction rather than ischemia. The underlying vascular problem, however, did resolve, as documented with MR angiography.

## References

1. Meyer UA. Porphyrins. In: Braunwald E, Isselbacher KJ, Petersdorf RG, Wilson JD, Martin JB, Fauci AS, eds. *Harrison's Principles of Internal Medicine*. 11th ed. New York: McGraw-Hill, 1987:1638-1643
2. Aggarwal A, Quint DJ, Lynch JP III. MR imaging of porphyric encephalopathy. *AJR Am J Roentgenol* 1994;162:1218-1220
3. King PH, Bragdon AC. MRI reveals reversible cerebral lesions in an attack of acute intermittent porphyria. *Neurology* 1991;41:1300-1302
4. Lip GYH, McColl KEL, Moore MR. The acute porphyrias. *Br J Clin Pharmacol* 1993;47:38-43
5. Bloomer JR, Straka JG, Rank JM. In: Schiff L, Schiff ER, eds. *Diseases of the Liver*. 7th ed. Philadelphia: JB Lippincott, 1993: 1438-1458