

# The Hypoglossal Canal: Normal MR Enhancement Pattern

Frank Voyvodic, Andrew Whyte, and John Slavotinek

**PURPOSE:** To review the anatomy of the hypoglossal canal and present the normal precontrast and postcontrast MR appearance of axial posterior fossa images. **METHODS:** Thirty-one axial MR examinations of the normal posterior fossa were retrospectively reviewed. **RESULTS:** The hypoglossal canals are well seen on 3-mm-thick axial MR images of the posterior fossa (28[90%] of 31 patients). Symmetric intense intracanalicular enhancement after intravenous administration of gadopentetate dimeglumine is routine, typically with minor anterior extension into the nasopharyngeal region (28 [100%] of 28). A linear filling defect traversing the enhanced canal often is seen (21 [75%] of 28) and may represent hypoglossal nerve rootlets. Circumferential enhancement of the meninges at the level of the foramen magnum was a common finding (19 [64%] of 28). **CONCLUSION:** Enhancement within the hypoglossal canal with anterior extension beneath the skull base is a normal finding. This pattern is characteristic enough on MR imaging to aid interpretation of skull base lesions and to exclude the possibility of a mass within the hypoglossal canal.

**Index terms:** Posterior fossa, magnetic resonance; Skull, anatomy

*AJNR Am J Neuroradiol* 16:1707-1710, September 1995

The hypoglossal (or anterior condyloid) canal is a paired bone passage that runs lateral to and slightly forward from the posterior cranial fossa to the nasopharyngeal carotid space and transmits the hypoglossal nerve. The plain x-ray and computed tomography (1-3) appearances of the hypoglossal canal have been described, as has the magnetic resonance (MR) appearance (4, 5), although not necessarily in detail.

The excellent contrast resolution and multiplanar imaging capability of MR imaging facilitates the evaluation of skull base disease. In many cases, the use of intravenous contrast agents such as gadopentetate dimeglumine further improves assessment. Knowledge of the normal precontrast and postcontrast appearance and anatomic variations of the skull base and its foramina has therefore become increasingly important.

This study reviews the anatomy of the hypoglossal canal and presents the axial MR appearance and contrast enhancement pattern.

## Method

Thirty-one consecutive MR examinations with normal findings, done for investigation of sensorineural hearing loss at Flinders Medical Centre between September 1993 and April 1994, were assessed. All examinations were performed on a Siemens Impact 1.0-T unit (Ehrlagen, Germany).

The patients included 19 men and 12 women with a median age of 52 years (range, 29 to 70 years). Patients were imaged in a head coil. All studies included precontrast and postcontrast (10 mL gadopentetate dimeglumine) T1-weighted spin-echo sequences (600/15/3 [repetition time/echo time/excitations]) with a 20-cm field of view, 3-mm section thickness, 10% intersection gap, and a 192 × 256 matrix. Axial sections were obtained from just above the foramen magnum to the level of the third ventricle. Three-millimeter coronal sections extended from the dorsum sellae to include the entire posterior fossa.

In a retrospective analysis, the presence or absence of canal visibility, symmetry, posterior fossa dural enhancement, anterior extension of enhancement, and a linear filling defect within the canal were independently evaluated by two radiologists with good interobserver agreement (94%). The intensity of canal enhancement was graded as 1 (equivalent to adjacent vascular structures), 2

---

Received November 2, 1994; accepted after revision April 7, 1995.

From the Department of Radiology, Flinders Medical Centre, Bedford Park, South Australia.

Address reprint requests to Dr J. P. Slavotinek, Department of Radiology, Flinders Medical Centre, Bedford Park, 5042, South Australia.

*AJNR* 16:1707-1710, Sep 1995 0195-6108/95/1608-1707

© American Society of Neuroradiology

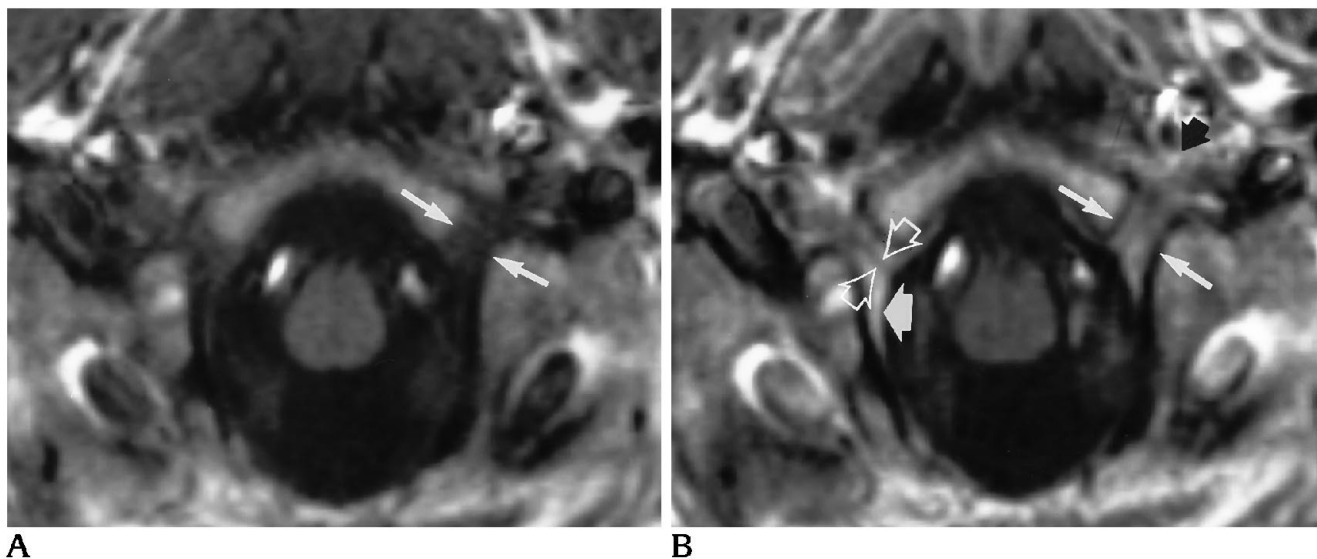


Fig 1. Normal hypoglossal canal. *A*, Spin-echo T1-weighted, 600/15/3 noncontrast axial image of the low posterior fossa. Note the margins of the hypoglossal canal (*arrows*).

*B*, Spin-echo T1-weighted, 600/15/3 gadopentetate dimeglumine-enhanced axial image. The postcontrast scan shows the typical intensity and extent of intracanalicular enhancement. Note the linear filling defect traversing the enhanced canal representing nerve rootlets (*open arrowheads*) and dural enhancement (*thick white arrow*). Extension of enhancement into the carotid area is present (*black arrow*). Note the canal margins (*thin white arrows*).

(mild enhancement), or 3 (no enhancement). An attempt was made to correlate the MR appearance with anatomic descriptions of the canal contents.

## Results

The pattern of contrast enhancement in hypoglossal canals in the patients of our series is as follows:

	Present	Absent
Symmetry	28 (100%)	0 (0%)
Anterior extension enhancement into prevertebral nasopharyngeal space	28 (100%)	0 (0%)
Linear filling defect traversing canal	21 (75%)	7 (25%)
Dural enhancement in low posterior fossa	18 (64%)	10 (36%)

Cases with significant motion artifact (3 [10%] of 31) were excluded from the study, for a total of 28 subjects. The hypoglossal canals were routinely identified in most cases on retrospective evaluation of fine slice axial sections of the low posterior fossa. The high signal of the fatty marrow of the basilar occiput on T1-weighted sequences provides a landmark for the level of visibility of the canals that pierce the occiput at the junction of its basilar and lateral parts bilaterally, just above the level of the foramen magnum (Fig 1A). The canals are out-

lined by the low-signal-intensity cortex of the surrounding occipital bone. The nonenhanced canal contains tissue of intermediate signal intensity.

The enhanced canal has a characteristic appearance (Fig 1B). Intracanalicular enhancement is a constant finding and was symmetric in all cases reviewed. The intensity of enhancement generally was equivalent to adjacent vascular structures (grade 1) such as the jugular bulb (23 [82%] of 28). Anterior extension and branching into the soft tissues beneath the skull base was consistently seen (28 [100%] of 28). A linear filling defect traversing the canal was present in many cases (21 [75%] of 28). Circumferential (sometimes incomplete) dural enhancement at the level of the foramen magnum also was common (18 [64%] of 28).

## Discussion

Identification of the hypoglossal canals on MR imaging is possible routinely; it requires an understanding of the bone structures. These include the occipital condyles inferiorly, the jugular process of the occipital bone and the jugular foramen laterally, and the sphenoid component of the clivus superomedially (6, 7). The jugular foramina and the hypoglossal canals are about 8 mm apart on the inner surface

of the skull but separated by only a thin sheet of bone on the external surface (5). A variably present channel, the condylar (posterior condylar) canal, is seen posterolateral to the hypoglossal canal. Its MR appearance has been recently described (8).

Although prior studies have demonstrated the hypoglossal canal to be inclined at a slight angle to the orbitomeatal plane (1, 2), both routine computed tomography and MR axial imaging allows identification of the canal usually throughout its entire length. The dimensions of the canal have been previously reported with both plain x-ray film and computed tomography (1, 2). The latter study suggested a mean length and breadth of the canal of 7.8 mm and 5.0 mm, respectively.

Intracanalicular enhancement with gadopentetate dimeglumine is a constant finding. To speculate on the origin of this phenomenon, we need to review the contents of the canal.

The nucleus of the hypoglossal nerve lies in a paramedian location in the floor of the fourth ventricle. Nerve root fibers exit the medulla as 10 to 15 rootlets in the preolivary sulcus and pass through the premedullary subarachnoid space as multiple rootlets in proximity to the vertebral artery (5, 9). The nerve rootlets combine to form two separate bundles that perforate the dura mater and unite after their passage through the hypoglossal canal (10). Opinions vary as to whether the nerve bundles simply pierce the dura or acquire a dural sheath extending into the canal (10, 11). This point is relevant, because we have noted dural enhancement as a common finding in the low posterior fossa (61%). This compares to some degree of enhancement of the meninges at the level of the fourth ventricle in 91% of cases in a recent study (12). However, although extension of dura into the hypoglossal canal possibly contributes to intracanalicular enhancement, we do not consider it to be the major cause, because the enhancement extends anteriorly out of the canal and is more frequent (100%) than meningeal enhancement in the posterior fossa (64%).

Canal vascular structures have been reported to include a meningeal branch of the ascending pharyngeal artery as well as a small emissary vein (anterior condyloid) from the basilar plexus (10). The arterial branch is an inconstant finding seen in only 45% of cases in a recent anatomic study (11).

The anterior condyloid vein arises from the inferior petrosal sinus (13), and we consider this structure the most likely cause of the canal enhancement. Recent anatomic studies suggest that in fact, five to eight venous radicles consistently pass through the canal (11) accounting for the intensity of the enhancement. The anterior extension and branching pattern of enhancement can be explained by these venous radicles joining the suboccipital venous plexus (13). Further work could include dynamic contrast enhanced MR studies to compare the timing of canal enhancement with other skull base structures (arteries, veins, and dura) for confirmation.

A linear filling defect traversing the enhanced canal is a characteristic and common finding. A bone spicule partially dividing the hypoglossal canal has been previously described as a normal variant (10). Theoretically, the low signal intensity of cortical bone could be responsible for this finding, but the symmetry and frequency of the appearance (75% of our cases) suggest otherwise: past studies suggest partial bone division of the canal in only 10% to 15% and complete bilateral division in less than 5% (1). Hypoglossal nerve rootlets or other structures between numerous enhancing venous radicles could be responsible.

Diseases involving the hypoglossal nerve and canal at the skull base include benign tumours such as large glomus jugulare neoplasms; such a case initially prompted this study when normal hypoglossal canal enhancement was misinterpreted to represent direct extension and involvement of the canal by tumour (Fig 2). Intravenous administration of MR contrast media has been recommended to improve lesion detectability in patients with paragangliomas (14), although others would argue that contrast does not improve the diagnostic yield (15). If contrast is used, recognition of the normal enhanced appearance of the hypoglossal canals should improve assessment of tumor spread.

Other skull base neoplasms include metastases and myeloma, as well as tumors of neural origin (neuromas, schwannomas); meningiomas also can occasionally occur in this region. Extension of extracranial malignant neoplasms such as squamous cell carcinoma of the head and neck and infection also may involve the hypoglossal canal.

In summary, the hypoglossal canals are well demonstrated on fine-section axial MR images

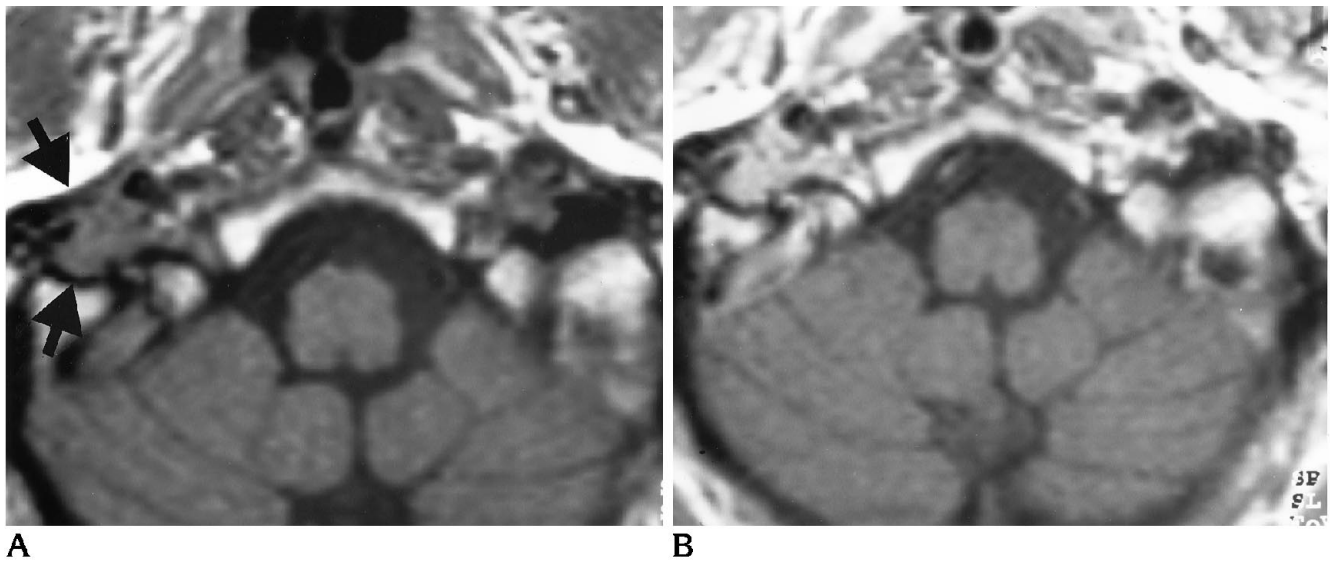


Fig 2. Right jugulotympanic glomus tumor. A, Spin-echo T1-weighted, 600/15/3 noncontrast axial image shows tumor involvement within the carotid sheath, jugular fossa, and bulb (arrows).

B, Spin-echo T1-weighted, 600/15/3 gadopentetate dimeglumine-enhanced axial image. Tumor abuts but does not involve the hypoglossal canal, which shows a normal enhancement pattern.

of the posterior fossa and show a characteristic and symmetric enhancement pattern after contrast injection probably attributable to the passage of multiple emissary venous radicles. The importance of these findings lies in the ability to recognize the normal MR appearance of the canal and in interpretation of skull base lesions.

## References

- Berlis A, Putz R, Schumacher M. Direct and CT measurements of canals and foramina of the skull base. *Br J Radiol* 1992;65:653-661
- Kirdani MA. The normal hypoglossal canal. *Radiology* 1967;99(3):700-704
- Valvassori GE, Kirdani MA. The abnormal hypoglossal canal. *Radiology* 1967;99(3):705-711
- Harnsberger R. Unlocking the brain stem, basal cisterns, and skull base through MR imaging of the cranial nerves. In: Stark DD, Bradley WG Jr, eds. *MRI Diagnostic Syllabus*. Oak Brook, Ill: Radiological Society of North America; 1988:197-219
- Smoker WRK, Harnsberger R, Osborn AG. The hypoglossal nerve. *Semin Ultrasound CT MR* 1987;8(3):301-312
- Daniels DL, Williams AL, Haughton VM. Jugular foramen: anatomic and computed tomographic study. *AJNR Am J Neuroradiol* 1983;4:1227-1232
- Daniels DL, Schenck JF, Foster T, et al. Magnetic resonance imaging of the jugular foramen. *AJNR Am J Neuroradiol* 1985;6:699-703
- Weissman JL. Condylar canal vein: unfamiliar normal structure as seen at CT and MR imaging. *Radiology* 1994;190:81-84
- Lang J. Anatomy of the brainstem and the lower cranial nerves, vessels and surrounding structures. *Am J Otol* Nov 1985(suppl):1-19
- Williams PL, Warwick R, eds. *Gray's Anatomy*. 36th ed. New York, NY: Churchill Livingstone 1980:307-313
- Lang J, Hornung G. Über den Canalis hypoglossi und seinen Inhalt beim postero-lateralen Zugang zur petroclivalen Region. *Neurochirurgia* 1993;36:75-80
- Fam JW, Mirowitz SA. MR imaging of the normal meninges: comparison of contrast enhancement patterns on 3-D gradient-echo and spin-echo images. *AJR Am J Roentgenol* 1994;162:131-135
- Hacker H. Superficial supratentorial veins and dural sinuses. In: Newton TH, Potts DG, eds. *Radiology of the Skull and Brain: Angiography*. St Louis: CV Mosby; 1974;2
- Phelps PD, Cheeseman AD. Imaging jugulotympanic glomus tumours. *Arch Otolaryngol Head Neck Surg* 1990;116:940-945
- van Gils APG, van den Berg R, Falke THM, et al. MR diagnosis of paraganglioma of the head and neck: value of contrast enhancement. *AJR Am J Roentgenol* 1994;162:147-153