
Severe Symptomatic Vasospasm after Rupture of an Arteriovenous Malformation

Karl Kothbauer, Gerhard Schroth, Rolf W. Seiler, and Dai-Do Do

Summary: A 31-year-old woman had intracerebral and intraventricular hemorrhage from an arteriovenous malformation. Vasospasm of the internal carotid arteries developed and was treated with angioplasty. On initial CT scans, only traces of blood were seen in the basal cisterns; thus, the development of symptomatic vasospasm was an unexpected complication.

Index terms: Arteriovenous malformations, intracranial; Vasospasm

Symptomatic vasospasm is a severe complication in the course of subarachnoid hemorrhage (SAH) caused by a ruptured intracranial aneurysm (1). It is believed that the severity of vasospasm is related to the amount of blood in the basal cisterns (1, 2). The prevalence of vasospasm in SAH after bleeding from an intracranial arteriovenous malformation (AVM) has been reported to be very low, symptomatic vasospasm with ischemic events being a rare exception (2–5). We report a case of intraventricular and intracerebral hemorrhage from an AVM that unexpectedly resulted in severe symptomatic vasospasm, although virtually no cisternal blood was seen on initial computed tomographic (CT) scans.

Case Report

A 31-year-old woman was referred to this hospital after 3 days of recurrent headaches and sudden onset of severe headache with consecutive coma. An SAH, grade V according to the scale of Hunt and Hess (6), was suspected. CT scanning showed intracerebral hemorrhage in the head of the right caudate nucleus and the genu of the corpus callosum with severe intraventricular hemorrhage. Only little, if any, subarachnoid blood was seen (Fig 1A). Internal hydrocephalus was present. After external ventricular drainage, the patient's status improved significantly; she was alert, oriented, and without focal neurologic deficit. Subsequent angiographic evaluation showed a small anterior callosal AVM on the right side that received feeding

vessels from the right pericallosal artery and drained into both superficial and deep cerebral veins on the right side (Fig 1B), thus representing a grade II lesion according to the system of Spetzler and Martin (7). Sixteen days after the initial hemorrhage the patient's status suddenly deteriorated and left-sided hemiparesis developed. CT scanning showed evidence of ischemia in the vascular territories of both anterior cerebral arteries as well as the right middle cerebral artery (Fig 1C). Transcranial Doppler measurement of blood flow velocities (8) in the middle cerebral arteries revealed vasospasm with extremely high mean velocities of about 300 cm/s on the right side and 230 cm/s on the left side, compared with normal velocities (70 cm/s) on the day of admission. Repeat angiography showed severe vasospasm of both internal carotid arteries, more pronounced on the right side (Fig 1D). Transluminal angioplasty of the right internal carotid artery was then performed with a single-lumen, over-the-wire balloon catheter (Stealth System; Target Therapeutics, San Jose, Calif). Mean velocities of the middle cerebral artery on the right side were down to 170 cm/s thereafter. Treatment with intravenous nimodipine was started. The patient's status remained critical. Progressive hydrocephalus eventually required occipital ventriculoperitoneal shunting 1 month after the initial hemorrhage. After clinical deterioration, the symptomatic vasospasm was closely monitored with transcranial Doppler recordings. Velocities on both middle cerebral arteries slowly returned to normal within about 3 weeks. The patient remained stable with left-sided hemiparesis, gait disorder, and severe neuropsychological deficits. Definitive treatment of the AVM was postponed.

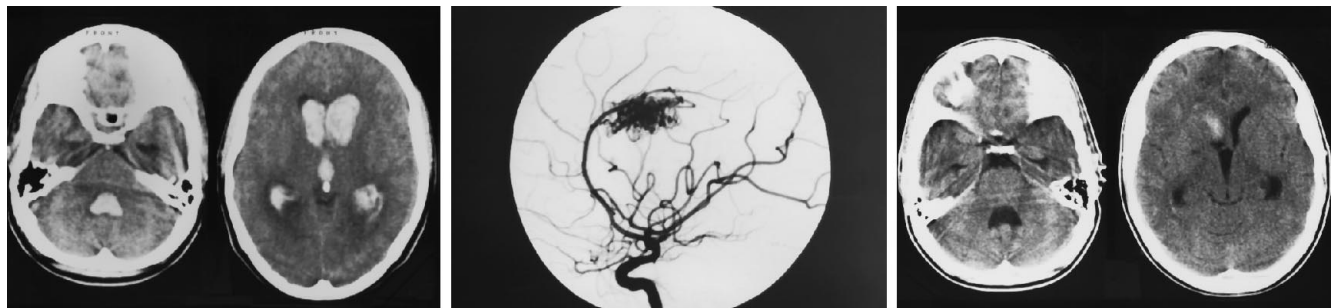Discussion

According to the data obtained from larger series, symptomatic vasospasm caused by SAH from intracranial AVMs is rare (3–5). Furthermore, evidence suggests that the occurrence and severity of vasospasm in aneurysmal SAH are directly related to the amount of blood detected in the basal cisterns (1). Because

Received November 9, 1993; accepted February 16, 1994.

From the Departments of Neurosurgery (K.K., R.W.S.), Neuroradiology (G.S.), and Angiology (D-D.D.), University of Bern, Switzerland.

Address reprint requests to Gerhard Schroth, MD, Department of Neuroradiology, University of Bern, Inselspital, CH-3010, Bern, Switzerland.



A, The initial axial noncontrast CT scans show extensive intraventricular hemorrhage without subarachnoid hemorrhage in the basal cisterns.

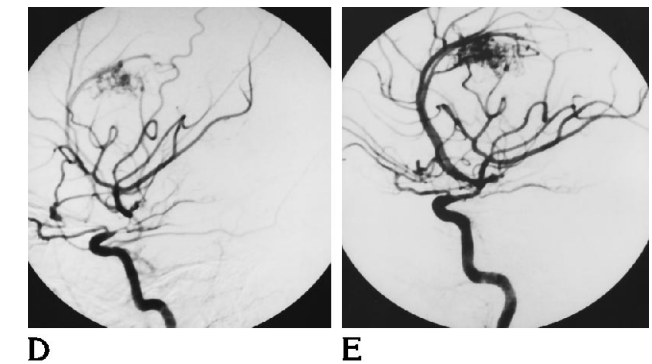
B, Lateral right internal carotid artery angiogram shows an arteriovenous malformation of the corpus callosum as the source of bleeding. There is no evidence of concomitant aneurysm of the feeding arteries.

C, Axial noncontrast CT scans 16 days after the bleeding episode show residual hemorrhage inside and adjacent to the frontal horn of the right lateral ventricle without subarachnoid hemorrhage.

D, Lateral right internal carotid artery angiogram 16 days after hemorrhage shows severe spasm in the intracranial-supraclinoid carotid segment (C1), extending to the M1 segment of the middle cerebral artery.

E, Lateral right internal carotid artery angiogram after angioplasty shows significant reversal of vasospasm.

bleeding from AVMs is usually less severe than that from saccular aneurysms, this was thought to account for the rarity of vasospasm after bleeding from AVMs (4). In the case reported here, predominantly intracerebral and intraventricular bleeding was present, whereas virtually no cisternal blood and definitely no cisternal clot were found. The occurrence of symptomatic vasospasm more than 2 weeks after the initial hemorrhage was unexpected and is not readily explained. On angiography, the spastic segments of the basal cerebral arteries were visualized (Fig 1D), and it was decided to dilate the vessel on the symptomatic side (Fig 1E). On repeat transcranial Doppler measurements of the basal cerebral arteries, a drop in mean velocity on the side with angioplasty was observed, indicating effective dilatation of the spastic vessel. However, the clinical status of the patient remained critical. A pathophysiologic explanation of vasospasm from solely intraventricular and intracerebral bleeding is lacking. A factor derived from the ventricular clot and transported via the cerebrospinal fluid could be presumed. Trapping of vasogenic factors in the subarachnoid space was suggested as a cause for vasospasm (9). Furthermore, central sympathetic structures exerting a neu-



rogenic influence on cerebral vessels could be functionally or structurally altered by the hemorrhage (10, 11). The amount of blood in the basal cisterns is generally a reliable predictor of vasospasm and has been shown to be associated with outcome in aneurysmal SAH (1). The severity of vasospasm in the patient reported is a remarkable rarity and can be attributed to some unknown individual susceptibility of the affected arteries to develop spasm after hemorrhage, even in the absence of blood clot in the adjacent cisterns. As shown by others (12, 13), transluminal angioplasty is a feasible treatment for symptomatic arterial spasm intracranially. Reversal of symptoms was not entirely possible in our case, but at least the severity of ischemia and the size of infarction were reduced.

References

1. Fisher CM, Kistler JP, Davis JM. Relation of cerebral vasospasm to subarachnoid hemorrhage visualized by computerized tomographic scanning. *Neurosurgery* 1980;6:1-8
2. Arutiunov AI, Baron MA, Majorova NA. Experimental and clinical study of the development of spasm of the cerebral arteries related to subarachnoid hemorrhage. *J Neurosurg* 1970;32:617-625
3. Mohr JP. Neurological manifestations and factors related to therapeutic decisions. In: Wilson CB, Stein BM, eds. *Intracranial Arteriovenous Malformations*. Baltimore: Williams & Wilkins, 1984:1-11

4. Parkinson D, Bachers G. Arteriovenous malformations. *J Neurosurg* 1980;53:285-299
5. Taveras JM, Pool JL, Fletcher TM. The incidence and significance of cerebral vasospasm in 100 consecutive angiograms of intracranial aneurysms. *Trans Am Neurol Assoc* 1959;83:100-104
6. Hunt WE, Hess RM. Surgical risk as related to time of intervention in the repair of intracranial aneurysms. *J Neurosurg* 1968;28:14-20
7. Spetzler RF, Martin NA. A proposed grading system for arteriovenous malformations. *J Neurosurg* 1986;65:476-483
8. Aaslid R, Huber P, Normes H. Evaluation of cerebrovascular spasm with transcranial Doppler ultrasound. *J Neurosurg* 1984;60:37-41
9. White RP, Hagen AA, Morgan H, Dawson WN, Robertson JT. Experimental study on the genesis of vasospasm. *Stroke* 1975;6:52
10. Svendgaard NA, Arbab MA-R, Delgado TJ, Rosengren E. Effect of selective lesions of medullary catecholamine nuclei on experimental cerebral vasospasm in the rat. *J Cereb Blood Flow Metab* 1987;7:21-28
11. Delgado TJ, Diemer NH, Svendgard N-A. Subarachnoid hemorrhage in the rat: cerebral blood flow and glucose metabolism after selective lesions of the catecholamine systems in the brainstem. *J Cereb Blood Flow Metab* 1986;6:600-606
12. Barnwell SL, Higashida RT, Halbach VV, Dowd CF, Wilson CB, Hieshima GB. Transluminal angioplasty of intracerebral vessels for cerebral arterial spasm: reversal of neurological deficits after delayed treatment. *Neurosurgery* 1989;25:424-429
13. Zubkov YN, Nikiforov BM, Shustin VA. Balloon catheter technique for dilatation of constricted cerebral arteries after aneurysmal SAH. *Acta Neurochir (Wien)* 1984;70:65-79