

The Paranasal Sinuses of Patients with Acute Graft-versus-Host Disease

J. H. Deutsch, P. A. Hudgins, J. L. Siegel, S. B. Peterman, S. M. Devine, R. York, and J. R. Wingard

PURPOSE: To determine whether patients who have acute graft-versus-host disease (AGVHD), are more likely to have radiographically abnormal paranasal sinuses after bone marrow transplantation than patients without AGVHD. **METHODS:** This retrospective case-control study population comprised 45 adult allogeneic or matched unrelated donor patients who underwent bone marrow transplantation. Twenty-eight patients had AGVHD, and 17 patients did not. All patients had paranasal sinus imaging with either CT or plain films for evaluation of possible sinusitis after bone marrow transplantation. The severity of radiographic changes was measured with an objective scoring system based on mucosal findings. **RESULTS:** An odds ratio revealed no association between AGVHD and the presence of radiographically abnormal sinuses. **CONCLUSION:** The diagnosis of AGVHD should not complicate the radiographic evaluation of acute sinusitis after bone marrow transplantation.

Index terms: Paranasal sinuses, radiography; Bone marrow transplantation; Immune deficiency

AJNR Am J Neuroradiol 16:1287-1291, June 1995

Bone marrow transplantation (BMT) is a therapeutic modality performed with increasing frequency in patients with hematologic or selected solid malignant neoplasms (1, 2). The transplantation of hematopoietic cells from a donor enables the regeneration of the host marrow, allowing more intensive antineoplastic therapy.

The most common complication of BMT during the postengraftment period, acute graft-versus-host disease (AGVHD), occurs because the transplanted immunocompetent T cells recognize host antigens as foreign, resulting in graft rejection or AGVHD (2). Human leukocyte antigen matching reduces, but does not pre-

vent, AGVHD, because there are minor antigens that can also cause AGVHD. AGVHD occurs in 30% to 60% of allogeneic (human leukocyte antigen-matched family members) patients who undergo BMT (2). Matched unrelated donor transplantations are also associated with AGVHD. AGVHD carries a 40% mortality rate, primarily because of infectious complications (3).

AGVHD affects the epithelial surfaces of target organs, especially the skin and gastrointestinal tract, causing mucosal damage. Strict clinical and pathologic criteria are used for establishing the diagnosis of AGVHD, which has an onset within 3 months after BMT (1, 2). The radiographic appearance of the paranasal sinus epithelial surface in the patient with AGVHD is not known. However, biopsy-proved AGVHD in paranasal sinus mucosa has been reported (4).

BMT preparation includes total body irradiation and chemotherapy, resulting in a profoundly immunocompromised patient. Infections, a common complication of BMT, usually occur within 3 months (2). Therefore, clinical distinction between AGVHD and infection may be difficult. Sinus computed tomographic (CT) scans or plain films are commonly obtained in patients after BMT for the detection of possible

Received August 26, 1994; accepted after revision January 23, 1995.

Presented at the International Congress of Head and Neck Radiology, Washington, DC, June 15-19, 1994, and as a poster at the 32nd Annual Meeting of the American Society of Neuroradiology, Nashville, Tenn, May 2-5, 1994.

From the Department of Radiology, Division of Neuroradiology (J.H.D., P.A.H., J.L.S., S.B.P.), and the Department of Medicine, Division of Hematology/Oncology (Bone Marrow Transplant Program) (S.M.D., R.Y., J.R.W.), Emory University School of Medicine, Atlanta, Ga.

Address reprint requests to Patricia A. Hudgins, MD, Emory University Hospital, Department of Radiology, 1364 Clifton Rd, NE, Atlanta, GA 30322.

AJNR 16:1287-1291, Jun 1995 0195-6108/95/1606-1287

© American Society of Neuroradiology

acute sinusitis or to discover the source of a fever. An accurate diagnostic radiographic evaluation of the paranasal sinuses is essential in the treatment of these immunocompromised patients.

Because AGVHD affects epithelial surfaces, and the paranasal sinuses are lined with epithelium, we hypothesized that patients with AGVHD will be more likely to have an abnormal radiologic appearance of the paranasal sinuses than patients without AGVHD. Because the diseased paranasal sinuses have a limited imaging appearance, it is possible that AGVHD could manifest itself with the nonspecific findings of sinus mucoperiosteal thickening, an air-fluid level, or opacification. Confirmation of this hypothesis would significantly impact the radiologist's interpretation of sinus imaging in the population with AGVHD.

Methods and Materials

During a 21-month period (December 1991 to September 1993), 72 patients underwent allogeneic sibling or matched unrelated donor BMT at our institution. This was a retrospective case-control study. These patients were identified from a larger database of BMT. Medical charts were reviewed to determine the study group. Patients were excluded from the study and control groups if they had had a prior BMT, were seropositive for the human immunodeficiency virus, had had prior surgery on the paranasal sinuses, or had chronic graft-versus-host disease without AGVHD. Patients with AGVHD included in the study had to meet the following inclusion criteria: (a) evidence of transplant engraftment, (b) radiographic imaging for possible acute sinusitis within 3 months after BMT, and (c) post-BMT sinus imaging within 3 weeks of the AGVHD diagnosis. Twenty-eight patients with AGVHD met the inclusion criteria. A control population without AGVHD included 17 patients who met the first two inclusion criteria. Imaging indications for possible acute sinusitis included unexplained fever or signs or symptoms referable to the paranasal sinuses.

Indications for BMT were as follows: chronic granulocytic leukemia (17 of 45 patients), acute myelogenous leukemia (16 of 45), myelodysplastic syndrome (4 of 45), non-Hodgkin lymphoma (3 of 45), acute lymphocytic leukemia (3 of 45), multiple myeloma (1 of 45), and aplastic anemia (1 of 45). Of the 45 patients who met inclusion criteria, 43 patients had allogeneic sibling transplants, and two had matched unrelated donor transplants. The diagnosis of AGVHD was established by standard clinical and pathologic criteria (1). Most patients (40 of 45) had baseline pre-BMT paranasal sinus imaging, which was reviewed with the post-BMT examinations. Imaging included either radiographs (four plain-film views) or CT scans (axial and coronal) of the sinuses (Table 1). Axial scans were

TABLE 1: Characteristics of patients with and without AGVHD

No. of Patients	With AGVHD (n = 28)	Without AGVHD (n = 17)	P Value
Age, mean years; SD	43.1; 9.0	44.1; 9.0	.35
Sex	15 M, 13 F	9 M, 8 F	.967
Acute sinusitis	7	8	.128
Pre-BMT imaging	5 CT, 20 plain film	5 CT, 10 plain film	.34
Pre-BMT imaging time, mean days; SD	22.1; 11.42	20.53; 7.78	.35
Post-BMT imaging	22 CT, 6 plain film	14 CT, 3 plain film	1.0
Post-BMT imaging time, mean days; SD	35.8; 21.4	24.2; 20.6	.05

performed at 5-mm intervals and coronal scans at 3-mm section increments. By consensus reading, two neuroradiologists blind to the presence of AGVHD retrospectively assigned a score to each maxillary, sphenoid, frontal, and ethmoid sinus. Sinuses were scored as 0, normal; 1, less than 10 mm mucoperiosteal thickening; 2, greater than or equal to 10 mm mucoperiosteal thickening or polyp; 3, air-fluid level; or 4, complete opacification. For each imaging study, the highest score obtained for a single paranasal sinus was considered the imaging score (Fig. 1).

Patients often had multiple imaging studies, and criteria were established to select which study would be used. The most current imaging study before the BMT was used for the pre-BMT score. For patients with multiple post-BMT sinus studies, the radiographic study with the highest score was designated as the post-BMT score. When patients had both plain-film and CT scans after transplantation, the CT scan was selected as the imaging modality. In addition, for patients who had multiple same scores and same modality imaging, the study that was earliest after BMT was included. When patients in the group with AGVHD had multiple radiographic studies, the same criteria were used, except the date of AGVHD diagnosis was used as the reference point instead of the BMT date. Six patients with AGVHD had post-BMT imaging before diagnosis of AGVHD. For these patients, the number of days before diagnosis of AGVHD was 1 (two patients), 4, 5, 8, and 17.

The clinical diagnosis of acute sinusitis, obtained from a retrospective chart review, was made by the BMT medical team and was based on both clinical and x-ray evaluation.

Possible confounding variables of the case and control groups were compared with two sample *t* tests for the continuous variables and χ^2 or Fisher's Exact Tests for the categorical variables. Odds ratios comparing normal versus abnormal sinus appearance were constructed to test the association between AGVHD and the paranasal sinus radiographic findings. Ninety-five percent confidence intervals were calculated using Fisher's Exact method. In addition, a power analysis was performed.

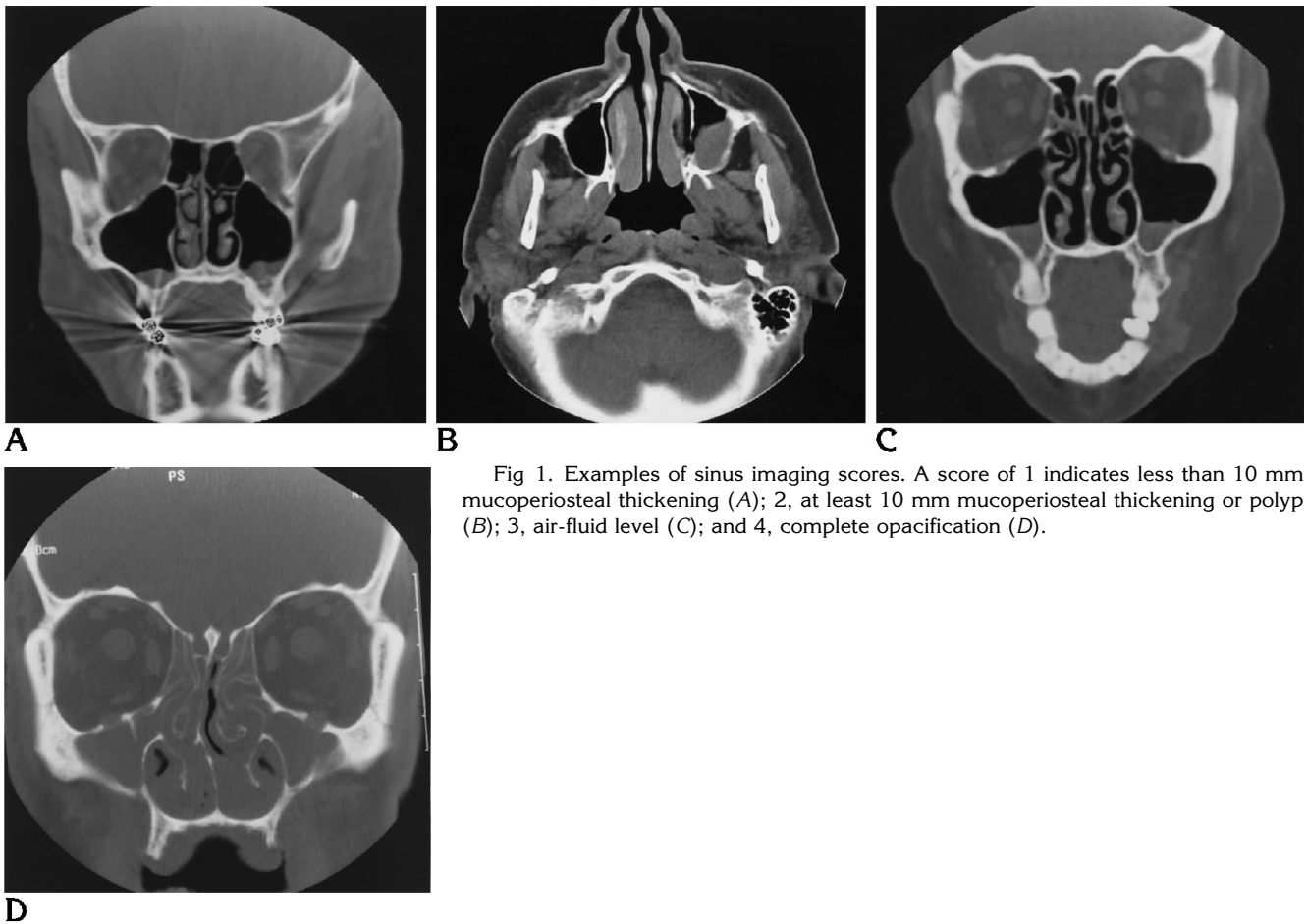


Fig 1. Examples of sinus imaging scores. A score of 1 indicates less than 10 mm mucoperiosteal thickening (A); 2, at least 10 mm mucoperiosteal thickening or polyp (B); 3, air-fluid level (C); and 4, complete opacification (D).

Results

Pre-BMT imaging studies were obtained in 40 of 45 patients (15 of 40 without AGVHD, 25 of 40 with AGVHD). All 45 patients had post-BMT imaging scores. Table 1 summarizes the patient and imaging characteristics of both the case and control groups. Patients with and without AGVHD did not differ significantly with regard to age, sex, presence of acute sinusitis, or type of post-BMT or pre-BMT imaging. There was no difference between the two groups on the number of days before BMT that baseline imaging was performed. The difference between the two groups with regard to when after BMT imaging was performed was significant at $P = .05$.

Figure 2 summarizes the post-BMT imaging scores for patients with and without AGVHD.

The odds ratio is the ratio of the likelihood that a patient with AGVHD has a radiographic finding to the likelihood that a control patient has that finding. An odds ratio of 1.0 means the finding is not associated with AGVHD. Using the

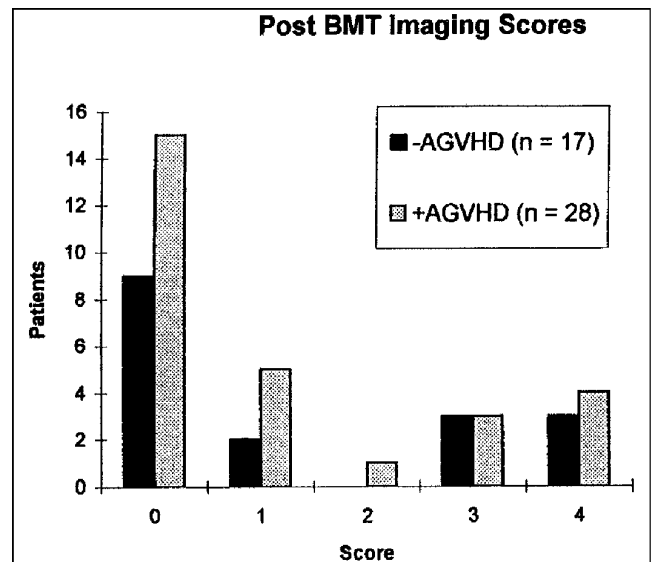


Fig 2. Imaging scores after BMT in patients with and without AGVHD.

TABLE 2: Post-BMT sinus score analysis for patients with versus without AGVHD

Normal Sinus Score	Abnormal Sinus Score	Odds Ratio (95% confidence interval)	Odds Ratio Adjusted for Time of Imaging (95% confidence interval)
0	1,2,3,4	0.98 (0.25–3.87)	0.69 (0.15–2.92)
0,1	2,3,4	0.73 (0.17–3.20)	0.51 (0.08–2.21)
0,1,2	3,4	0.61 (0.40–2.74)	0.44 (0.06–1.97)
0,1,2,3	4	1.29 (0.16–8.82)	0.64 (0.08–4.57)

multiple definitions of abnormal sinus imaging scores (Table 2), an odds ratio analysis showed no association between AGVHD and abnormal post-BMT sinus imaging scores. Odds ratios adjusted for the difference in post-BMT imaging timing also revealed no association. Baseline pre-BMT imaging showed no association between sinus scores and AGVHD status. A power analysis reveals that the study sample size is large enough to detect an odds ratio of 5.30 if the definition of abnormal findings includes scores of 1, 2, 3, and 4. The sample size is large enough to detect an odds ratio of 7.20 if an abnormal finding is considered a score of 4 only.

Discussion

Sinusitis in the healthy immunocompetent patient has a radiographic appearance that, in the correct clinical setting, can be confidently identified. An air-fluid level, sinus opacification, or at least 6 mm of mucoperiosteal thickening is highly accurate for sinusitis (5). Complicated sinusitis can be treated aggressively with antibiotics or surgery if indicated.

The presence of pancytopenia after BMT mandates an early diagnosis of sinusitis. Diagnostic biopsy for culture is usually not realistic in the patient with thrombocytopenia. Surgical drainage for the development of more complicated sinusitis is even more difficult. Finally, the decision to use either intensive antibiotics or antifungals for sinusitis is not without associated toxicity. Therefore, it is critical that the radiologist be confident of the diagnosis of sinusitis. The likelihood that an alternative process be responsible for the radiographic findings must be very low.

Unfortunately for the patient with BMT with clinical signs and symptoms referable to the sinuses, accurate diagnosis of pyogenic or fun-

gal sinusitis, even with radiographic evidence, is not assured. The coexistence of two disease processes in the same immunocompromised patient is common.

After engraftment allogeneic transplant, fever is not uncommon. Common causes include sinusitis, pulmonary cytomegalovirus or aspergillosis, hepatosplenic candidiasis, and venous catheter infections. Approximately 30% of allogeneic patients have clinical or radiologic evidence of sinusitis (Devine SM, Wingard JR, Deutsch J, et al, "Acute Sinusitis following Bone Marrow Transplantation," presented at the 35th Annual Meeting of the American Society of Hematology, St Louis, Mo, December 3–7, 1993). When a patient who has undergone BMT has a persistent fever with no obvious source and no symptoms referable to the paranasal sinuses, radiographic evaluation and diagnosis can be crucial. Given the spectrum of fever sources, accurate diagnosis is essential. Sinusitis and AGVHD are common complications found in the first several months after BMT. AGVHD has well-known clinical findings of a skin rash, hepatic dysfunction, or diarrhea. Skin involvement is the most common, and usually the first manifestation of graft-versus-host disease (1). Although sinus involvement has been reported, the effect of AGVHD on sinus radiographs is not known. However, given the potential epithelial involvement, it is highly likely that the sinuses would not have a normal radiographic appearance. Mucoperiosteal thickening in the sinuses can have many different inflammatory causes (6).

Because the two conditions, sinusitis and AGVHD, may coexist, and because both may affect the sinuses, this study was performed to show whether sinus abnormalities seen on plain films or CT scans can be attributed to infection or AGVHD.

Potential methodological difficulties based on the retrospective nature of the study did not prove to be problematic. The optimal study populations would consist of patients in the study (with AGVHD) and control subjects, with neither group having a clinical basis to suspect sinusitis. Table 1 reveals no significant difference regarding possible confounding variables. Because there was no significant difference between our control and study groups concerning the incidence of acute sinusitis, our study can accurately reflect the potential effects of AGVHD on the appearance of the sinuses. Even

though the patients without AGVHD were imaged sooner after BMT than those with AGVHD, the adjusted odds ratios (Table 2) were not significantly affected by this difference. In addition, image evaluation was done in a blind fashion.

The odds ratio as used in this study is the likelihood of a positive sinus score when AGVHD is present over the likelihood of a positive sinus score when AGVHD is not present. Adjusting for differences in date of imaging, positive sinus scores are not more likely to be present when AGVHD is present. In addition, different levels of sinus score abnormalities were not significant. However, our sample size was large enough to detect a significant difference.

Despite the fact that AGVHD affects mucosal surfaces, the likelihood of having radiographically abnormal sinuses is the same after BMT in patients with or without AGVHD. Therefore, the clinical diagnosis of AGVHD should not complicate the radiographic evaluation of acute sinusitis in this patient population. When a radio-

graphic abnormality of the sinuses develops in the patient after BMT in the appropriate clinical setting, the diagnosis of sinus infection can be made with confidence. The radiographic findings should not be attributed to mucosal involvement by AGVHD.

References

1. Ferrara JL, Deeg HJ. Mechanisms of disease: graft-versus-host disease. *N Engl J Med* 1991;324:667-674
2. Patzik SB, Smith C, Kubicka RA, Kaizer H. Bone marrow transplantation: clinical and radiologic aspects. *Radiographics* 1991; 11:601-610
3. Storb R. Bone marrow transplantation. In: Wyngaarden JD, Smith LH, Bennett JC, eds. *Cecil Textbook of Medicine*. 19th ed. Philadelphia: WB Saunders, 1992;1:985-987
4. Berlinger NT. Sinusitis in immunodeficient and immunosuppressed patients. *Laryngoscope* 1985;95:29-33
5. Williams JW, Simel DL. Does this patient have sinusitis? Diagnosing acute sinusitis by history and physical examination. *JAMA* 1993;270:1242-1246
6. Som PM. Sinonasal cavity. In: Som PM, Bergeron RT, eds. *Head and Neck Imaging*. St Louis: Mosby Year Book, 1991:114-276