

Limbic Connections

Leighton P. Mark, David L. Daniels, Thomas P. Naidich, and Lloyd E. Hendrix

The main structures of the limbic system, which have been described in past anatomic moments (1–5), are interrelated by a complex system of connections (6–8) that continue to be defined. The purpose of this anatomic moment is to summarize briefly some of the better known pathways, although a detailed discussion is beyond the scope of this small overview.

In 1937 a closed system, now known as the *circuit of Papez* (9) (Fig 1), was described linking the hippocampus, fornix, mamillary body, thalamus, and cingulum. Papez had suggested that this circuit was an essential part of the structural basis of emotion. Fibers from the hippocampus contribute to the alveus, which coalesce medially to form the fimbria. The fimbria forms the arching fornix, which projects to the mamillary body via the postcommissural fornix. Although the mamillary bodies project primarily to the anterior thalamic nucleus, some fibers also extend to the midbrain tegmentum. The anterior thalamic nucleus in turn projects to the cingulum deep to the cingulate gyrus to reach the temporal lobe entorhinal area, where the fibers connect with the hippocampus to complete the circuit. This is the classic description of the circuit of Papez, but more recent anatomic investigations have contributed to a greater appreciation of the role of the subiculum, indirect pathways, and cingulum (10) to this limbic system circuit.

The intrinsic connections of the hippocampus involve fibers from the entorhinal area, dentate gyrus, Ammon's horn, and the subiculum. The three primary pathways (11) of this area are called the *perforant path*, *mossy fibers*, and *Schaffer collaterals* (Fig 2). The existence of a fourth pathway, the alvear path from the entorhinal area to Ammon's horn through the alveus, has been questioned. The perforant path (Fig 2, *red arrow*) is considered the main affer-

ent pathway to the hippocampus, where glutaminergic fibers from the entorhinal area "perforate" the subiculum, traverse the fused hippocampal fissure, and reach the dentate gyrus. Investigators debate whether some perforant fibers reach Ammon's horn. The glutaminergic mossy fibers (Fig 2, *light blue arrow*) then extend from the dentate gyrus to CA-4 and CA-3, although some efferent fibers from CA-4 and CA-3 project to the fimbria. Many axons of CA-4 and CA-3, however, give off the Schaffer collaterals (Fig 2, *yellow arrow*) that reach the dendrites of CA-1. CA-1 is considered the main output of the hippocampus with fibers (Fig 2, *dark blue arrow*) extending to the alveus, fimbria, and then fornix. A supplementary linkage with the subiculum also is believed to be present.

The *efferent fibers* from the hippocampal region can be considered in three groups: precommissural fornix, postcommissural fornix, and nonfornical fibers (7). The *precommissural fibers* of the fornix (Fig 3, *short red arrows*) can originate from the cornu Ammonis or the subiculum. These fibers travel within the fimbria, crura, and body of the fornix, and then the precommissural fibers of the fornix. The cornu Ammonis fibers terminate exclusively in the lateral septal nucleus, whereas the subicular fibers are distributed to nucleus accumbens, anterior olfactory nucleus, lateral septal nucleus precommissural hippocampus, medial frontal cortex, and gyrus rectus. The *postcommissural fibers* (Fig 3, *blue arrows*) mostly terminate in the mamillary body, although some fibers also project to the anterior thalamic nucleus, bed nucleus of the stria terminalis, and ventromedial hypothalamic nucleus. The *nonfornical fibers* (Fig 3, *long red arrows*) project directly from the hippocampus to the entorhinal area as well as to the posterior cingulate and retrosplenial

From the Medical College of Wisconsin, Milwaukee (L.P.M., D.L.D., L.E.H.), and Baptist Hospital, Miami, Fla (T.P.N.).

Address reprint requests to Leighton P. Mark, MD, Neuroradiology Section, Medical College of Wisconsin, Department of Radiology/DH 151, Doane Clinic, 8700 W Wisconsin Ave, Milwaukee, WI 53226.

Index terms: Brain, anatomy; Anatomic moment





Fig 1. A, Reference drawing for Figures 1B through D (circuit of Papez) and Figures 3 through 5. The hippocampus, fornix, mamillary body, and thalamus (anterior nuclear group) are demonstrated in this slightly tilted medial view of the cerebral hemisphere.

B, The fibers from the hippocampus converge to form the fimbria, which in turn form the fornix. The curvilinear fornix (*blue arrow*) carries these fibers to the mamillary body.

C, The mamillary bodies then project fibers primarily to the anterior nuclear group of the thalamus, although a minority of fibers extend to the midbrain.

D, Fibers from the anterior thalamic nuclear group extend to the cingulum to reach the parahippocampal gyrus (entorhinal area) and then the hippocampus to complete the circuit of Papez.




Fig 2. Coronal schematic shows the intrinsic connections of the hippocampus. The perforant path (*red arrow*) extends from the entorhinal area to the dentate gyrus. The mossy fibers (*light blue arrow*) extend from the dentate gyrus to CA-4 and CA-3 with some fibers also projecting to the fimbria. The Schaffer collaterals (*yellow arrow*) connect CA-3 and CA-4 with CA-1. Fibers from CA-1 (*dark blue arrow*) constitute the main efferent pathway from the hippocampus with these fibers projecting to the alveus and then the fimbria and fornix.





Fig 3. Main efferent projection of the hippocampus. Fibers originating from the subiculum and cornu ammonis extend to the precommissural fibers (*short red arrows*) of the fornix, which project to the septal region and surrounding structures. The post-commissural fornical fibers (*blue arrows*) predominantly project to the mamillary body with some fibers also reaching the thalamus and ventromedial hypothalamic nucleus. The nonforniceal fibers (*long red arrows*) project directly from the hippocampus to the entorhinal area, posterior cingulate, and retrosplenial cortices and the amygdala.

Fig 4. Main afferent connections of the hippocampus. Fibers from the supramamillary and septal regions reach the hippocampus via the fornix (*blue arrow*). The anterior and midline thalamic (*MT*) nuclear groups reach the hippocampus via the cingulum (*red arrow*). The amygdala also projects to the hippocampus (*green arrow*).

Fig 5. Limbic pathways linking the telencephalon, diencephalon, and midbrain. The stria medullaris (*thin green arrow*) connects the septal nuclei with the habenula. Fasciculus retroflexus (*thin orange arrow*)

connects the habenula with the brain stem. The medial forebrain bundle (*thin purple arrow*) links the septal region with the midbrain. Also shown are the bidirectional fibers of the fornix (*blue arrows*) and stria terminalis (*long yellow arrow*), which link the septal region and amygdala. The mamillary body–thalamus–cingulum–hippocampus (*red arrows*) and amygdala–hippocampus (*short yellow arrow*) connections are indicated.

cortices and the amygdala. The hippocampus is able to reach many cortical areas via the entorhinal and perirhinal cortices. It is important to understand that the hippocampus has major connections with associational cortical areas and with subcortical limbic structures (12, 13). The relationships of the hippocampal-parahippocampal complex with the associational cortical areas are believed to be integral to the learning and memory processes.

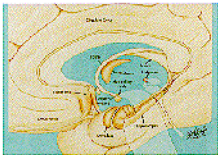
Many of the limbic fiber tracts are bidirectional so that the hippocampal complex also received afferent input from many areas that it projects to (Fig 4). Fibers from the medial septal nucleus reach the hippocampal region via the fornix (14) (Fig 4, *blue arrow*). Fibers from the nucleus of the diagonal gyrus and supramammillary region also project to the hippocampal region via the fornix. The anterior and midline thalamic nuclear complexes extend to the hippocampal region via the cingulum (Fig 4, *red arrow*), which is part of the circuit of Papez. The amygdala also provides input to the hippocampus and entorhinal cortex (Fig 4, *green arrow*).

Limbic pathways also provide connections between the telencephalon, diencephalon, and central midbrain structures (6) (Fig 5). The stria medullaris (Fig 5, *thin green arrow*) carries fibers from the septal to the habenula nuclei. These impulses are then conveyed to the midbrain via fasciculus retroflexus (Fig 5, *thin orange arrow*). The medial forebrain bundle (Fig 5, *purple arrow*) carries fibers directly from the septal region to the midbrain tegmentum after traversing the lateral hypothalamic area. Fibers

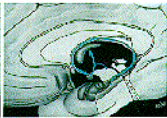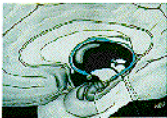from the mammillary bodies also project to the midbrain by the mammillothalamic tract (not indicated).

References

1. Mark LP, Daniels DL, Naidich TP, Borne JA. Limbic system anatomy: an overview. *AJNR Am J Neuroradiol* 1993;14(2):349-352
2. Mark LP, Daniels DL, Naidich TP, Yetkin Z, Borne JB. The hippocampus. *AJNR Am J Neuroradiol* 1993;14:709-712
3. Mark L, Daniels D, Naidich T. The fornix. *AJNR Am J Neuroradiol* 1993;14:1355-1358
4. Mark L, Daniels D, Naidich T, Williams A. Hippocampal anatomy and pathologic alterations on conventional MR images. *AJNR Am J Neuroradiol* 1993;14:1237-1240
5. Mark L, Daniels D, Naidich T, Hendrix L, Maas E. The septal area. *AJNR Am J Neuroradiol* 1994;15:273-276
6. Carpenter MB, Sutin J. *Human Neuroanatomy*. 8th ed. Baltimore: Williams and Wilkins, 1983:612-642
7. Nieuwenhuys R, Voogd J, van Huijzen C. *The Human Central Nervous System: A Synopsis and Atlas*. 3rd ed. New York, Berlin, Heidelberg: Springer-Verlag, 1988:293-363
8. Williams PL, Warwick R, Dyson M, Bannister LH. *Gray's Anatomy*. 37th ed. London: Churchill Livingstone, 1989:1028-1039
9. Papez J. A proposed mechanism of emotion. *Arch Neurol Psychiatry* 1937;38:725-743
10. Dagi T, Poletti C. Reformulation of the Papez circuit: absence of hippocampal influence on cingulate cortex unit activity in the primate. *Brain Res* 1983;259:229-236
11. Duvernoy HM. *The Human Hippocampus: An Atlas of Applied Anatomy*. New York, Berlin, Heidelberg: JF Bergmann Verlag Munchen, 1988:5-43
12. Rosene D, Van Hoesen G. Hippocampal efferents reach widespread areas of the cerebral cortex and amygdala in the rhesus monkey. *Science* 1977;198:315-317
13. Swanson L. Normal hippocampal circuitry. *Neurosci Res Prog Bull* 1982;20:624-637
14. Swanson LW. The anatomical organization of septo-hippocampal projections. *CIBA Foundation Symposium* 1977;58:25-48



A

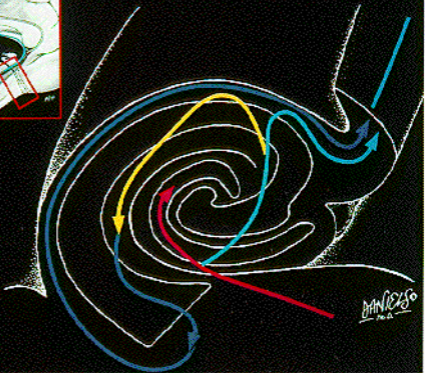
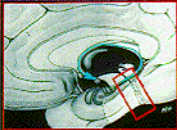


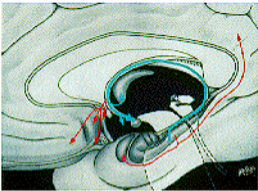
B

C

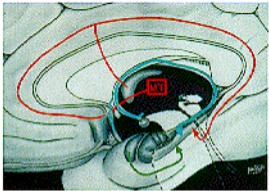


D

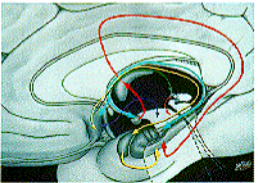




3



4



5