
Cortical and Subcortical T2 Shortening in Multiple Sclerosis

Craig Russo, Wendy R. K. Smoker, and Wayne Kubal

Summary: Low signal intensity on long-repetition-time MR sequences has been observed in deep gray matter structures in patients with multiple sclerosis. This T2 shortening most likely represents a nonspecific degenerative process. We recently observed T2 shortening in the pericentral cortical gray matter and subcortical white matter in a patient with severe multiple sclerosis and we postulate that this represents an additional manifestation of neural degeneration.

Index terms: Sclerosis, multiple; Brain, magnetic resonance

The magnetic resonance (MR) imaging appearance of multiple sclerosis (MS) is well described and includes characteristic abnormalities of the white matter and, less commonly, the gray matter (1–3). Of the gray matter abnormalities, T2 shortening of the basal ganglia may occur in long-standing cases and has been attributed to abnormal iron deposition, reflecting a degenerative phenomenon (3). We recently encountered a patient with severe MS in whom MR findings included T2 shortening of the precentral and postcentral cortical gyri and adjacent subcortical white matter. Given that iron deposition has been described in the histopathology of MS (4), we hypothesize that this finding may represent an additional manifestation of degenerative nonheme iron deposition.

Case Report

A 31-year-old woman first presented 4 years previously with bilateral lower extremity weakness and visual disturbance. MR examination at that time (not shown) revealed periventricular white matter changes characteristic of MS. Since then, the patient has suffered repeated exacerbations of symptoms, including bilateral lower extremity weakness, diplopia, vertigo, ataxia, urinary incontinence, and dysphagia. At the time of the MR study presented here, the patient's ataxia and lower extremity weakness had progressed to such an extent that she required assistance to walk at all times. Over the course of her illness she also suffered a general deterioration in cognitive function

and carried the additional diagnosis of organic personality disorder caused by the MS.

T1-weighted (600/15/1 [repetition time/echo time/excitations]) and first (2400/45/1) and second (4000/90/1) echo long-repetition-time turbo T2-weighted MR images (echo train = 5) were obtained using a 1.5-T magnet. The long-repetition-time images showed hypointensity of the pericentral gyri, adjacent subcortical white matter, thalami, and basal ganglia, as well as extensive hyperintensity involving the centrum semiovale and periventricular white matter (Fig 1).

Discussion

Although white matter abnormalities in MS are common and well described, gray matter abnormalities are less commonly encountered. In some severe or long-standing cases, the gray matter of the putamina and/or thalami may show T2 shortening, most likely representing deposition of nonheme iron as part of a nonspecific degenerative process (3). MS plaques, located in more peripheral white matter, may also involve adjacent cortical gray matter (2). Diffuse brain parenchymal volume loss, reflecting a general state of degeneration, may be seen early in the disease and in long-standing cases (1).

In our patient, the cause of T2 shortening in the pericentral gray matter is unknown, as no biopsy was performed. Similar findings have recently been described by Oba et al (5) in their series of patients with amyotrophic lateral sclerosis. Histologic analysis of several of their cases showed increased nonheme iron deposition in the regions of T2 shortening. Iron deposition may be seen histologically in MS plaques, along fiber tracts, within the walls of vasculature in gray matter, and in microglia in proximity to axons in MS patients (4). However, even in those cases with pathologically proved increased iron deposition, the origin of this in-

Received November 28, 1995; accepted after revision March 1, 1996.

From the Department of Radiology, Medical College of Virginia, Virginia Commonwealth University, Richmond, VA 23298. Address reprint requests to Craig Russo, MD.

AJNR 18:124–126, Jan 1997 0195-6108/97/1801-0124 © American Society of Neuroradiology

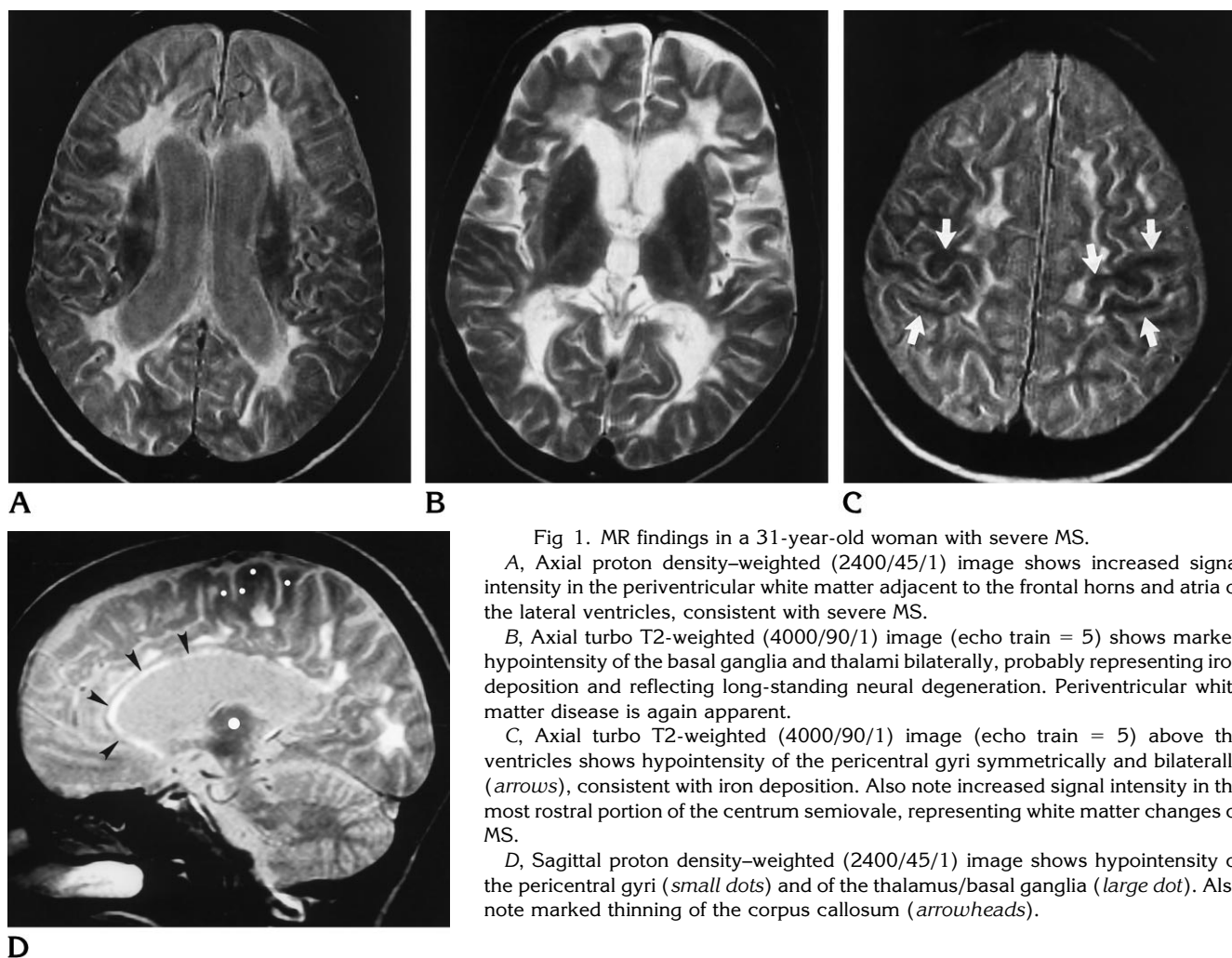


Fig 1. MR findings in a 31-year-old woman with severe MS.

A, Axial proton density-weighted (2400/45/1) image shows increased signal intensity in the periventricular white matter adjacent to the frontal horns and atria of the lateral ventricles, consistent with severe MS.

B, Axial turbo T2-weighted (4000/90/1) image (echo train = 5) shows marked hypointensity of the basal ganglia and thalami bilaterally, probably representing iron deposition and reflecting long-standing neural degeneration. Periventricular white matter disease is again apparent.

C, Axial turbo T2-weighted (4000/90/1) image (echo train = 5) above the ventricles shows hypointensity of the pericentral gyri symmetrically and bilaterally (arrows), consistent with iron deposition. Also note increased signal intensity in the most rostral portion of the centrum semiovale, representing white matter changes of MS.

D, Sagittal proton density-weighted (2400/45/1) image shows hypointensity of the pericentral gyri (small dots) and of the thalamus/basal ganglia (large dot). Also note marked thinning of the corpus callosum (arrowheads).

creased iron and its relation to the neurodegenerative process remain uncertain. T2 shortening of subcortical white matter, similar to that seen in this case, has been described in early cortical ischemia and has been attributed to the presence of free radicals and/or iron deposition (6). However, given the clinical scenario and distribution of this finding in our case, ischemia is an unlikely explanation. T2 shortening of white matter has also been described in wallerian degeneration (7). This finding may be seen several weeks into the process of wallerian degeneration and, eventually, the affected white matter becomes hyperintense on long-repetition-time images. Conceivably, this mechanism could account for the white matter T2 shortening seen in this case, if one postulates that there is symmetric bilateral subacute wallerian de-

generation superimposed over this patient's chronic findings of MS.

In addition to T2 shortening in the pericentral gyri, the MR findings in our case demonstrated T2 shortening of the basal ganglia and thalami, as described by Drayer et al (3). T2 shortening of the basal ganglia has also been associated with other neurodegenerative disorders, such as Parkinson disease and Huntington disease, and it may be seen in healthy elderly persons (8). Also present were typical findings of severe MS, including extensive periventricular white matter T2 prolongation, corpus callosal atrophy, and generalized cerebral atrophy (Fig 1). The subcortical white matter immediately adjacent to the pericentral cortical T2 shortening also appeared hypointense. The pathogenesis of this finding is uncertain, but it may represent an

additional manifestation of the same neurodegenerative process.

In summary, we have observed T2 hypointensity within the cortex and adjacent subcortical white matter in a patient with severe MS. Although we lack pathologic confirmation, the MR imaging findings suggest that this may represent degenerative nonheme iron deposition, similar to that described within the deep gray matter structures in MS.

References

1. Dietemann JL, Beigelman C, Rumbach L, et al. Multiple sclerosis and corpus callosum atrophy: relationship of MRI findings to clinical data. *Neuroradiology* 1988;30:478-480
2. Giang DW, Poduri KR, Eskin TA, et al. Multiple sclerosis masquerading as a mass lesion. *Neuroradiology* 1992;34:150-154
3. Drayer B, Burger P, Hurwitz B, Dawson D, Cain J. Reduced signal intensity on MR images of thalamus and putamen in multiple sclerosis: increased iron content? *AJNR Am J Neuroradiol* 1987;8:413-419
4. Craelius W, Migdal MW, Luessenhop CP, et al. Iron deposits surrounding multiple sclerosis plaques. *Arch Pathol Lab Med* 1982;106:397-399
5. Oba H, Araki T, Ohtomo K, et al. Amyotrophic lateral sclerosis: T2 shortening in motor cortex at MR imaging. *Radiology* 1993;189:843-846
6. Ida M, Mizunuma K, Hata Y, et al. Subcortical low intensity in early cortical ischemia. *AJNR Am J Neuroradiol* 1994;15:1387-1393
7. Kuhn MJ, Mikulis DJ, Ayoub DM, et al. Wallerian degeneration after cerebral infarction: evaluation with sequential MR imaging. *Radiology* 1989;172:179-182
8. Schenker C, Meier D, Wichman S, et al. Age distribution and iron dependency of the T2 relaxation time in the globus pallidus and putamen. *Neuroradiology* 1993;35:119-124