

Embolization of Dural Cavernous Fistulas via Superior Ophthalmic Vein Approach

D. Quiñones, G. Duckwiler, P. Y. Gobin, R. A. Goldberg, and F. Viñuela

PURPOSE: To present the results of our treatment of dural cavernous sinus fistulas with surgical exposure of the superior ophthalmic vein (SOV), retrograde venous catheterization, and coil embolization of the cavernous sinus. **METHODS:** Twelve patients with dural cavernous sinus fistulas were treated via a retrograde transvenous SOV approach in our hospital during a 3-year period. All patients had been referred by ophthalmologists because of secondary glaucoma and decreased visual acuity. Angiography showed preferential venous drainage of the dural cavernous sinus fistulas to an enlarged ipsilateral SOV. A total of 13 SOV exposures were performed, one patient with bilateral fistulas required bilateral treatment. The vein was surgically exposed by an ophthalmologist and then catheterized. Platinum coils were delivered through a microcatheter at the fistula site and into the root of the SOV, until there was complete angiographic closure. **RESULTS:** Catheterization and embolization were successful in 12 of the 13 patients, with complete angiographic occlusion of the fistula. Two patients with bilateral fistulas had transient worsening of symptoms on the contralateral side. Three patients required follow-up angiography. No early complications occurred, and late complications were minor in two cases. All patients except one with long-standing symptoms recovered premonitory visual acuity. At follow-up, 11 (92%) of the 12 embolized fistulas remained occluded. **CONCLUSIONS:** Retrograde catheterization of the SOV and embolization of the cavernous sinus with coils is a direct, safe, and efficient way to occlude dural cavernous sinus fistulas.

Index terms: Fistula, dural cavernous sinus; Fistula, embolization

AJNR Am J Neuroradiol 18:921-928, May 1997

Dural arteriovenous fistulas represent 10% to 15% of all intracranial arteriovenous malformations (A. Fox, G. Duckwiler, "Dural Arteriovenous Fistula," presented at the annual meeting of the American Society of Neuroradiology, St Louis, Mo, June 1992). Most dural fistulas are acquired conditions, typically occurring in postmenopausal women, but sometimes in younger patients in association with pregnancy (1-3). These fistulas account for most of the "spontaneous" cavernous carotid shunts (usually low-flow) (2, 4, 5), and are occasionally related to past trauma or surgery (6).

The vascular malformation consists of a nidus of multiple fistulas in the wall of a dural sinus. The arterial feeders are usually meningeal branches arising from the internal carotid artery (ICA) or the external carotid artery (ECA). Barrow et al (3) classified carotid cavernous fistulas into four groups according to arterial feeders. Types B, C, and D are dural fistulas, with feeders arising from the ICA only, the ECA only, or both the ICA and ECA, respectively. The arterialized blood usually drains into the dural sinus itself, either directly or through venous branches. Symptoms are related to the degree of shunting and the route of venous drainage (7-9). When there is partial thrombosis of the cavernous sinus, venous drainage can be diverted to the ophthalmic veins with associated ocular symptoms; most frequently, conjunctival injection (red eye), glaucoma, diplopia, and proptosis (1, 2).

The natural evolution of this vascular malfor-

Received March 7, 1995; accepted after revision November 25, 1996.
From the Department of Neuroradiology (D.Q., G.D., P.Y.G., F.V.) and the Jules Stein Eye Institute (R.A.G.), University of California, Los Angeles.
Address reprint requests to Diana Quiñones, MD, Clínica La Zarzuela, Resonancia Magnética, Las Pleyades 25, Aravaca, 28023 Madrid, Spain.

mation is variable; many spontaneously resolve by thrombosis (2, 7). If symptoms persist or worsen, treatment is considered. We report our experience in the treatment of dural cavernous sinus fistulas through a retrograde transvenous superior ophthalmic vein (SOV) approach using coils in patients with decreased visual acuity. The SOV route was described in 1969 for electrically induced thrombosis of the cavernous sinus (10) (W. Peterson, J. Valbert, D. Whittingham, "Electrically Induced Thrombosis of the Cavernous Sinus in the Treatment of Carotid-Cavernous Fistula," In: *Proceedings of the Fourth International Congress of Neurological Surgery: International Congress Series, 1969; 193:105, abstract.*), and its use has been described by several authors since then for different types of occlusion of the cavernous sinus (11–18).

Subjects and Methods

During a period of 3 years, we treated 12 patients with dural cavernous sinus fistulas through a retrograde transvenous SOV approach (Table 1). This represents 15% of the population who underwent embolization for dural arteriovenous fistulas of the cavernous sinus.

The patients included 10 women and two men, 27 to 86 years old (mean, 49.5 years). Three had a recent history of trauma; all the other fistulas were spontaneous in origin. One patient (case 7) presented several months after delivery of a child. Two patients (cases 2 and 12) had longstanding adult-onset diabetes mellitus.

All patients presented with red eye (conjunctival injection) and proptosis. The time between presentation and treatment ranged from 2 months to 2 years. In all cases, declining visual acuity prompted the ophthalmologists to consider endovascular occlusion.

Most of the patients had imaging findings—computed tomography (CT), magnetic resonance (MR) imaging, MR angiography, or Doppler sonography—that suggested the presence of a low-flow cavernous sinus shunt. In two patients (case 4 and 11), however, the initial findings at CT or MR imaging were negative.

Bilateral common carotid and selective internal and external carotid angiography was performed in all patients to assess the feeding arteries and the fistulous site and drainage before treatment. Bilateral fistulas are defined as those located in the dura of both cavernous sinuses. Unilateral fistulas may have feeders from both carotid systems, with the fistulous site limited to one cavernous sinus.

Whenever a selective transarterial catheterization was performed to embolize ECA feeders (cases 2, 3, 4, and 5), systemic heparinization was used.

The SOV was exposed by the ophthalmologist, with the patient under general anesthesia, and with lateral fluoroscopic control and a femoral artery sheath in place (19,

20). No systemic heparinization was used in order to enhance thrombosis of the cavernous sinus and reduce the likelihood of bleeding. The exposed vein was punctured with a 4F micropuncture system (Cook, Bloomington, Ind), and the needle was introduced only a few millimeters into the middle third of the vein until blood refluxed into the hub. The micropuncture set guidewire (0.018 gauge) was then carefully introduced inside the lumen and pushed gently into the cavernous sinus under fluoroscopic control. Once the wire was secured manually, the needle was retrieved and the 4F introducer was advanced about 2 to 5 cm coaxially. The introducer was secured to the vein by light detachable silk knots to avoid inadvertent dislodgment during manipulation. (Retrograde venography can be performed through the introducer sheath or later through the microcatheter.) The short (90 cm) Tracker 18 microcatheter (Target Therapeutics, Fremont, Calif) and wire (Dasher 14, Target Therapeutics) complex was advanced retrogradely to the cavernous sinus and positioned at the level of the fistulous site (as determined by the arteriogram). Selective venography through the microcatheter was performed manually under low pressure to avoid increasing intraocular pressure.

The embolic material we used included platinum ("flower") coils (Target Therapeutics) or Hilal coils (Cook) in most cases. We required between 10 and 27 Hilal coils to achieve angiographic occlusion. The coils were introduced with a coil pusher and deposited from the fistulous site posteriorly in the cavernous sinus to the base of the ipsilateral ophthalmic vein anteriorly. The use of a sheath permitted repositioning of the catheter tip as necessary to compact the coils adequately. In two patients (cases 6 and 8), we used Guglielmi electrically detachable platinum coils (Target Therapeutics).

When occlusion was considered satisfactory (no fistulous flow on the arteriogram), the venous catheter and sheath were removed after loosening of the silk ligatures. There was no significant bleeding because the vein was no longer arterialized. The vein was then ligated or cauterized before the lid incision was closed. We avoided silk sutures to prevent the formation of granulomas.

Follow-up angiography was not considered necessary in patients who had progressive improvement of visual symptoms. However, angiography was performed to evaluate contralateral orbital symptoms in two patients (cases 9 and 12) and to document complete eradication of a fistula in a patient in whom image quality was poor (case 8).

Results

According to the classification by Barrow et al (3), two patients (cases 6 and 8) had type B fistulas (ICA feeders only) and the other 10 had type D fistulas (both ICA and ECA feeders). There were no type C fistulas (ECA feeders only) in our series.

Angiography revealed a dangerous anasto-

Superior ophthalmic vein (SOV) approach to embolization of cavernous sinus dural fistulas

| Case | Age, y/Sex | Type of Fistula/Side | Time since Symptom Onset | Type of Imaging | Angiography/Embolization | Venous Drainage and Embolization Attempts | SOV Embolization | Clinical Outcome |
|------|------------|----------------------|--------------------------|-----------------|---|---|--|---|
| 1 | 27/F | D/R | 2 y | MR/TCD | R ICA, R ECA | R SOV stagnant, no angular vein | R SOV, 14 microcoils | 2 mo: facial asymptomatic; 14 mo: asymptomatic |
| 2 | 52/M | D/R | 6 mo | MR/angio | R ECA, bilateral ICA/R ascending pharyngeal artery with coils | R SOV | R SOV thrombosed. Microcoils | 9 mo: asymptomatic |
| 3 | 32/F | D/L | 3 mo | CT | L ICA, R ICA, L ECA/PVA in L ECA | Pial venous drainage to inferior temporal and perimesencephalic veins | L SOV, microcoils | 15 days: improved diplopia and VA; 8 mo: asymptomatic |
| 4 | 68/F | D/R | 6 mo | CT/MR/angio | R ICA, R ECA/PVA and coils in R IMA pseudoaneurysm | R SOV to angular vein, thrombosis in IPS | R cavernous sinus and posterior R SOV, 14 microcoils | 4 mo: VA, 20/80; eye granuloma; 1 y: scotoma |
| 5 | 31/F | D/L | 6 mo | CT/angio | L ICA, L ECA/PVA in L IMA | Anterior, no IPS. Posterior cavernous sinus thrombosis | L SOV thrombosed with microcoils | 7 mo: asymptomatic |
| 6 | 86/F | B/L | 3 wk | CT/MR/angio | L ICA, R ICA | Anterior, failed L IPS embolization | L SOV, 6 Hilal coils and 3 GDCs | 1 mo: improved VA; lost to follow-up |
| 7 | 40/F | D/bilateral | 3 mo | MR/TCD | L ICA, L ECA, R ICA | Anterior, transfemoral IPS only, posterior cavernous sinus, R SOV did not fill | R SOV, 27 microcoils | 1 mo: improved VA; 2 y: complete resolution |
| 8 | 36/F | B/R | 6 mo | CT/MR | ICA small hole direct fistula >>ECA | Anterior, R SOV | R SOV, GDCs | Angio at 15 days: cured; 4 mo: asymptomatic |
| 9 | 73/F | D/bilateral | 3 mo | MR/TCD | R ECA | Posterior, drains to R SOV; IPS failed | R SOV, microcoils | Angio at 5 d: occluded; 2 y: resolved |
| 10 | 35/F | D/L | 9 mo | MR | L ECA, L ICA | Anterior, L SOV, transfemoral angular failed | L SOV | 7 mo: asymptomatic |
| 11 | 44/M | D/L | 6 mo | CT/MR | L ICA, L ECA | Anterior, perimesencephalic pial drainage; transfemoral failed: IPS and angular vein thrombosis | L SOV, 10 Hilal coils | 1 mo: VA, 20/20 |
| 12 | 70/F | D/bilateral | 2 mo | MR | L ICA, L ECA, R ECA L ECA>>>ICA | Posterior, no IPS. drains R SOV and cortical posterior | R SOV, residual filling L SOV, unable to thrombose small L SOV | 1 mo: R side better, L side worse; 2 mo: R VA stable but L not improved |

Note.—TCD indicates transcranial Doppler sonography; angio, angiography; ICA, internal carotid artery; ECA, external carotid artery; PVA, polyvinyl alcohol particles; MM, middle meningeal artery; IPS, inferior petrosal sinus; GDC, Guglielmi detachable coils; and VA, visual acuity.

mosis between the ECA and ICA systems in two type D fistulas (cases 2 and 7), precluding safe ECA embolization. Retrograde pial venous drainage was seen in two patients (cases 3 and 12), prompting urgent occlusion. In four patients with type D fistulas (cases 2, 3, 4, and 5), prior transarterial external carotid embolization was insufficient to occlude the dural fistula and

to relieve visual symptoms. Embolization was done with polyvinyl alcohol particles (350 to 500 μm) in cases 3, 4, and 5 and with coils in case 2.

Three patients (cases 7, 9, and 12) had bilateral fistulas, and in these instances the most symptomatic side—the one with the enlarged SOV—was embolized. One patient (case 12,

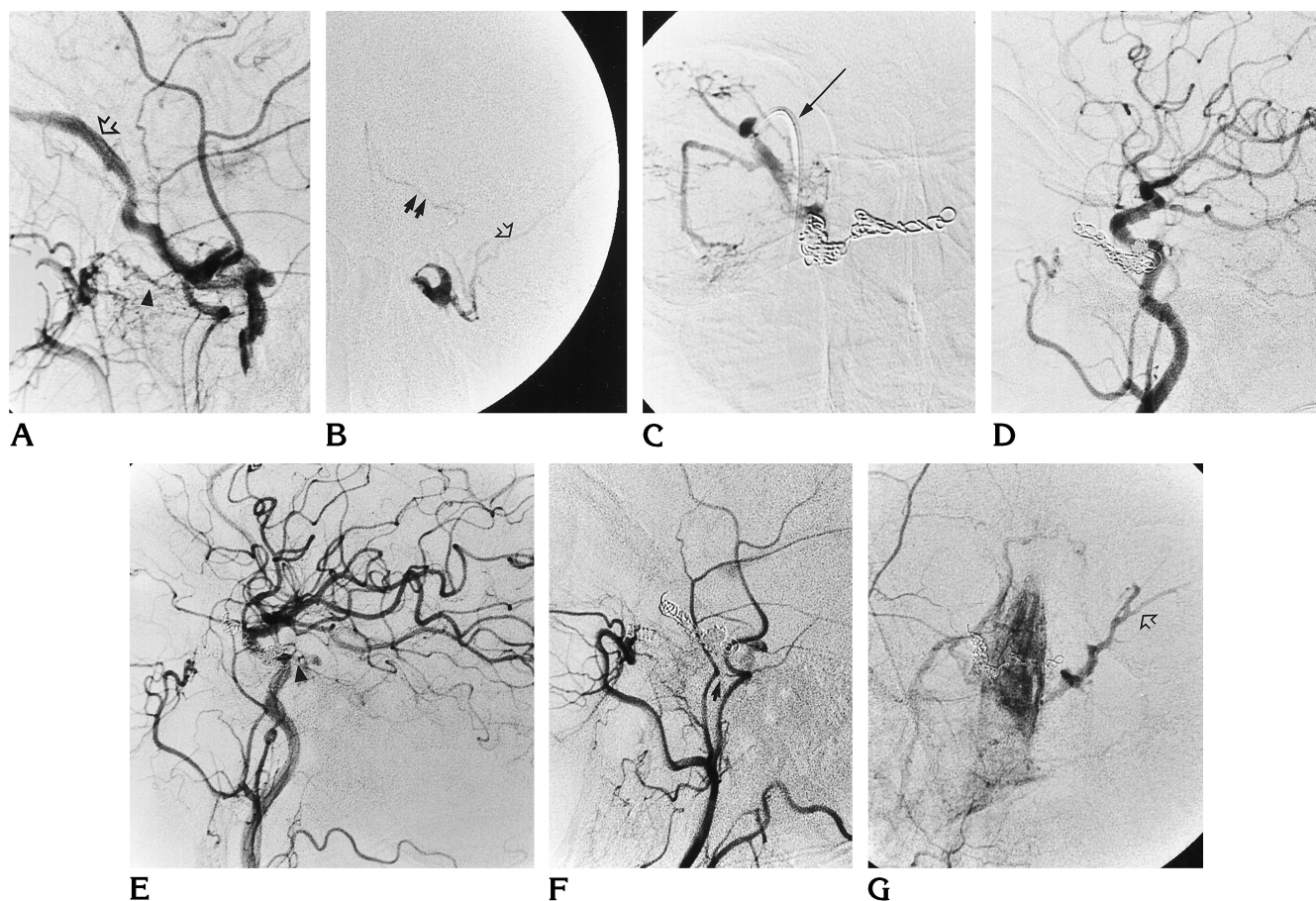


Fig 1. Case 12: 70-year-old woman with diabetes and nonresectable lung carcinoma who presented 2 months earlier with spontaneous bilateral proptosis (worse on the right). Arteriography showed a type D fistula, with predominant vascular supply from the ECA.

A, Right ECA angiogram, late arterial phase, shows feeders from the distal internal maxillary (arrowhead). The fistulous site is in the posterior cavernous sinus. Venous drainage was only to the right SOV at that time (arrow).

B, Right SOV venogram, anteroposterior view, shows the microcatheter tip crossing the coronary plexus to the contralateral side. The left SOV was not enlarged. Retrograde flow is seen to perimesencephalic veins (closed arrows), left superior petrosal sinus, and left temporal veins (open arrow). The inferior petrosal sinus was thrombosed.

C, Anteroposterior sinogram through the introducer sheath (arrow) after embolization of the right SOV shows coils deposited in the left posterior cavernous sinus across the midline to the right cavernous sinus and in the posterior right SOV. The orbital veins are massively engorged due to venous hypertension.

D, Lateral angiogram after embolization of the right common carotid artery shows complete occlusion of the right-sided fistula.

One month later, contralateral symptoms worsened. The right ICA and ECA injections show mild residual fistula.

E, Lateral angiogram of left common carotid artery shows feeders from the inferior hypophyseal trunk (arrowhead).

F, Lateral angiogram of right ECA shows feeders from the middle meningeal artery (arrow). Venous drainage is now only to the left SOV.

G, Anteroposterior angiogram, venous phase, of right ECA shows the small left SOV branching anteriorly (arrow). It was located deep in the orbital apex, and we were not able to catheterize it.

Fig 1) was initially treated from the right side (with coils also being deposited in the contralateral cavernous sinus, since the microcatheter crossed the coronary plexus). Symptoms from the right ameliorated, but during the following month contralateral symptoms progressed. Repeat angiography disclosed that the ipsilateral fistula had not thrombosed completely, and the contralateral fistula had worsened. Drainage on that occasion was to the left orbit, where two

small SOVs were seen with very little drainage posteriorly to the left inferior petrosal sinus.

On the day of embolization, the SOV did not fill in two patients (cases 2 and 5), indicating venous thrombosis. In both cases, retrograde catheterization of the SOV was possible with our usual technique. In case 2, the SOV was thrombosed 5 days after the initial angiogram; in patient 5, who had thrombosis of the posterior cavernous sinus, the SOV had thrombosed the

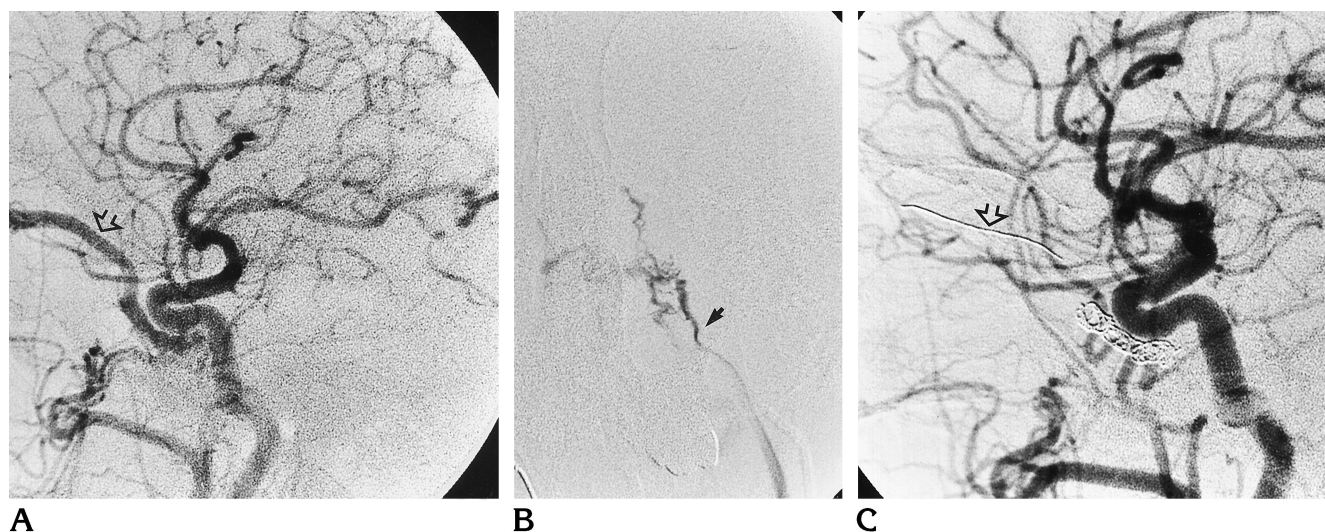


Fig 2. Case 11: 44-year-old man 6 months after spontaneous onset of left proptosis.

A, Lateral view of left common carotid artery angiogram shows SOV is enlarged (*arrow*) and fills retrogradely in early arterial phases. Outflow from the SOV is to an enlarged angular vein. An attempt to embolize through a transfemoral facial route failed owing to tortuosity at the junction of the angular vein and SOV.

B, A transfemoral venous attempt to catheterize the cavernous sinus failed because the small left inferior petrosal sinus (*arrow*) did not connect directly to the cavernous sinus on left petrosal venogram.

C, Lateral left common carotid artery arteriogram after SOV embolization shows the coils in the cavernous sinus, in the base of the SOV, and in the SOV (*arrow*). There is complete occlusion of the fistula.

day after the initial angiogram and a transfemoral angular vein approach had failed.

The transfemoral inferior petrosal sinus venous route failed in five patients (cases 4, 6, 7, 9, and 11). Figure 2 illustrates a patient (case 11) in whom an angular vein approach was not possible and a transfemoral inferior petrosal sinus route failed owing to the smallness of this structure.

No complications occurred on the day of the procedure. In the postprocedural period, most patients reported headache, dizziness, or nausea, which were attributed to chemical meningitis related to the thrombosis of the cavernous sinus.

Two delayed complications occurred. One patient (case 4) had a palpebral silk granuloma that was surgically removed for cosmetic reasons. Another patient (case 9), who had bilateral fistulas, had a transient contralateral cavernous sinus syndrome (abducens palsy) the day after the embolization. A follow-up angiogram performed on day 5 documented bilateral occlusion of the fistulas.

Progressive improvement of ocular symptoms (glaucoma, visual acuity) ensued in the following weeks. All but two patients (cases 4 and 12) recovered their premorbid visual acuity. In case 4, intraocular pressure normalized,

but visual acuity and normal visual fields (small central scotoma) were not recovered. This may be related to the delayed diagnosis (after 2 years) and the long interval (9 months) between the ECA embolization and definitive SOV occlusion. In case 12, the contralateral fistula could not be occluded, and thus visual acuity did not change on that side. Occlusion was evidenced angiographically in 92% of the patients in our series.

Discussion

Making a correct diagnosis of a dural cavernous sinus fistula is clinically difficult and may take months. The symptoms of these low-flow fistulas are not as dramatic as in traumatic high-flow cavernous sinus fistulas. Most patients do not have bruit (only three of our patients did) or pulsatile exophthalmos (none of our cases), which indicate a vascular lesion. This diagnosis should always be considered in patients with a red eye and arterialized episcleral vessels (1, 19).

Once clinical suspicion is raised, diagnosis can be supported by contrast-enhanced CT and MR imaging, MR angiography, or Doppler imaging studies, which can detect enlarged draining veins. MR imaging may suggest thrombosis

or slow flow in the SOV when this structure appears hyperintense (instead of the usual flow void) on T1-weighted images (21). Phase-contrast MR angiography and Doppler studies permit identification of flow reversal in the enlarged SOV.

Dural cavernous sinus fistulas are rarely life threatening, and may not require angiography or embolization (1, 22). In most cases, the initial step should be to wait, because there is a high rate of spontaneous closure (between 17% [2] to 50% [1]). Angiography is reserved for cases in which progression of symptoms occurs and occlusion of the fistula is considered. Bilateral ECA and ICA injections must be performed to assess the feeders, the site of the fistula, the venous drainage, and the hemodynamics of the lesion. All these factors influence possible treatment options. There is frequent contribution from contralateral dural vessels (2, 3, 7, 23–26) and, occasionally, from meningeal branches of the vertebral artery. After angiography, the fistula sometimes occludes, possibly related to thrombogenicity of angiographic contrast material (27, 28).

Several techniques have been used to attempt fistulous occlusion. Carotid compression is a simple maneuver that can be tried (26, 29). Patients at risk for embolic stroke or who show susceptibility to vasovagal hypotension at carotid massage should be excluded from this treatment. Reported cure rates are 30% in dural fistulas (30). Carotid compression was used and failed in two patients in our series (cases 8 and 10).

In the past, carotid ligation, carotid trapping, and other surgical techniques have been used to treat cavernous carotid fistulas. In most cases, the carotid was sacrificed. These methods were often ineffective because the site of the fistula was not always occluded and could recanalize through collaterals from the vertebral and ophthalmic arteries (11). A combination of surgery and vascular embolization has also been used (9, 12).

Today, endovascular methods permit distal occlusion of the abnormal dural feeders and fistulas, eliminating abnormal venous drainage and preserving the carotid artery. The route depends on the vascular anatomy and the rate of fistulous flow (31).

Venous drainage of dural cavernous carotid fistulas is usually to the ipsilateral cavernous sinus. Depending on the site of the fistulous

connection, subsequent drainage may be anterior (either to the SOV or the inferior ophthalmic vein) or posterior (to the inferior petrosal sinus, pterygoid, or clival plexus). When the drainage is to the inferior petrosal sinus (these cases are seen less frequently with decreased visual acuity), a transfemoral jugular venous embolization is feasible. If the drainage is anterior, to the orbital veins, we use an anterior SOV approach. The facial or angular veins may also be used (32), but catheterization to the fistulous site is not always feasible (case 11, Fig 2).

Endovascular embolization of ECA feeders in type C fistulas has a high success rate (26, 31). In type D fistulas, the ECA system is usually embolized first, since it may be sufficient to decrease symptoms. In bilateral fistulas, embolization of the most symptomatic side may also occlude the contralateral fistula. When there is predominant ICA supply or when ECA embolization is insufficient, venous embolization is indicated. The purpose of venous embolization is to occlude the fistula without rerouting venous drainage to cortical structures (26). When catheterization is possible, transvenous embolization has high (100%) occlusion rates (12). Some authors report a 50% rate of catheterization of the inferior petrosal sinus not detected at angiography (13), but in our hands we estimate a 30% success rate, even in cases in which the inferior petrosal sinus is seen. We prefer the SOV route when there is decreased visual acuity and anterior venous drainage.

The SOV route has been described for electrically induced thrombosis of the cavernous sinus since 1969 (12) (Peterson et al, "Electrically Induced Thrombosis..."). This route has been used for embolization of cavernous carotid fistulas with detachable balloons (31) and other embolic materials (11–13, 15, 16). Surgical exposure of the angular vein and catheterization of the distal SOV have also been described (14, 17, 32). Hanneken et al (18) used the SOV route when transarterial embolization could not be performed, was too dangerous, or had failed. Teng et al (15) used the SOV route when the posterior half of the SOV was enlarged, not focally narrowed, and the inferior petrosal sinus was not accessible. We used this route even in two patients in whom the enlarged SOV was thrombosed at the time of SOV exposure.

Bilateral fistulas were more complicated to treat. To control the pain and rapid visual decline on the contralateral side in one patient

(case 12), we attempted to catheterize the left SOV, but failed because it was not significantly enlarged and very posterior in the orbital apex. The only alternative treatment, direct surgical exposure of the cavernous sinus, was considered too aggressive in this patient with end-stage pulmonary carcinoma. On follow-up examination at 1 month, the patient had recovered most visual acuity on the treated side, but symptoms had worsened significantly on the contralateral side.

Embolic materials used for the SOV route include coils or balloons. The results of both methods are similar (20), but we prefer coils because they are technically less complicated and allow the use of a smaller-diameter catheter (4F instead of 5F) in the SOV.

We required between 10 and 27 Hilal coils to achieve angiographic occlusion. Guglielmi electrically detachable coils, which permit the insertion of a longer platinum wire segment and thus reduce the number of manipulations of the SOV, were used in two patients (cases 6 and 8). Angiographic results were satisfactory and the procedure was less complicated than when Hilal coils were used.

Potential complications of the SOV approach are hemorrhage resulting from the surgical cut down, the venous puncture, or rupture of the SOV; damage to the trochlea or other orbital structures; and infection. We do not routinely administer intravenous antibiotics and have not had any case of orbital infection. Late complications, such as granulomas, should not occur if silk sutures are avoided.

The current literature supports use of the SOV approach only when the transfemoral venous access has failed. However, our initial experience with surgical exposure of the SOV established some advantages over the transfemoral route. A direct approach to the cavernous sinus requires fewer catheter manipulations. Surgical exposure permits direct visibility and immobilization of the SOV, with less risk of rupture of the arterialized vein than with direct puncture. This approach also allows control of possible orbital hemorrhage. These advantages prompted us to choose this route for the treatment of dural cavernous sinus fistulas with predominant venous drainage to the SOV. In addition, the SOV exposure is not expensive, the extra surgical charge for the ophthalmologist is \$2500 at our institution, and the extra time needed is between 1 and 2 hours.

In conclusion, we find that retrograde catheterization of an enlarged SOV is a safe, direct, and efficient way to access the cavernous sinus, allowing endovascular coil occlusion of dural cavernous sinus fistulas with excellent angiographic and clinical results. We were able to use this route successfully even in two patients with recent SOV thrombosis. We thus recommend its use in the following circumstances: 1) when decreased visual acuity is associated with venous hypertension in the orbit; 2) when a large SOV is seen on MR or CT studies; 3) when the predominant arterial supply is from the ICA (Barrow type C and some type D); 4) when the external carotid feeders are dangerous to embolize because they anastomose with the ICA; and 5) when the transvenous jugular route fails.

Further research and larger patient populations are needed to validate these criteria for endovascular occlusion of dural cavernous sinus fistulas through the SOV.

References

1. Phelps C, Thompson H, Ossoinig K. The diagnosis and prognosis of atypical carotid-cavernous fistula (red-eye shunt syndrome). *Am J Ophthalmol* 1982;93:423-436
2. Newton T, Hoyt W. Dural arteriovenous shunts in the region of the cavernous sinus. *Neuroradiology* 1970;1:71-81
3. Barrow D, Spector R, Braun I, et al. Classification and treatment of spontaneous carotid cavernous fistulas. *J Neurosurg* 1986;62:248-256
4. Halbach V, Hieshima G, Higashida R, Reicher M. Carotid cavernous fistulae: indications for urgent treatment. *AJNR Am J Neuro-radiol* 1987;8:627-633
5. Toya S, Shiobara R, Izumi J, Shinomiya Y, Shiga H, Kimura C. Spontaneous carotid-cavernous fistula during pregnancy or in the postpartum stage: report of two cases. *J Neurosurg* 1981;54:252-256
6. Watanabe A, Takahara Y, Ibuchi Y, Mizukami K. Two cases of dural arteriovenous malformation occurring after intracranial surgery. *Neuroradiology* 1984;26:375-380
7. Viñuela F, Fox A, Debrun G, Peerless S, Drake C. Spontaneous carotid-cavernous fistulas: clinical, radiological and therapeutic considerations: experience with 20 cases. *J Neurosurg* 1984;60:976-984
8. Lasjaunias P, Chiu M, TerBrugge K, et al. Neurological manifestations in intracranial dural arteriovenous malformations. *J Neurosurg* 1986;64:724-730
9. Awad I, Little J, Akrawi W, Ahl J. Intracranial dural arteriovenous malformations: factors predisposing to an aggressive neurological course. *J Neurosurg* 1990;72:839-850
10. Hosobuchi Y. Electrothrombosis of carotid-cavernous fistula. *J Neurosurg* 1975;42:76-85
11. Ufflacker R, Lima S, Ribas G, Piske R. Carotid cavernous fistulas: embolization through the superior ophthalmic vein approach. *Radiology* 1986;159:175-179
12. Mullan S. Treatment of carotid-cavernous fistulas by cavernous sinus occlusion. *J Neurosurg* 1979;50:131-144
13. Halbach V, Higashida R, Hieshima G, Hardin C, Pribram H. Trans-

- venous embolization of dural fistulas involving the cavernous sinus. *AJNR Am J Neuroradiol* 1989;10:377-383
14. Iaccarino V, Spaziante R, Bonavolonta G, Cirillo S, Divitiis E. Treatment of carotid-cavernous fistula by transvenous anterior (transorbital) approach: case report and review of previous report. *J Neurosurg Sci* 1989;37:103-112
 15. Teng M, Guo W, Huang C, Chang T. Occlusion of arteriovenous malformations of the cavernous sinus via the superior ophthalmic vein. *AJNR Am J Neuroradiol* 1988;9:539-546
 16. Takahashi A, Yoshimoto T, Kawakami K, Sugawara T, Suzuki J. Transvenous copper wire insertion for dural arteriovenous malformations of cavernous sinus. *J Neurosurg* 1989;70:751-754
 17. Monsein, Debrun G, Miller R, Nauta, Chazaly J. Treatment of dural carotid-cavernous fistulas via the superior ophthalmic vein. *AJNR Am J Neuroradiol* 1991;12:435-439
 18. Hanneken A, Miller N, Debrun G, Nauta H. Treatment of carotid-cavernous fistulas using a detachable balloon catheter through the superior ophthalmic vein. *Arch Ophthalmol* 1989;107:87-92
 19. Goldberg RA, Goldey SH, Duckwiler G, Viñuela F. Management of cavernous sinus-dural fistulas: indications and techniques for primary embolization via the superior ophthalmic vein [see comments]. *Arch Ophthalmol* 1996;14:707-714
 20. Miller NR, Monsein LH, Debrun GM, Tamargo RJ, Nauta JWN. Treatment of carotid-cavernous sinus fistulas using a superior ophthalmic vein approach. *J Neurosurg* 1995;83:838-842
 21. Sergott R, Grossman R, Savino P, Bosley T, Schatz N. The syndrome of paradoxical worsening of dural-cavernous sinus arteriovenous malformations. *Ophthalmology* 1987;94:205-212
 22. Grove A. The dural shunt syndrome: pathophysiology and clinical course. *Ophthalmology* 1984;91:31-34
 23. Kupersmith M, Berenstein A, Choi I, Warren F, Flamm E. Management of nontraumatic vascular shunts involving the cavernous sinus. *Ophthalmology* 1988;95:121-130
 24. Djindjian R, Manelfe C, Picard L. Fistules artério-veineuses carotide externe-sinus caverneux: etude angiographique a propos de 6 observations et revue de la littérature. *Neurochirurgie* 1973; 19:91-110
 25. Kerber C, Newton T. The macro and microvasculature of the dura mater. *Neuroradiology* 1973;6:175-179
 26. Duckwiler G. Dural arteriovenous fistula. *Neuroimaging Clin N Am* 1992;2:291-307
 27. Keltner J, Satterfield D, Dublin A, Lee B. Dural and carotid cavernous sinus fistulas: diagnosis, management, and complications. *Ophthalmology* 1987;94:1585-1600
 28. Seeger J, Gabrielsen T, Giannotta S, Lotz P. Carotid-cavernous sinus fistulas and venous thrombosis. *AJNR Am J Neuroradiol* 1980;1:141-148
 29. Habalch V, Higashida R, Hieshima G, Wilson C, Hardin C, Kwan E. Treatment of dural fistulas involving the deep cerebral venous system. *AJNR Am J Neuroradiol* 1989;10:393-399
 30. Hieshima G. Advances in the diagnosis and treatment of carotid cavernous fistulae. *Ophthalmology* 1986;93:69
 31. Debrun G, Viñuela F, Fox A, Davis K, Ahn H. Indications for treatment and classification of 132 carotid cavernous fistulas. *Neurosurgery* 1988;22:285-289
 32. Courtheoux P, Labbe D, Hamel C, Lecoq P, Jahara M, Théron J. Treatment of bilateral spontaneous dural carotid-cavernous fistulas by coils and sclerotherapy: case report. *J Neurosurg* 1987;66: 468-470