

## Periganglionic Foraminal Steroid Injections Performed under CT Control

Hélène Zennaro, Vincent Dousset, Brigitte Viaud, Michèle Allard, Joel Dehais, Jacques Sénégas,  
and Jean-Marie Caillé

**PURPOSE:** The purpose of our study was to evaluate the efficacy of direct intraforaminal steroid injections into the periganglionic space in the treatment of radicular pain.

**METHODS:** Periganglionic infiltrations were performed in 41 patients with acute or chronic radicular pain. Neuroradiologic imaging in all patients showed foraminal stenosis due to degenerative disorders or herniated disk. All injections were performed under CT control.

**RESULTS:** Seventy percent of patients had significant pain reduction, with the greatest success (90% of patients) in those whose foraminal stenosis was due to degenerative disorders; 45% of patients with foraminal herniated disks had pain relief.

**CONCLUSION:** Intraforaminal steroid injection is useful in the treatment of radicular pain, particularly in cases of foraminal degenerative stenosis.

When treating lumbar radicular pain, in addition to the classic therapy consisting of rest, analgesics, and nonsteroidal antiinflammatory agents and muscle relaxants, local steroid injections may be indicated for patients in whom radicular pain persists. Different techniques can be used, and many investigators have discussed the use of epidural or intrathecal injections (1–5). A few authors have described their experience with periradicular injections, and in these reports the procedure was performed under fluoroscopic control (6–9). We studied the efficacy of periradicular injections of steroids and lidocaine adjacent to the dorsal root ganglion under CT control. The aim of our study was to evaluate the efficacy of this technique in the treatment of acute or chronic lumbar radicular pain due to foraminal disorders (degenerative stenosis or foraminal disk herniation).

### Methods

The study group consisted of 41 patients (23 men and 18 women), 28 to 88 years old (mean age, 58 years). Seventeen patients had radicular pain at L-3 (five patients) or L-4 (12 patients), and 24 patients had L-5 radicular pain. S-1 radicular pain was not considered in this study, since its dorsal root ganglion does not lie in a foramen. For all patients, physical examination was unremarkable, with neither sensory nor motor

deficit. The average duration of symptoms was 16 months ( $\pm 25$  months). Most patients had already had unsuccessful epidural or intrathecal injections before undergoing periganglionic infiltration. Before each procedure, the intensity of pain was graded on a scale of 0 (no pain) to 10 (maximum intensity). Another scoring evaluation was made after infiltration to assess the extent of pain reduction.

All patients underwent a neuroradiologic examination with computed tomography (CT). In 27 cases, magnetic resonance (MR) imaging was also performed. The imaging studies were analyzed by two neuroradiologists, who divided the patients into two groups: patients in group A had foraminal degenerative stenosis (21 patients) due to disk bulging, hypertrophic osteoarthritis of the zygapophyseal joint, facet subluxation, a posterior vertebral body osteophytic ridge, and ligamentum flavum hypertrophy; patients in group B had foraminal obstruction due to disk herniation (20 patients).

Steroid injections were performed under CT control with patients prone. Three-millimeter axial scans were obtained to locate the dorsal root ganglion in the intervertebral foramen. Then, after skin anesthesia with lidocaine 1%, a 22-gauge spinal needle was introduced with a posterolateral approach. Once the needle reached the lateral portion of the foramen, 75 mg of steroid (hydrocortisone), 0.8 mL of lidocaine 1%, and 0.2 mL of contrast material were injected. The injection was performed carefully, in 1 to 2 minutes, to avoid reflux along the needle. Infiltration was considered successful when pain was reproduced during injection, and when a control CT study after injection showed contrast material around the ganglion with transforaminal diffusion medially toward the epidural space (Fig 1). No complications occurred, except in one patient, who had an adverse reaction to the contrast medium, experiencing transitory cutaneous erythema immediately after injection.

All patients were examined after an average follow-up period of 9 months ( $\pm 7$  months), and all filled out a questionnaire in which they reported whether they had felt pain relief. The efficacy of infiltration was also evaluated by comparing pain scores before and after infiltration. To define the efficacy of this treatment, we compared patients' scores with the duration of symptoms, acute ( $< 3$  months) or chronic ( $\geq 3$  months) ( $\chi^2$

Received February 10, 1997; accepted after revision August 13.

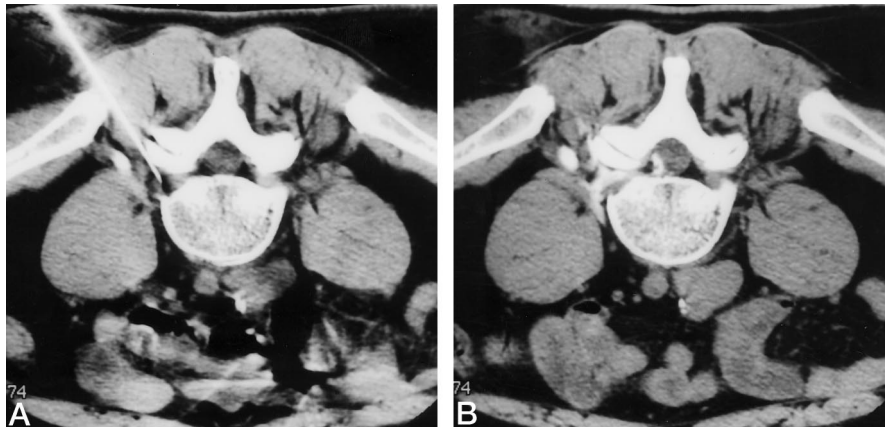
From the Departments of Neuroradiology (H.Z., V.D., B.V., M.A., J-M.C.), Rheumatology (J.D.), and Orthopedic Surgery (J.S.), Centre Hospitalo-Universitaire Pellegrin, Bordeaux, France.

Address reprint requests to Hélène Zennaro, MD, Department of Neuroradiology, Centre Hospitalo-Universitaire de Bordeaux; Hôpital Pellegrin, Place Amélie Raba Léon, 33076 Bordeaux Cedex, France.

FIG 1. Patient with L-5 radicular pain due to degenerative foraminal stenosis. Pain was completely relieved after infiltration, continuing to clinical follow-up at 5 months.

A, Control CT study before injection shows needle introduction.

B, Control CT study after injection shows periganglionic and transforaminal diffusion toward epidural space.



test corrected by the Yates method), and with the radiologic findings (degenerative stenosis or herniated disk).

### Results

Twenty-nine patients (71%) had relief of pain and 12 (29%) had either no relief or minimal pain reduction. Among the 29 patients who were relieved of pain (16 men and 13 women), the pain scores showed an average decrease of 5.6 points. Twenty-six patients had long-lasting pain relief (average follow-up of 10 months) and three had a recurrence of pain 9 months, 5 months, and 1.5 months, respectively, after infiltration, although the recurrent pain was of much lesser intensity than the initial pain. Duration of symptoms before infiltration in these patients was acute in three cases and chronic in all the others. Neuroimaging evaluation showed degenerative foraminal stenosis in 20 patients and a herniated disk in nine cases. Among the 12 patients who had no or minimal pain relief (seven men and five women), the pain score showed an average decrease of 0.08 point; 11 of these patients had no pain reduction and one patient decreased his score by 1 point. Two patients had pain relief for 24 hours, owing to the local anesthetic effect, and two had insignificant, transitory pain relief, lasting 3 weeks and 2 months, respectively. Duration of symptoms before infiltration in these patients was 17 months on average (range, 10 days to 10 years). Five patients had acute radicular pain, and all the others had chronic symptoms. Neuroradiologic examination revealed one case of degenerative stenosis and 11 disk herniations. Finally, the results indicated good efficacy when the injections were performed in patients with degenerative foraminal stenosis (95% of patients relieved). For those with foraminal herniated disks, only 45% of the patients had pain relief. We found no significant difference between chronic and acute pain in terms of the success of treatment ( $\chi^2$ -test corrected by Yates method = 3.43;  $P < .05$ ).

### Discussion

Steroid medications are commonly used for the management of radicular pain, and various injection techniques have been described (1–9). The most com-

mon site of injection is the epidural space. Injections are caudal (through the sacral hiatus) or lumbar (interspinous approach). In both cases, steroid diffusion is affected by the presence or absence of epidural ligaments or surgical scar tissue. When done blindly, this technique can result in improper needle placement in the epidural space; thus, injections should be performed under fluoroscopic control (6–9). Intrathecal injections can also be performed, but these are associated with more complications (arachnoiditis, meningeal irritation symptoms). Both epidural and intrathecal injections involve many nerve roots, so selective nerve block and reproduction of radicular pain are not possible. Only selective periradicular injections are useful for diagnosis, because they do reproduce radicular pain during needle introduction. With this technique, steroids are injected in the vicinity of the dorsal root ganglion in the intervertebral foramen.

The dorsal root ganglion plays an important role in nociceptive transmission. Many reports dealing with pain mechanisms have discussed the involvement of the dorsal root ganglion, but its precise role in pain production is still only partially understood. Therefore, numerous hypotheses have been proposed to explain the mechanisms by which it could induce radicular pain (10–13). Anatomically, the dorsal root ganglion lies within the lateral portion of the intervertebral foramen and contains the cell bodies of small unmyelinated primary afferent fibers (C fibers) and thinly myelinated primary afferent fibers. These primary sensory fibers play a major role in nociceptive transmission by conducting afferent stimuli to the spinal cord (14–17).

Some authors have proposed that radicular pain is a result of “chemical radiculitis” induced by leakage of breakdown products from a degenerating nucleus pulposus (18–21). In a recent study on radicular pain caused by disk rupture in the absence of direct spinal nerve root compression (22), the authors suggested that mucopolysaccharides released after disk rupture could induce an inflammatory reaction involving the peripheral annulus. The sensory nerve fibers contained in the outer annulus could therefore act as a

trigger zone and induce pain. Many other hypotheses have been proposed to explain radicular pain, such as autoimmune phenomena (in response to disk material) (23, 24) or neural ischemia and fibrosis due to intraforaminal venous obstruction (25). In considering the dorsal root ganglion, some reports suggest that pain may result from a pressure increase (due to intraforaminal mechanical deformation of the ganglion) arising in the tightly encapsulated ganglion. The increased pressure within the ganglion could lead to edema and ischemia, and finally to neuronal dysfunction (26–29). Another investigator (11), in reporting the findings in patients with radicular pain in whom radiologic studies revealed that the dorsal root ganglion was medially situated in the foramen (normally, its lateral position protects it from compression by a bulging disk or an enlarged facet), suggested that the dorsal root ganglion actually might interfere with pain production. When medially placed, the dorsal root ganglion becomes entrapped in a narrowed space. The patients in that study were relieved from their pain after surgical decompression of the ganglion, which suggested that the ganglion might have directly interfered with pain production, since no other radicular conflict had been demonstrated.

The precise role of the dorsal root ganglion in pain production has been studied in numerous neuroscientific reports. It has been suggested that pain may be mediated by various neurotransmitters contained in the ganglion (30–34) and then released after stimulation of sensitive afferent C fibers. These molecules involved in synaptic transmission enable the transport of neural influx from the peripheral afferent fibers to the spinal cord. In cases of repeated stimulation of sensitive afferent C fibers, all the reactions induced by these neurotransmitters are amplified, leading to a central sensitization as a result of which continuous pain occurs despite the absence of nociceptive peripheral stimulation (35–39). Repeated stimulation of C fibers is not necessarily due to repeated stimulation of their peripheral receptors: when peripheral neuronal lesions occur (originating from diskal, osseous, or ligamentous processes), wounded axons regenerate and become extremely sensitive to mechanical stimulation and acquire spontaneous activity (40). Therefore, when peripheral neural lesions occur (eg, during certain movements in degenerative foraminal stenosis), the stimulated ganglion generates ectopic neuronal activity as a result of its increased mechanosensitivity, thus leading to ongoing chronic pain. It is therefore necessary to interrupt the pain cycle, which can be done by blocking the initial primary sensory afferent influx. Because steroids have been proved to block C fiber activity (41–44), their periganglionic injection is of great potential in therapy. Other treatments that act directly on spinal neurons might also be of value, and substances other than steroids should be tested with the aim of blocking nociceptive neurotransmitters or their receptors (45).

## Conclusions

Intraforaminal infiltration produced satisfactory pain relief in 70% of patients. This technique is an interesting alternative in the treatment of radicular pain. It is most successful when pain symptoms are due to degenerative disorders (95% of such patients were relieved of pain), but in cases of spinal nerve involvement due to a herniated disk, relief is uncertain (just 45% of these patients had pain relief). In the former case, interruption of the self-maintained pain cycle caused by blocking the repeated nociceptive influx might explain the good results we obtained, whereas in the latter group, continuous stimulation was more difficult to control. In the future, testing of other substances that could block nociceptive transmission, such as specific antagonists of nociceptive neurotransmitters or of their receptors, may be of value.

## Acknowledgment

We thank Ray Cooke for his assistance in the writing of this article.

## References

1. Castagnera L, Maurette P, Pontillart V, Vital JM, Erny P, S n g s J. Long-term results of cervical epidural steroid injection with and without morphine in chronic cervical radicular pain. *Pain* 1994;58:239–243
2. Cuckler JM, Bernini PA, Wiesel SW, Booth RE, Rothman RH, Pickens GT. The use of epidural steroids in the treatment of radicular pain. *J Bone Joint Surg Am* 1985;67:63–66
3. White AH, Derby R, Wynne G. Epidural injection for the diagnosis and treatment of low-back pain. *Spine* 1980;5:78–86
4. White AH. Injection techniques for the diagnosis and treatment of low back pain. *Orthop Clin North Am* 1983;14:553–567
5. Weinstein SM, Herring SA, Derby R. Contemporary concepts in spine care: epidural steroid injections. *Spine* 1995;20:1842–1846
6. El-Khoury GY, Ehara S, Weinstein JN, Montgomery WJ, Kathol MH. Epidural steroid injection: a procedure ideally performed with fluoroscopic control. *Radiology* 1988;168:554–557
7. Morvan G, Monpoint D, Bard M, Levi-Valensin G. Direct intraforaminal injection of corticosteroids in the treatment of cervicobrachial pain. In: *Interventional Radiology in Bone and Joint*. New York, NY: Springer; 1988:253–257
8. Kidd BL, Cawley M, Ellis RE. Sinu-vertebral corticosteroid injections for sciatica without spinal pain (abstract). *Br J Rheumatol* 1988;27(Suppl 2):12
9. Bebelski B, Beranek L. Traitement par infiltration p riradiculaire des cruralgies et des sciatiques par conflit disco-radulaire. *Rev Rhum* 1989;56:795–796
10. Besson J, Guilbaud G, Abdelmounene M, Chaouch A. Physiologie de la nociception. *J Physiol Paris* 1982;78:7–107
11. Vanderlinden R. Subarticular entrapment of the dorsal root ganglia as a cause of sciatic pain. *Spine* 1984;9:19–22
12. Wall PD, Devor M. Sensory afferent impulses originate from dorsal root ganglia as well as from periphery in normal and nerve injured rats. *Pain* 1983;17:321–339
13. Weinstein J. Mechanisms of spinal pain: the dorsal root ganglion and its role as a mediator of low back pain. *Spine* 1986;11:999–1001
14. Fields H. Les voies de la douleur dans le syst me nerveux central. In: *Douleur*. Paris, France: Medsi/McGraw-Hill; 1987:12–118
15. Grant G. Primary afferent projections to the spinal cord. In: *The Rat Nervous System*. 2nd ed. San Diego, Calif: Academic Press; 1995:61–66
16. McMahon S, Koltzenburg M. The changing role of primary afferent neurons in pain. *Pain* 1990;43:269–272
17. Melzack R, Wall PD. Pain mechanism: a new theory. *Science* 1965;150:971–979
18. Jaffray D, O'Brien J. Isolated intervertebral disc resorption: a source of mechanical and inflammatory back pain. *Spine* 1986;11:397–401

19. McCarron RF, Wimpee MW, Hudgkins PG, et al. **The inflammatory effect of the nucleus pulposus.** *Spine* 1987;12:759-764
20. Marshall LL, Trethewie ER. **Chemical irritation of nerve root in disc prolapse.** *Lancet* 1973;2:320-322
21. Marshall LL, Trethewie ER, Curtain CC. **Chemical radiculitis: chemical, physiological and immunological study.** *Clin Orthop* 1977;129:61-67
22. Millette PC, Fontaine S, Lepanto L, Breton G. **Radiating pain to the lower extremities caused by lumbar disk rupture without spinal nerve root involvement.** *AJNR Am J Neuroradiol* 1995;16:1605-1613
23. Naylor A, Happey F, Turner RL, West DC. **Enzymatic and immunological activity in the intervertebral disc.** *Orthop Clin North Am* 1975;6:51-58
24. Gertzbein S, Tile M, Gross A, Falk K. **Autoimmunity in degenerative diseases of the lumbar spine.** *Orthop Clin North Am* 1975;6:67-73
25. Hoyland J, Freemont A, Jayson M. **Intervertebral foramen venous obstruction: a cause of periradicular fibrosis?** *Spine* 1989;14:558-568
26. Macnab I, MacCulloch J. **Soft tissue lesions.** In: *Backache*. 2nd ed. Baltimore, Md: Williams & Wilkins; 1990:140-147
27. Rydevik B, Brown M, Lundborg G. **Pathoanatomy and pathophysiology of nerve root compression.** *Spine* 1984;9:7-15
28. Rydevik B, Myers R, Powell H. **Pressure increase in the dorsal root ganglion following mechanical compression: closed compartment syndrome in nerve roots.** *Spine* 1989;14:574-576
29. Olmarker K, Rydevik B, Holm S. **Edema formation in spinal nerve roots by experimental, graded compression: an experimental study on the pig cauda equina with special references to differences in effects between rapid and slow onset of compression.** *Spine* 1989;14:569-573
30. Dray A, Urban L, Dickenson A. **Pharmacology of chronic pain.** *Trends Pharmacol Sci* 1994;15:190-197
31. Besson J, Chaouch A. **Peripheral and spinal mechanisms of nociception.** *Physiol Rev* 1987;67:67-186
32. Cuello A. **Peptides as neuromodulators in primary sensory neurons.** *Neuropharmacology* 1987;26:971-979
33. Igwe O, Larson A. **Role of substance P amino terminal metabolites in substance P-induced desensitization in mice.** *Neuroscience* 1990;36:535-542
34. Levine J, Fields H, Basbaum A. **Peptides and the primary afferent nociceptor.** *J Neurosci* 1993;13:2273-2286
35. Urban L, Thompson S, Dray A. **Modulation of spinal excitability: cooperation between neurokinin and excitatory amino acid neurotransmitters.** *Trends Neuro Sci* 1994;17:432-438
36. Woolf C. **Evidence of a central component of post-injury pain hypersensitivity.** *Nature* 1983;306:686-688
37. Woolf C. **Recent advances in the pathophysiology of acute pain.** *Br J Anaesth* 1989;63:139-146
38. Woolf C, Thomson S. **The induction and maintenance of central sensitization is dependent on N-methyl-D-aspartic-acid receptor activation: implications for treatment of post-injury hypersensitivity states.** *Pain* 1991;44:293-299
39. Yamamoto T, Yaksh T. **Spinal pharmacology of thermal hyperesthesia induced by constriction injury of sciatic nerve: excitatory amino acid antagonists.** *Pain* 1992;49:121-128
40. Howe JF, Loeser JD, Calvin WH. **Mechanosensitivity of dorsal root ganglia and chronically injured axons: a physiological basis for the radicular pain of nerve root compression.** *Pain* 1977;3:25-41
41. Johansson A, Hao J, Sjolund B. **Local corticosteroid application blocks transmission in normal nociceptive C-fibers.** *Acta Anaesthesiol Scand* 1990;34:335-338
42. Devor M, Gorvrin-Lippmann R, Raber P. **Corticosteroids suppress ectopic neuronal discharge originating in experimental neuromas.** *Pain* 1985;22:127-137
43. Jurna I, Brune K. **Central effect of the non-steroid anti-inflammatory agents, indometacin, ibuprofen, and diclofenac, determined in C fibre-evoked activity in single neurons of the rat thalamus.** *Pain* 1990;41:71-80
44. McCormack K. **Non-steroidal anti-inflammatory drugs and spinal nociceptive processing.** *Pain* 1994;59:9-43
45. Dickenson AH. **A cure for wind-up: NMDA receptor antagonists as potential analgesics.** *Trends Pharmacol Sci* 1990;11:307-309

Please see the Commentary on page 353 in this issue.