

# Power Doppler Sonography of Cervical Lymph Nodes in Patients with Head and Neck Cancer

Yoshiko Ariji, Yasuo Kimura, Nobuyuki Hayashi, Tetsuro Onitsuka, Koichi Yonetsu, Kuniaki Hayashi, Eiichiro Ariji, Toshimitsu Kobayashi, and Takashi Nakamura

**PURPOSE:** The purpose of this preliminary study was to evaluate the usefulness of power Doppler sonography in differentiating metastatic from nonmetastatic cervical lymph nodes in patients with cancer.

**METHODS:** Histologically proved metastatic (n = 71) and nonmetastatic (n = 220) lymph nodes were examined with power Doppler sonography in 77 patients with head and neck cancer. Power Doppler sonography was assessed for its ability to differentiate metastatic from nonmetastatic lymph nodes.

**RESULTS:** Power Doppler sonography showed characteristic features of parenchymal blood flow signal in 59 (83%) of the 71 metastatic lymph nodes. By contrast, only four (2%) of the 220 nonmetastatic nodes showed these power Doppler signals. In addition, power Doppler sonography showed high levels of sensitivity (83%) and specificity (98%) in depicting metastatic lymph nodes, which were superior to the values (66% sensitivity and 92% specificity) obtained by applying size criteria (transverse to longitudinal ratio). However, a combination of the two criteria (parenchymal color signal and transverse to longitudinal ratio) improved diagnostic accuracy to 92% sensitivity and 100% specificity.

**CONCLUSION:** Our preliminary findings suggest that the power Doppler criteria of no hilar flow, peripheral parenchymal nodal flow, and a transverse to longitudinal ratio of more than 0.65 together constitute a powerful tool for depicting metastatic lymph nodes in patients with cancer.

The presence of cervical lymph node metastasis in patients with cancer of the oral cavity or other head and neck regions is an important prognostic determinant in staging cancers and in planning radiation therapy. In this regard, the presence of one or more metastatic lymph nodes in the ipsilateral or contralateral side of the neck, or both, reduces the 5-year survival rate by about 50% (1). Increasing evidence of lymph node metastasis has been accumulating as we gain more experience with computed tomography (CT), magnetic resonance (MR) imaging, and sonography in the examination of cancer patients (2). Recent reports have shown that assessment of nodal blood flow by Doppler sonography may serve as an adjunct to these other imaging techniques in the iden-

tification of metastatic lymph nodes in cancer patients (3, 4).

Power Doppler sonography was first introduced by Rubin et al (5). It is essentially angle-independent and has a greater dynamic range than conventional color Doppler sonography, which increases its sensitivity. Since its introduction, power Doppler sonography has been found capable of depicting blood flow in the kidney and orbit and to show hyperemia (6-8), and its usefulness as an adjunct to gray-scale sonography and its superiority over conventional Doppler sonography have been confirmed.

The extended dynamic range of power Doppler sonography may enhance visibility of the microvasculature of the lymph nodes. Our goal was to evaluate the efficacy of power Doppler sonography in depicting metastatic cervical lymph nodes in patients with head and neck cancers.

## Methods

### *Subjects and Examination Procedures*

Seventy-seven patients with head and neck cancer were studied prospectively to assess a total of 71 metastatic and 220 nonmetastatic cervical lymph nodes. Sixty-six patients had squamous cell carcinomas and the others had mucoepidermoid

---

Received May 19, 1997; accepted after revision July 28.

From the Department of Radiology and Cancer Biology (Y.A., Y.K., K.Y., E.A., T.N.), Nagasaki (Japan) University School of Dentistry, and the Departments of Radiology (N.H., K.H.) and Otolaryngology (T.O., T.K.), Nagasaki University School of Medicine.

Address reprint requests to Takashi Nakamura, DDS, PhD, Department of Radiology and Cancer Biology, Nagasaki University School of Dentistry, 1-7-1 Sakamoto, Nagasaki 852, Japan.

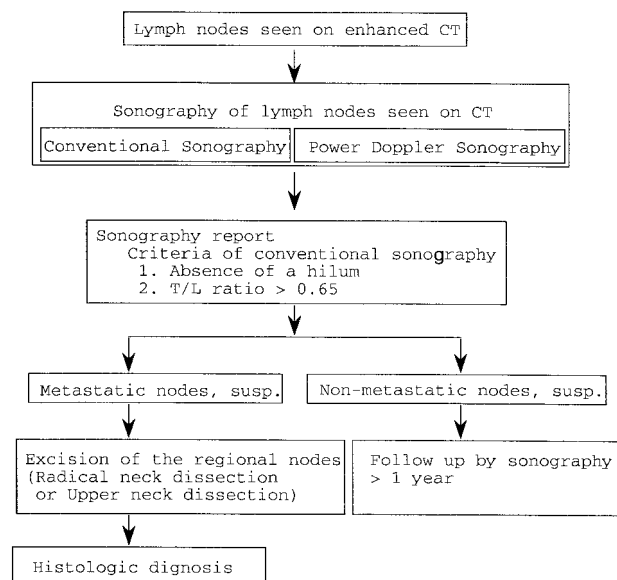


Fig 1. Flow chart shows the procedure for examining cervical lymph nodes in patients with head and neck cancer. See text for details.

carcinomas (n = 4), adenocarcinomas (n = 3), adenoid cystic carcinomas (n = 2), and papillary carcinomas (n = 2). The study population included four patients with proved metastatic nodes bilaterally. All patients in whom neck dissections had been planned were included in the study, and all had CT and sonography. Informed consent was obtained from all participants.

Examination procedures are summarized in Figure 1. First, lymph nodes were surveyed by CT, after which, the large nodes were studied by both conventional and power Doppler sonography. Metastatic lymph nodes were confirmed by histopathologic examination of the excised specimen. To ensure that the node removed surgically during a neck dissection was the same as the node seen at sonography, we performed a series of maneuvers. First, large nodes seen on CT scans were numbered sequentially from the most cephalad to the most caudal. Then, each of these nodes was examined by sonography. During a sonographic examination, additional abnormal nodes, distinguished by their size and/or absent hilum (9, 10), were sometimes found. In such cases, we renumbered the large or abnormal nodes that had been diagnosed at conventional sonography, and reported our findings to the surgeons. The sonographic report thus included data concerning the approximate location, size (transverse to longitudinal ratio determined at sonography), and internal structure (such as the presence or absence of the hilum) of the nodes (Fig 2). These features seen at conventional sonography have been reported to be important in determining the presence of metastatic lymph nodes (10). The sonographic report also included the radiologist's suppositions regarding nodal malignancy. On the basis of the report, surgeons decided which of the procedures, radical or supraomohyoid dissection, should be performed. At surgery, the lymph nodes were excised en bloc along with the adjacent reference structures to more easily ascertain the spatial relationship between the excised nodes and the surrounding structures, such as muscles, salivary glands, and veins. The size of the node was also used to compare the excised node with the image. Just after removal, the excised lymph nodes were compared with those studied sonographically. Surgeons and at least one of the radiologists together compared the excised nodes with the nodes studied sonographically, and a final decision was reached by consensus. The excised nodes that matched those on the sonograms were then examined histolog-

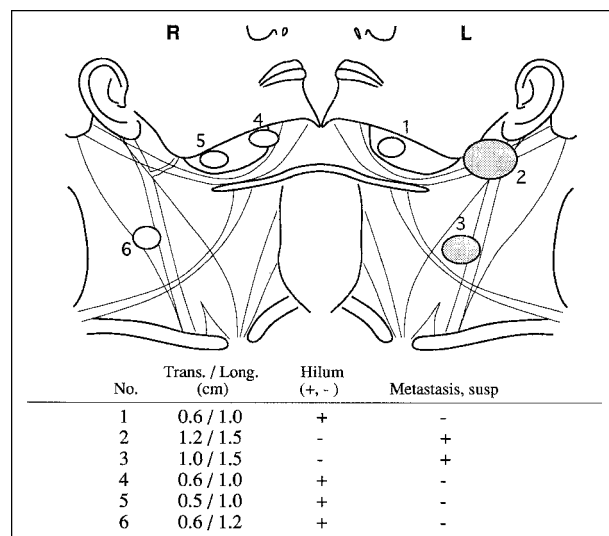


Fig 2. Representative report of sonographic examination. In this patient, a 39-year-old man, six large nodes were seen at CT. Sonography showed that lymph nodes 2 and 3 (hatched areas) were metastatic, since these nodes had an increased transverse to longitudinal ratio (>0.65) and lacked a hilum.

ically. We were able to match all the large lymph nodes detected on CT scans to the corresponding excised nodes.

Nodes found to be large at CT but that were considered negative for cancer at power Doppler sonography were judged to be nonmetastatic if they did not increase in size during the follow-up period and if no therapy, such as irradiation, had been performed (10). Therefore, in the present study, large nodes on the side opposite the metastatic lymph node(s) were considered inflammatory or reactive when no untoward features developed during 1 year of follow-up from the initial examination or surgery. During the follow-up periods, these lymph nodes were periodically examined by sonography. Thus, the nonmetastatic lymph node group included those that were seen at CT but not excised and whose nonmalignant nature was confirmed sonographically at the 1-year follow-up or those that were excised and proved histologically to be nonmetastatic. No patient received radiation therapy during the follow-up periods.

#### Power Doppler Sonography

Conventional and power Doppler sonography were performed using a Logiq 500 (GE Yokogawa Medical Systems, Tokyo, Japan) unit equipped with a 6.5-MHz wide-bandwidth (range, 4 to 9 MHz) transducer. The Doppler settings were chosen to optimize detection of the signals and the low Doppler shift frequencies expected from the lymph node vessels with low-velocity flow. The settings were as follows: color gain, 20 dB; dynamic range, 66 dB; and Doppler scale, 0.04 m/s. The lymph nodes were classified as hilar, parenchymal, or as showing no color signals. On sonograms, the parenchyma appears homogeneous in texture because of its exclusively predominant component of solid tissues with few lymph sinuses (10). On the other hand, the hilum is seen as an echogenic structure in the node because of its abundance of lipocytes. The hilar signal was detected as Y-shaped or club-shaped color signals invading the hilar region of the lymph node (Fig 3A). The parenchymal signals were seen as multiple, variably colored signals scattered in the parenchyma of the lymph node (Fig 3B).

The classification was done independently by two investigators using real-time images of power Doppler sonograms of the lymph nodes. Locations of color signals indicative of blood vessels in the lymph nodes were carefully confirmed by shifting

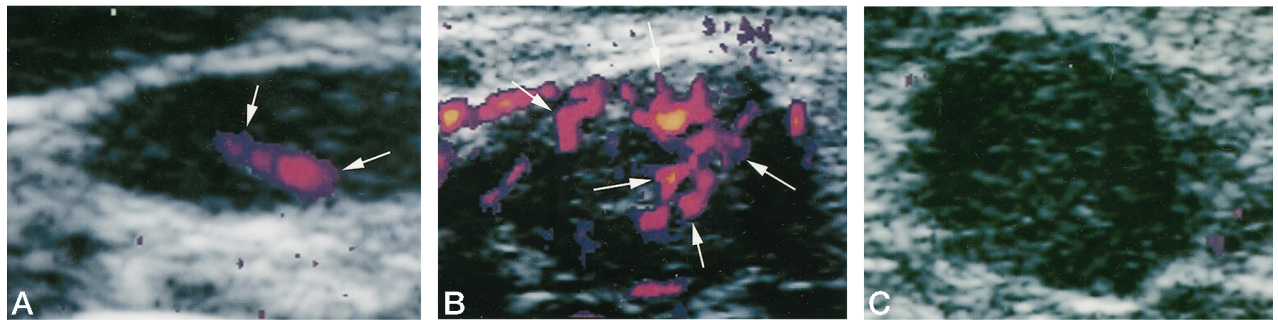


FIG 3. Power Doppler sonographic features of metastatic and nonmetastatic cervical lymph nodes.  
 A, Inflammatory lymph node shows color gains in the hilar region (arrows indicate blood flow signal).  
 B, Metastatic lymph node shows parenchymal color gains (arrows indicate blood flow signal).  
 C, Metastatic lymph node shows no color gain.

and tilting the probe so that extranodal vessels might not be misinterpreted as intranodal vessels. The transverse to longitudinal ratio of the lymph nodes was measured directly on the sonographic display equipment, as previously described (10). Most normal nodes in the jugular and spinal accessory chain are oval or kidney shaped, with a long axis often oriented vertically along the long axis of the neck. When a node is replaced by tumor, it becomes more spherical, thus raising the transverse to longitudinal ratio closer to 1.0.

#### CT

CT examinations were performed on a Somatom DR (Siemens, Erlangen, Germany) unit with patients in the supine position. Axial scans were obtained contiguously with a section thickness of 4 mm and the scan plane parallel to the inferior margin of the mandible. CT examinations were performed after patients received an intravenous injection, via rapid drip, of 100 mL of contrast medium (Iopamiron 300, Schering). We classified the lymph nodes detectable on CT scans as "large," as they were more than 5 mm in diameter.

#### Data Analysis

Fisher's discrimination analysis was used to evaluate the sensitivity and specificity of the different imaging techniques and criteria for the detection of metastasis. Sensitivity and specificity were assessed by the following formulas: sensitivity =  $A/F$  (%) and specificity =  $B/NF$  (%), where A is the number of correctly diagnosed metastatic lymph nodes, B is the number of correctly diagnosed nonmetastatic lymph nodes, F is the total number of metastatic lymph nodes, and NF is the total number of nonmetastatic lymph nodes.

#### Results

Power Doppler sonograms showed color signal in the hilar regions only in the nonmetastatic lymph nodes (Fig 3A). Conversely, in the metastatic lymph nodes, the color signal never appeared in the hilar region but rather was apparent predominantly in the parenchyma of the nodes (Fig 3B). However, four (2%) of the 220 nonmetastatic lymph nodes showed color signal in the parenchyma. Forty-one (19%) of 220 nonmetastatic lymph nodes and 12 (17%) of 71 metastatic lymph nodes showed no color signal on the power Doppler images (Fig 3C). Of these 12, three were found to have necrotic areas in the central portion of the nodes, as determined by histopathologic examination.

We further assessed the diagnostic capability of power Doppler sonography in depicting metastatic lymph nodes by calculating sensitivity and specificity. When metastasis was diagnosed on the basis of the presence of parenchymal color signal, sensitivity was 83% and specificity 98%.

We next tested whether size, as determined on sonograms, could help distinguish metastatic from nonmetastatic cervical lymph nodes. In this regard, we compared the diagnostic ability of power Doppler sonography with that of transverse to longitudinal ratios in depicting metastatic lymph nodes. We calculated sensitivity and specificity by classifying lymph nodes with transverse to longitudinal ratios greater than 0.65 as metastatic, since this threshold provided the best diagnostic accuracy. Sensitivity and specificity based on the transverse to longitudinal ratio were 66% and 92%, respectively. However, when the node was classified as metastatic on the basis of both peripheral parenchymal flow on power Doppler sonograms and a transverse to longitudinal ratio greater than 0.65, diagnostic accuracy improved substantially, reaching 92% sensitivity and 100% specificity.

#### Discussion

In our preliminary study, metastatic cervical lymph nodes showed characteristic blood flow patterns in the parenchyma on power Doppler sonograms. This parenchymal blood flow appeared infrequently in nonmetastatic lymph nodes in patients with cancer. However, 17% of the metastatic lymph nodes and 19% of the nonmetastatic lymph nodes showed no color signals, indicating that power Doppler sonography has an apparent limitation in differentiating metastatic from nonmetastatic nodes.

Accurate differentiation of metastatic from nonmetastatic lymph nodes has long been a primary focus of surgeons and radiologists who treat and diagnose cancer patients. Several attempts have been made to achieve this goal. Van den Brekel et al (9) proposed that the minimum diameter of lymph nodes on axial CT scans was one of the most accurate size criteria for predicting lymph node metastasis. High-resolution sonography was thought to be another tool for the detection of metastatic lymph nodes, and this was



partly substantiated by the observation of Vassallo et al (10), who showed that an increased transverse to longitudinal ratio and eccentric widening of the nodal cortex were useful structural parameters for differentiating benign from malignant nodes.

Differentiation of benign from malignant cervical lymph nodes has also been attempted with color Doppler sonography. In one study (4), color Doppler flow patterns were found to be abnormal in both benign (19%) and malignant (81%) lymph nodes, suggesting that the clinical value of color Doppler sonography is limited in making this differentiation. The study also showed that 51% of the lymph node metastases from head and neck cancers had abnormal flow patterns. By contrast, we found in the present study that 59 (83%) of 71 malignant lymph nodes that had metastasized from head and neck cancers exhibited abnormal (parenchymal) color signals. This discrepancy may be due to the extended dynamic range of power Doppler sonography relative to that of conventional Doppler sonography (5), with a resultant increase in sensitivity for depicting increased flow in metastatic lymph nodes.

By analyzing the spectral waveform, Steinkamp et al (3) and, more recently, Choi et al (11) appraised the clinical usefulness of color Doppler sonography in differentiating superficial lymph nodes involved in metastasis from those affected by benign disease. They showed that the resistive index was significantly higher in the metastatic than in the benign lymph nodes, and they proposed that this difference was due to compression by tumor cells of vessels in the lymph node and/or tumor-evoked angiogenesis. On the other hand, vessels were dilated in the nonmetastatic lymph nodes. Our results obtained with power Doppler sonography were consistent with these studies and showed that abnormal (parenchymal) blood flow signals, which may represent an additional angiogenesis in response to the infiltrating tumor cells, were characteristic of metastatic lymph nodes. However, these abnormal blood flow signals appeared infrequently in the nonmetastatic nodes as well. On the other hand, dilated vessels in the hilar region were characteristic of the nonmetastatic lymph nodes. Steinkamp et al (3) further stated that nonmetastatic lymph nodes showed greater hilar blood flow whereas metastatic nodes showed increased peripheral blood flow. Therefore, taken together with our study, these results indicate that increased parenchymal blood flow is an effective clinical hallmark highly suggestive of lymph node metastasis.

In one study with sonographically guided fine-needle aspiration biopsy (FNAB), sensitivity was 98% and specificity 95% for differentiating metastatic from nonmetastatic lymph nodes (12). A subsequent multicenter study found a sensitivity of 77% and a specificity of 100% (13). The present study with power Doppler sonography showed comparable results, with a sensitivity of 83% and a specificity of 98%. However, our study may contain pitfalls in that our patient population was relatively small. An increased number of subjects may result in a lower

sensitivity or specificity. A study population with a greater number of patients with advanced metastatic lymph nodes will result in a higher sensitivity for the method. On the other hand, a study population with more patients with nonmetastatic lymph nodes will result in a lower sensitivity (13). Since our study population consisted of a relatively high proportion of patients with nonmetastatic lymph nodes, it is unlikely that the obtained high sensitivity and specificity were overestimations.

Finally, it is noteworthy that 12 (17%) of 71 metastatic lymph nodes showed no apparent color signal on power Doppler sonograms, suggesting a limitation of power Doppler sonography in differentiating metastatic from nonmetastatic nodes. Similar results were reported previously with color Doppler sonography, which showed that blood flow was not detectable in 23% of the metastatic lymph nodes from squamous cell carcinomas (4). These findings indicate that, in an early stage, destruction of the organ vessels and the subsequent angiogenesis have not occurred, and the tumor is still fed by the host organ vessels even when invading tumor cells have already enlarged the host lymph nodes (3). Additional limitations of sonography of the neck nodes relative to CT include 1) inability to show retropharyngeal and tracheoesophageal groove nodes, 2) inability to show extracapsular spread, 3) occasional difficulty in showing a specific node relative to adjacent reference structures for the surgeon, and 4) difficulty in determining whether the node is the same or a different one at follow-up scanning.

Our follow-up period for nonmetastatic nodes was 1 year. We do not think that a 1-year follow-up is long enough; however, this study was a preliminary report, and a 2- to 5-year disease-free follow-up is required to obtain more reliable results.

## Conclusion

This preliminary study suggests that power Doppler sonography may be a powerful diagnostic tool for identifying metastatic superficial cervical lymph nodes in patients with head and neck cancer. However, other sonographic criteria, such as the transverse to longitudinal ratio of the lymph node, should be considered simultaneously for accurate diagnosis of metastasis. Therefore, we propose the following power Doppler (or sonographic) criteria for establishing metastatic cervical lymph nodes: 1) no hilar flow, 2) peripheral parenchymal nodal flow, and 3) a transverse to longitudinal ratio of more than 0.65.

## References

1. Farr HW, Goldfarb PM, Farr CM. **Epidermoid carcinoma of the mouth and pharynx at Memorial Sloan-Kettering Cancer Center: 1965 to 1969.** *Am J Surg* 1980;140:563-567
2. van den Brekel MWM, Castelijns JA, Snow GB. **Detection of lymph node metastases in the neck: radiologic criteria.** *Radiology* 1994; 192:617-618
3. Steinkamp HJ, Mäuer J, Cornehl M, Knöbber D, Hettwer H, Felix R. **Recurrent cervical lymphadenopathy: differential diagnosis**

- with color-duplex sonography. *Eur Arch Otorhinolaryngol* 1994;251:404-409
4. Chang D-B, Yuan A, Yu C-J, Luh K-T, Kuo S-H, Yang P-C. **Differentiation of benign and malignant cervical lymph nodes with color Doppler sonography.** *AJR Am J Roentgenol* 1994;162:965-968
  5. Rubin LM, Bude RO, Carson PL, Bree BL, Adler RS. **Power Doppler US: a potentially useful alternative to mean frequency-based color Doppler US.** *Radiology* 1994;190:853-856
  6. Bude RO, Rubin JM, Adler RS. **Power versus conventional color Doppler sonography: comparison in the depiction of normal intrarenal vasculature.** *Radiology* 1994;192:777-780
  7. Giovagnorio F, Quaranta L. **Power Doppler sonography enhances visualization of orbital vessels.** *J Ultrasound Med* 1995;14:837-842
  8. Newman JS, Adler RS, Bude RO, Rubin JM. **Detection of soft-tissue hyperemia: value of power Doppler sonography.** *AJR Am J Roentgenol* 1994;163:385-389
  9. van den Brekel MWM, Stel HV, Castelijns JA, et al. **Cervical lymph node metastasis: assessment of radiologic criteria.** *Radiology* 1990;177:379-384
  10. Vassallo P, Wernecke K, Roos N, Peters PE. **Differentiation of benign from malignant superficial lymphadenopathy: the role of high-resolution US.** *Radiology* 1992;183:215-220
  11. Choi MY, Lee JW, Jang LJ. **Distinction between benign and malignant causes of cervical, axillary, and inguinal lymphadenopathy: value of Doppler spectral waveform analysis.** *AJR Am J Roentgenol* 1995;165:981-984
  12. Baatenburg de Jong RJ, Rongen RJ, Verwoerd CD, van Overhagen H, Lameris JS, Knecht P. **Ultrasound-guided fine-needle aspiration biopsy of neck nodes.** *Arch Otolaryngol Head Neck Surg* 1991;117:402-404
  13. Takes RP, Knecht P, Manni JJ, et al. **Regional metastasis in head and neck squamous cell carcinoma: revised value of US with US-guided FNAB.** *Radiology* 1996;198:819-823