

T1 and T2 Alterations in the Brains of Patients with Hepatic Cirrhosis

Josef Vymazal, Milan Babis, Rodney A. Brooks, Karel Filip, Monika Dezortova, Halima Hrnckova, and Milan Hajek

PURPOSE: To determine whether previously reported T1-weighted MR hyperintensities in the brains of patients with hepatic cirrhosis are accompanied by changes in T2. **METHODS:** We measured T1 and T2 in the brains of 10 patients with chronic liver disease and 7 age-matched healthy volunteers, using classic spin-echo sequences with multiple saturation recovery times and multiple echoes. **RESULTS:** Both T1 and T2 were shortened in the basal ganglia, cortex, and white matter of the patients, with the greatest shortening in the globus pallidus, where $1/T1$ was increased by 0.76 s^{-1} or 74%, and $1/T2$ by 1.45 s^{-1} or 11%. **CONCLUSIONS:** The T1 changes were accompanied by T2 changes of greater magnitude that were not as visible because T2 is normally much shorter than T1, especially in the globus pallidus.

Index terms: Liver; Brain, magnetic resonance

AJNR Am J Neuroradiol 17:333-336, February 1996

There have been reports of radiologic (computed tomography [CT] and magnetic resonance [MR] imaging) changes in the brains of patients with chronic liver disease, beginning with reports of morphologic change, such as atrophy (1, 2). MR studies have revealed alterations in signal intensity, such as T2-weighted hyperintensity in the dentate nucleus (3), but mostly T1-weighted hyperintensity in the basal ganglia, particularly in the globus pallidus (4-10). These signal changes do not necessarily correlate with atrophy (10) or with the presence of acquired hepatocerebral degeneration (8). It has been suggested that the MR changes may precede the emergence of neurologic symptoms or reflect the presence of a subclinical hepatic encephalopathy (8). The sometimes transient character of the lesion appears to exclude gross morphologic changes, although an

increase in protoplasmic astrocytes has been reported (11). The MR changes are generally thought to arise from T1 shortening caused by some (possibly paramagnetic) substance, perhaps shunted away from the liver. Similar changes have been seen in patients receiving hyperalimentation therapy (12). Despite the widespread interest, we know of no direct measurements of T1 or reports of T2 shortening (which necessarily accompanies T1 shortening), except for small localized T2 changes that were attributed to calcification (4). Therefore, we measured both T1 and T2 in the basal ganglia of patients with chronic liver disease to see if T2 shortening is present and to compare its magnitude with the T1 shortening.

Materials and Methods

Ten patients (54 ± 13 years old) with hepatic cirrhosis of alcoholic or hepatitic origin were studied. All were candidates for liver transplantation, which was subsequently performed in some cases. Seven age-matched healthy volunteers (49 ± 10 years old) were also studied. The MR images were obtained on a 1.5-T scanner equipped with a head coil. A single 5-mm section at the level of the basal ganglia was scanned with classic spin-echo sequences as follows: For T1 determination, six T1-weighted sequences (100/22, 200/22, 400/22, 600/22, 1000/22, and 1500/22 [repetition time/echo time]) were used with one excitation and a field of view of 208×208 mm and a matrix of 256×256 . For T2 determination, a multiecho T2-weighted sequence was used (16 echoes: 2000/22,

Received May 19, 1995; accepted after revision August 4.

Supported in part by grants 1052-S and 1477-5 of IGA MZ, the Czech Republic.

From the Neuroimaging Branch, NINDS, National Institutes of Health, Bethesda, Md (J.V., R.A.B.); the Institute of Clinical and Experimental Medicine, Prague, the Czech Republic (M.B., K.F., H.H., M.H.); and the MR Unit, Clinic of Radiology, 10000 Third Medical School, Charles University, Prague, the Czech Republic (M.D.).

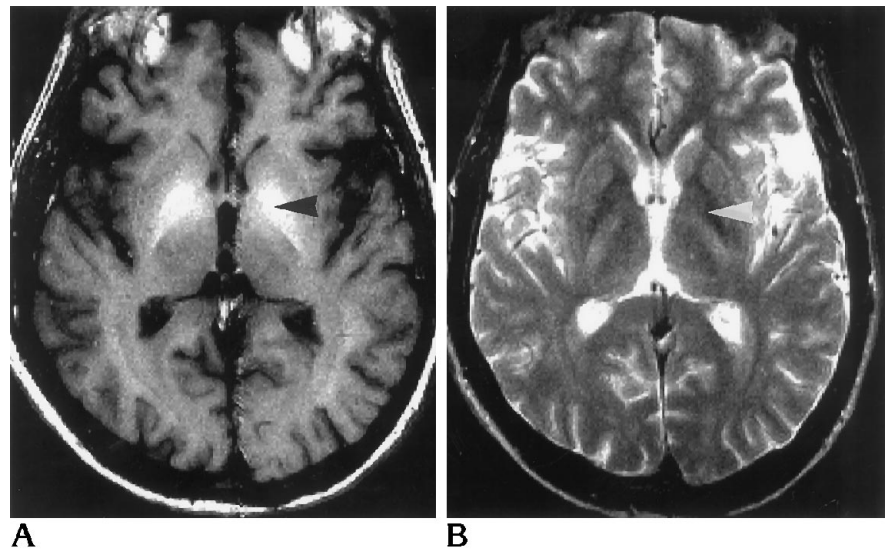
Address reprint requests to Rodney A. Brooks, MD, Mail Station 1178, National Institutes of Health, Bethesda, MD 20892.

AJNR 17:333-336, Feb 1996 0195-6108/96/1702-0333

© American Society of Neuroradiology

Fig 1. MR images in a patient with hepatic cirrhosis.

A and B, On T1-weighted (400/22) (A) and T2-weighted (2000/80) (B) images, T1 effect is evident in globus pallidus but T2 effect is masked by normal hypointensity (arrowheads).



Average Relaxation Times (ms) and Rates (s^{-1}), with Standard Deviations (in Parentheses)

Relaxation Time/ Rate	Caudate	Putamen	Pallidum	Thalamus	White Matter
T1					
Patients	1075 (185)	950 (145)	560 (120)	900 (155)	570 (82)
Control subjects	1615 (310)	1370 (244)	970 (150)	1135 (168)	770 (47)
Difference	540	420	410	235	200
1/T1					
Patients	0.93 (0.16)	1.05 (0.16)	1.79 (0.38)	1.11 (0.19)	1.75 (0.25)
Control subjects	0.62 (0.12)	0.73 (0.13)	1.03 (0.16)	0.88 (0.13)	1.30 (0.08)
Difference	0.31	0.32	0.76	0.23	0.46
T2					
Patients	84 (2)	75 (2)	66 (5)	77 (3)	75 (6)
Control subjects	90 (6)	83 (4)	73 (3)	85 (6)	80 (3)
Difference	6	8	7	8	5
1/T2					
Patients	11.90 (0.28)	13.33 (0.36)	15.15 (1.15)	12.99 (0.51)	13.33 (1.07)
Control subjects	11.11 (0.74)	12.05 (0.58)	13.70 (0.56)	11.63 (0.81)	12.50 (0.47)
Difference	0.79	1.28	1.45	1.36	0.83

40, 60, . . . 320) with two excitations and a field of view of 224×224 mm and a matrix of 256×256 . No saturation pulses were applied to eliminate flow effects. Values of T1 and T2 were calculated for regions of interest 5 mm in diameter (about 30 pixels) in the white matter, caudate, putamen, pallidum, and thalamus. T1 was calculated by curve-fitting the six saturation recovery points with an exponential function, whereas T2 was determined directly from a T2 map calculated by the scanner software from the 16-echo sequence. Differences between populations were evaluated statistically with a two-tailed Student's *t* test. A "T1/T2 alteration ratio" was also calculated, which was defined as the difference in the relaxation rate $1/T1$ between the patients and the volunteers divided by the corresponding difference in $1/T2$.

Results

Figure 1 shows T1-weighted and T2-weighted images of a patient with hepatic cirrhosis. The calculated relaxation times and rates are shown in the Table. Note that $1/T1$ for the patients is increased significantly (ie, T1 is reduced) compared with that for the control subjects. The increase in the globus pallidus, 0.76 s^{-1} is twice as great as in the other regions. Also, $1/T2$ is increased in all regions, with the globus pallidus again showing the greatest effect, 1.45 s^{-1} . This is not visually evident on the T2-weighted images because it is masked by the normal T2 shortening caused by iron accumulation. All differences were significant at the $P = .05$ level except for T2 of white matter.

The T1/T2 alteration ratio (the change in $1/T1$ divided by the change in $1/T2$) was 0.52 in the globus pallidus, 0.39 in the caudate, 0.25 in the putamen, and 0.17 in the thalamus. In the white matter it was 0.55.

Discussion

T1 and T2 are often affected by the same relaxation mechanisms. In particular, any substance or process that shortens T1 must also shorten T2, although the converse is not true. The effect is described quantitatively as an additive contribution to $1/T1$ or $1/T2$, the latter of which must theoretically be at least as great as the former. Therefore, it is not surprising that we found a contribution to $1/T2$ that is greater than the corresponding T1 effect by a factor of two or more. The reason the T2 shortening is not visually noticeable is because T2 throughout the brain is normally very short, especially in the globus pallidus.

The relative magnitude of the T1 and T2 shortening may be useful in evaluating possible mechanisms, although one must be wary of comparing in vitro and in vivo data, since diffusion rates and chemical forms may be different. A number of suggested agents may be found in the literature, although usually without any supporting pathologic data. One such possibility is ammonia, for which a correlation between plasma ammonia level and hyperintensity in the globus pallidus was found (7); however, ammonia is not paramagnetic and would produce negligible relaxation unless present in huge concentrations. Copper (13), which is paramagnetic, can also probably be ruled out because its magnetic moment is so small as to barely affect T1 and T2 (14), even in concentrations as large as 0.4 mg/g, found in Wilson disease. Iron in the form of ferritin has a strong effect in the normal brain, but the in vivo T1/T2 alteration ratio is 0.07 (15), much lower than the present results. A more compatible possibility is phospholipids (5), which may be responsible for T1 shortening in the normal neurohypophysis (16); measurements in suspensions of phospholipid vesicles (simulating tissue) yielded a T1/T2 alteration ratio of about 0.6 at 1.5 T (17), not much different from our results. Another possibility is manganese, which is elevated in the blood of patients with liver disease (18), accumulates preferentially in the globus pallidus and pituitary gland (19), and may cause T1 shortening in the globus pallidus of patients receiving hyperalimentation therapy (13). Although ionic manganese has a very low T1/T2 alteration ratio (0.08) in solution, chelated manganese would be compatible with our findings (14).

References

- Bernthal P, Hays A, Tarter RE, Van Thiel D, Lecky J, Hegedus A. Cerebral CT scan abnormalities in cholestatic and hepatocellular disease and their relationship to neuropsychologic test performance. *Hepatology* 1987;7:107-114
- Moore JW, Dunk AA, Crawford JR, et al. Neuropsychological deficits and morphological MRI brain scan abnormalities in apparently healthy non-encephalopathic patients with cirrhosis. *J Hepatol* 1989;9:319-325
- Hanner JS, Li KCP, Davis GL. Acquired hepatocerebral degeneration: MR similarity with Wilson disease. *J Comput Assist Tomogr* 1988;12:1076-1077
- Brunberg JA, Kanal E, Hirsch W, Van Thiel DH. Chronic acquired hepatic failure: MR imaging of the brain at 1.5 T. *AJNR Am J Neuroradiol* 1991;12:909-914

5. Kulisevsky J, Rusalleda J, Grau JM. MR imaging of acquired hepatocerebral degeneration (case report). *AJNR Am J Neuroradiol* 1991;12:527-528
6. Pujol A, Graus F, Peri J, Mercader JM, Rimola A. Hyperintensity in the globus pallidus on T1-weighted and inversion-recovery MRI: a possible marker of advanced liver disease. *Neurology* 1991;41:1526-1527
7. Kulisevsky J, Pujol J, Balanzo J, et al. Pallidal hyperintensity on magnetic resonance imaging in cirrhotic patients: clinical correlations. *Hepatology* 1992;16:1382-1388
8. Pujol A, Pujol J, Graus F, et al. Hyperintense globus pallidus on T1-weighted MRI in cirrhotic patients is associated with severity of liver failure. *Neurology* 1993;43:65-69
9. Inoue E, Hori S, Narumi Y, et al. Portal-systemic encephalopathy: presence of basal ganglia lesions with high signal intensity on MR images. *Radiology* 1991;179:551-555
10. Kulisevsky J, Pujol J, Junque C, Deus J, Balanzo J, Capdevila A. MRI of pallidal hyperintensity and brain atrophy in cirrhotic patients: two different MRI patterns of clinical deterioration? *Neurology* 1993;43:2570-2573
11. Salam-Adams M, Adams RD. Acquired hepatocerebral syndromes. In: Vinken PJ, Bruyn GW, Klawans HL, eds. *Handbook of Clinical Neurology*, vol 5(49): *Extrapyramidal Disorders*. Amsterdam: Elsevier, 1986:213-221
12. Mirowitz SA, Westrich TJ, Hirsch JD. Hyperintense basal ganglia on T1-weighted MR images in patients receiving parenteral nutrition. *Radiology* 1991;181:117-120
13. Grossman RI, Yousem DM. *Neuroradiology: The Requisites*. St Louis, Mo: Mosby, 1994:236
14. Vymazal J, Bulte JWM, Frank JA, Di Chiro G, Brooks RA. Frequency dependence of MR relaxation times, I: paramagnetic ions. *J Magn Reson Imaging* 1993;3:637-640
15. Vymazal J, Hajek M, Patronas N, Giedd JN, Bulte JWM, Brooks RA. The quantitative relation between T1- and T2-weighted MRI of normal gray matter and iron concentration. *J Magn Reson Imaging* 1995;5:554-560
16. Kucharczyk J, Kucharczyk W, Berry I, et al. Histochemical characterization and functional significance of the hyperintense signal on MR images of the posterior pituitary. *AJNR Am J Neuroradiol* 1988;9:1079-1083
17. Kucharczyk W, Lenkinski RE, Kucharczyk J, Henkelman RM. The effect of phospholipid vesicles on the NMR relaxation of water: an explanation for the MR appearance of the neurohypophysis? *AJNR Am J Neuroradiol* 1990;11:693-700
18. Hauser RA, Zesiewicz TA, Rosemurgy AS, Martinez C, Olanow CW. Manganese intoxication and chronic liver failure. *Ann Neurol* 1994;36:871-875
19. Newland CM, Ceckler TL, Kordower JH, Weiss B. Visualizing manganese in the primate basal ganglia with magnetic resonance imaging. *Exp Neurol* 1989;106:251-258