
Scanning Electron Microscopic Findings in a Basilar Tip Aneurysm Embolized with Guglielmi Detachable Coils

M. B. Horowitz, P. D. Purdy, D. Burns, and D. Bellotto

Summary: With the growing use of endovascular therapy for intracranial aneurysms, it is important that we understand at a cellular level the processes that lead to lesion obliteration. We present autopsy findings, including electron and light microscopic studies, of a basilar artery aneurysm that was successfully embolized with the Guglielmi detachable coil system 4 weeks before the patient died.

Index terms: Aneurysm, embolization; Interventional instruments, coils

The technique of coil embolization is well documented (1–4) and the concept of electrothrombosis has been summarized by Guglielmi et al in their early articles (1–3). The exact mechanism of aneurysmal obliteration and the process by which it is sealed off from the native circulation, however, are still poorly understood. Some histologic analysis of successfully thrombosed experimental aneurysms in animals is available (1). Nevertheless, despite deaths in 49 patients treated with Guglielmi detachable coils (GDCs) in the initial US multicenter study (5), there is a paucity of information concerning aneurysmal histology after coiling. We report a case of a successfully coiled basilar tip aneurysm that was studied with light microscopy and scanning electron microscopy 4 weeks after treatment.

Case Report

A 79-year-old woman was admitted to another institution with a subarachnoid hemorrhage that had a Hunt and Hess grade of 4 and a Fisher grade of 4. Computed tomography (CT) of the head showed blood in the fourth ventricle, the interpeduncular, ambient, quadrigeminal, carotid, and chiasmatic cisterns, and the sylvian fissures. Cerebral angiography revealed bilateral aneurysms of the posterior communicating artery and basilar tip. The pa-

tient was transferred to our institution for embolization of the presumably ruptured basilar aneurysm. Successful obliteration of the aneurysm with a 4 mm × 6 cm GDC-10 regular coil and a 3 mm × 4 cm GDC soft coil (Target Therapeutics, San Jose, Calif) was achieved without incident (Fig 1A and B). The two aneurysms of the posterior communicating artery could not be embolized. The left one was clipped immediately after the embolization procedure. Over the next 4 weeks the patient did not recover from the hemorrhage. Repeat angiograms never showed any foci of arterial vasospasm, although small-vessel spasm could not be ruled out and the patient was treated empirically with triple-H therapy (hypertension, hypervolemia, hemodilution). She died 4 weeks after treatment. An autopsy limited to the brain was performed with careful attention to the circle of Willis.

Autopsy Findings

Gross examination of the brain revealed massive subarachnoid hemorrhage in the posterior fossa and a smaller hemorrhage over the frontal orbital cortex. After the blood and circle of Willis were removed, three saccular aneurysms were apparent. One arose at the level of the right posterior communicating artery, another arose in association with the left posterior communicating artery, and the third was located at the right P1–P2 junction. A metal coil with thrombus was present in the lumen of this aneurysm. All vessels were patent. It was clear that the basilar aneurysm had not reruptured. The possibility of interim rupture of the right posterior communicating artery aneurysm could not be ruled out.

Scanning Electron Microscopic Procedure and Findings

The formaldehyde-fixed specimen was rinsed in phosphate-buffered saline followed by distilled water washes and a graduated dehydration in alcohol to 100%. The specimen was then moved into a Critical Point Dryer, model DCP-1 (Denton Vacuum, Inc, Moorstown, NJ). While the specimen was in the dryer, alcohol was replaced

Received March 18, 1996; accepted after revision July 29.

From the Departments of Radiology (M.B.H., P.D.P.), Neurosurgery (M.B.H., P.D.P.), and Pathology (D.Bu., D.Be.), University of Texas Southwestern Medical Center at Dallas.

Address reprint requests to Michael Horowitz, MD, Department of Neurosurgery and Radiology, University of Texas Southwestern Medical Center, 5323 Harry Hines Blvd, Dallas, TX 75235.

AJNR 18:688–690, Apr 1997 0195-6108/97/1804-0688 © American Society of Neuroradiology

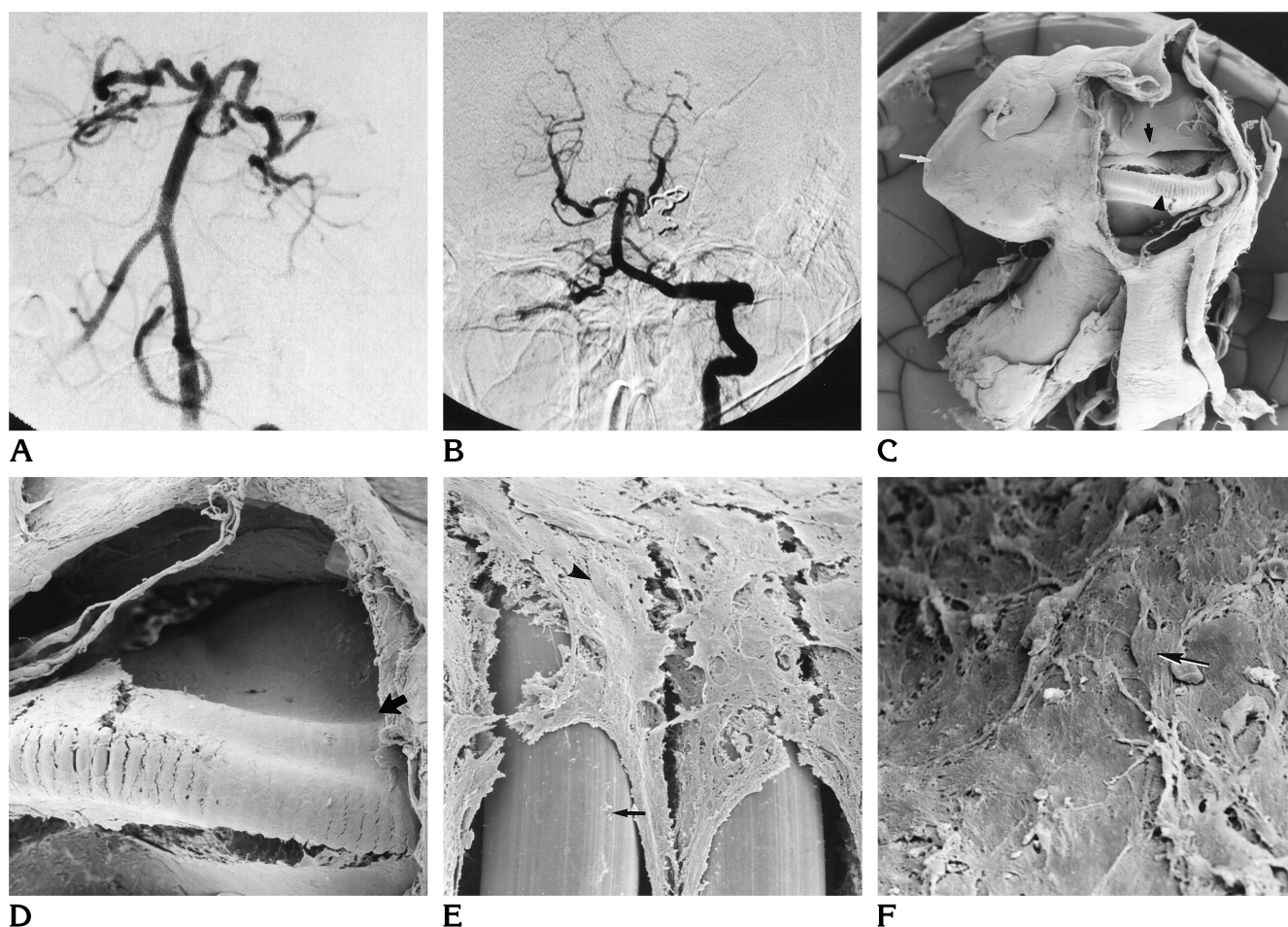


Fig 1. A 79-year-old woman with bilateral aneurysms of the posterior communicating artery and basilar tip.

A, Precoiling arteriogram of basilar tip aneurysm.

B, Postcoiling arteriogram of basilar tip aneurysm. (The aneurysm of the left communicating artery was clipped surgically.)

C, View of aneurysm (*white arrow*) from below through tear in posterior cerebral artery introduced at autopsy. *Small arrow* points to film that covers the aneurysmal neck and grows across the coils (*arrowhead*) (original magnification $\times 15$).

D, Higher magnification of coil with fibrinous film extending over the aneurysmal neck and the coil (*arrow*) (original magnification $\times 60$).

E, Coil (*arrow*) with overlying fibrin (original magnification $\times 650$).

F, Magnification of film with fibroblast (*arrow*) (original magnification $\times 1300$).

with liquid carbon dioxide, which was converted to carbon dioxide gas by increasing the temperature to 55°C at 1470 psi. The specimen was then placed in a Denton Vacuum Evaporator, model DV-502. Two hundred angstroms of gold and platinum were allowed to coat the specimen surface to provide stability and conductivity under the electron beams.

The specimen was viewed in a JEOL 840A scanning electron microscope (JEOL, Peabody, Mass) using the secondary electron imaging mode at a working distance of 25 mm and an accelerating voltage of 10kV. Images were documented with Polaroid Type 55 positive/negative 4×5 -in Instant Sheet Film (Polaroid Corp, Cambridge, Mass).

Magnification ranged from $\times 15$ to $\times 1300$. Evaluation of the coiled aneurysm in the posterior circulation revealed a thin layer of fibrin covering the coils (Fig 1C-F). Cellular

proliferation, either endothelial or fibroblastic, was noted at the edges of the aneurysm's neck.

Discussion

The GDC system for embolization of aneurysms has been available until recently only on an experimental basis to a select group of interventional centers. The technique and short-term results of electrothrombotic coil therapy for intracranial saccular aneurysms are well documented in published and unpublished reports (1-4) (F. Viñuela, Multicenter Study Group results, unpublished data). However, histologic data concerning aneurysmal appearance after

obliteration with GDCs appear to be limited to animal studies. Guglielmi et al (1) have documented the presence of well-organized thrombus within the aneurysmal fundus and neointima across the former aneurysmal neck. Such data appear to demonstrate that over time aneurysms become completely isolated from the native circulation. Graves et al (5) also demonstrated growth of endothelial cells across the luminal surface of the thrombus in experimental aneurysms. Geremia et al (6) have revealed similar findings in cases of experimental aneurysms treated with mesh stents placed across their ostia. Histopathologic analysis revealed neointima surrounding the stent wires as they traversed the experimental aneurysm's neck.

Our case appears to confirm in a human those findings reported in animal studies. Four weeks after coiling, the aneurysm's neck and fundus appeared to be functionally isolated from the parent vessel by a thin film of fibrin. The presence of either endothelial cells or fibroblasts encroaching upon the coils at the neck's periphery seems to suggest that neointimalization was beginning and that intima would ultimately line the vessel lumen and more definitively exclude the aneurysm from the native circulation. The human response to coiling of an aneurysm, therefore, may well parallel that seen

in animals. Covering of the neck with intima would afford one explanation for the long-term protection from rehemorrhage that aneurysmal coiling appears to provide. More postmortem data with more extended posttherapeutic survival, however, are needed if we are to understand fully the long- and short-term mechanisms and results of treatment in cases of coiled aneurysms.

References

1. Guglielmi G, Viñuela F, Sepetka I, Macellari V. Electrothrombosis of saccular aneurysms via endovascular approach, 1: electrochemical basis, technique, and experimental results. *J Neurosurg* 1991;75:1-7
2. Guglielmi G, Viñuela F, Dion J, Duckwiler G. Electrothrombosis of saccular aneurysms via endovascular approach, 2: preliminary clinical experience. *J Neurosurg* 1991;75:8-14
3. Guglielmi G, Viñuela F, Duckwiler G, et al. Endovascular treatment of posterior circulation aneurysms by electrothrombosis using electrically detachable coils. *J Neurosurg* 1992;77:515-524
4. Casasco AE, Aymard A, Gobin P, Houdart E. Selective endovascular treatment of 71 intracranial aneurysms with platinum coils. *J Neurosurg* 1993;79:3-10
5. Graves VB, Partington CR, Rufenacht DA, Rappe AH, Strother CM. Treatment of carotid aneurysms with platinum coils: an experimental study in dogs. *AJNR Am J Neuroradiol* 1990;11:249-252
6. Geremia G, Haklin M, Brennecke L. Embolization of experimentally created aneurysms with intravascular stent devices. *AJNR Am J Neuroradiol* 1994;15:1223-1231