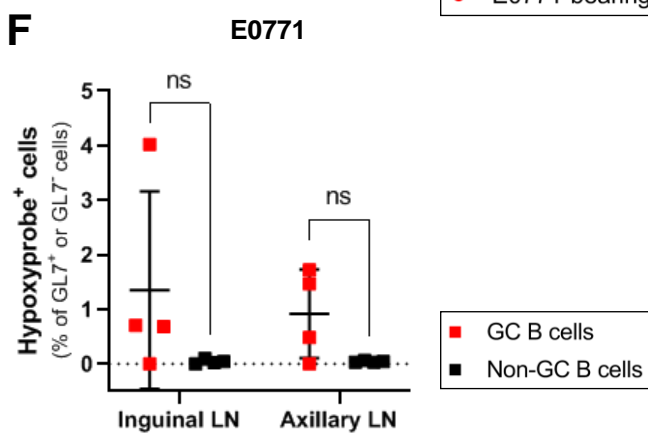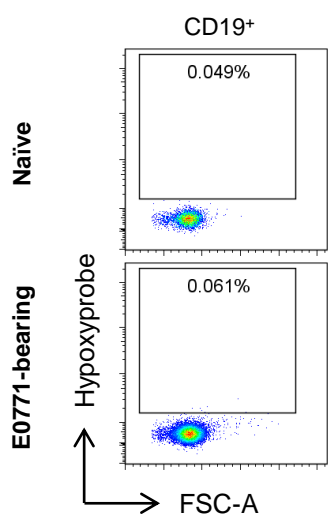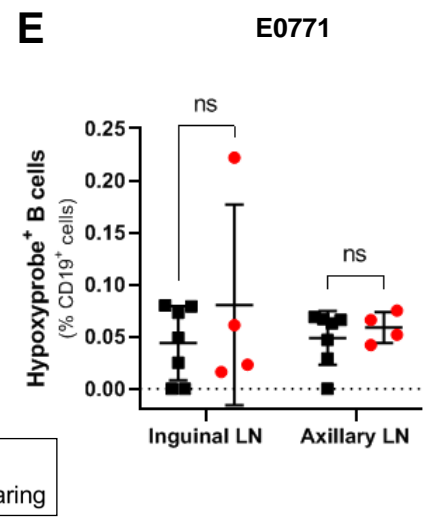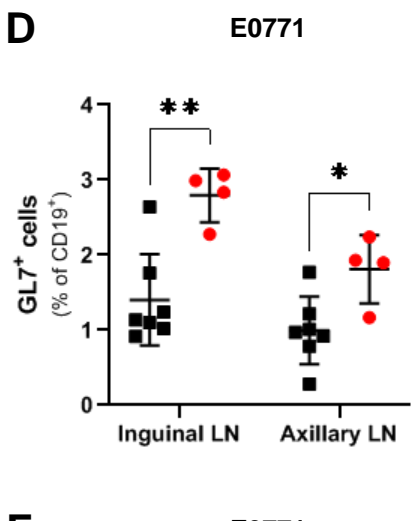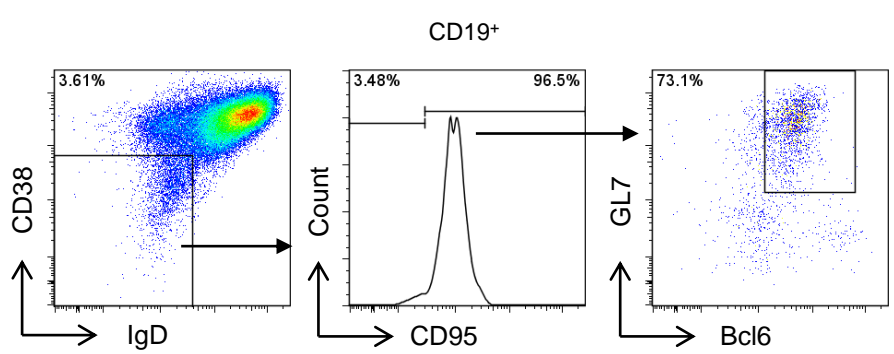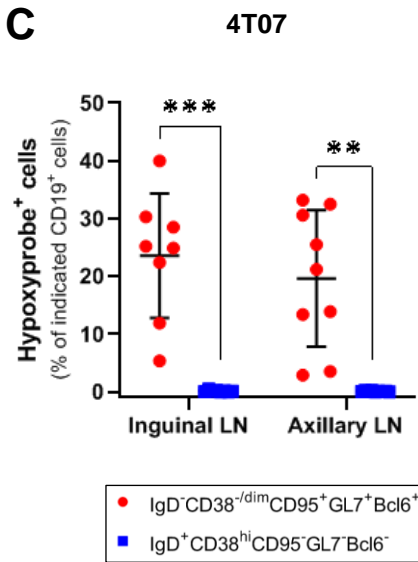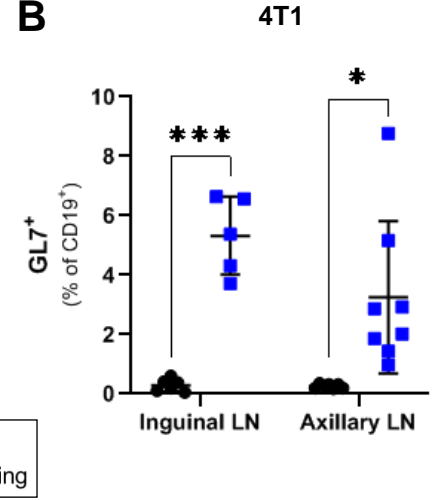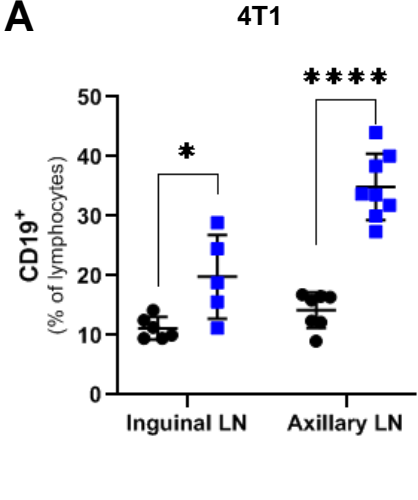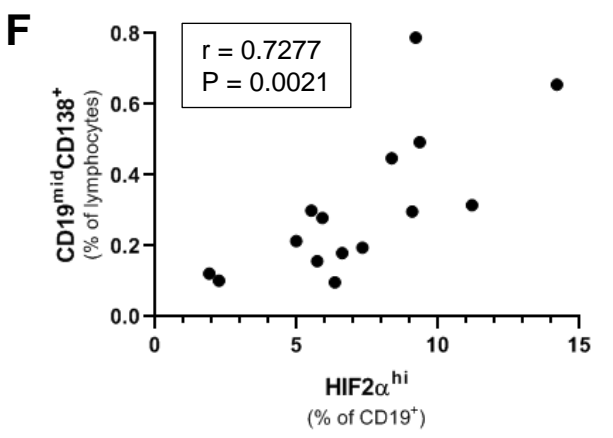
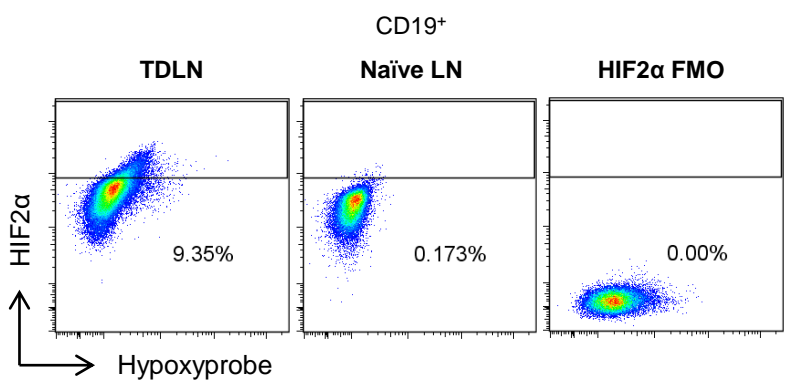
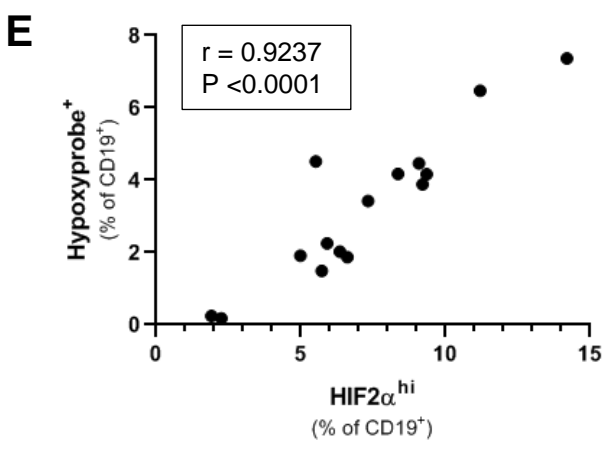
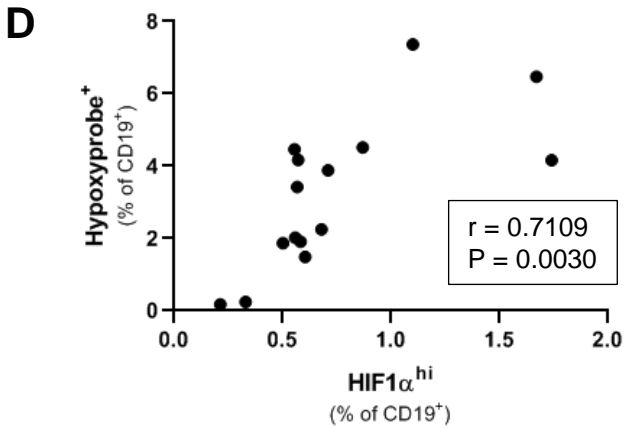
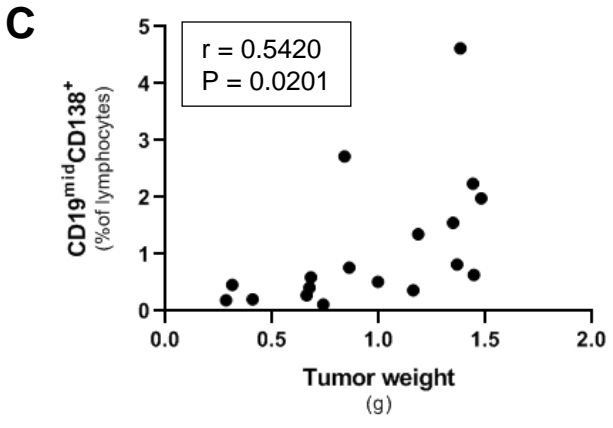
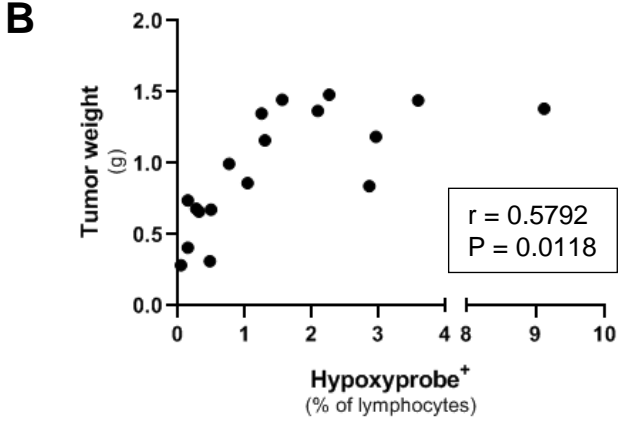
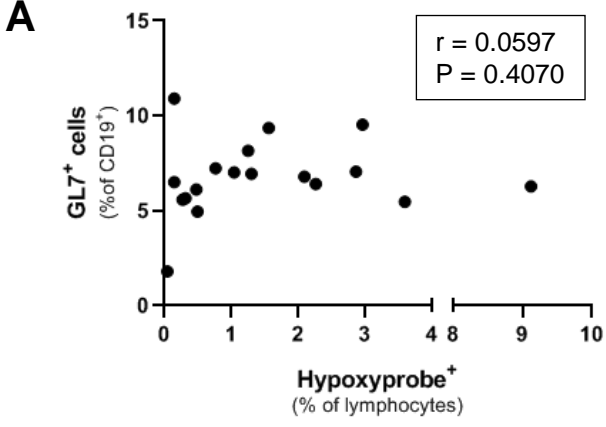


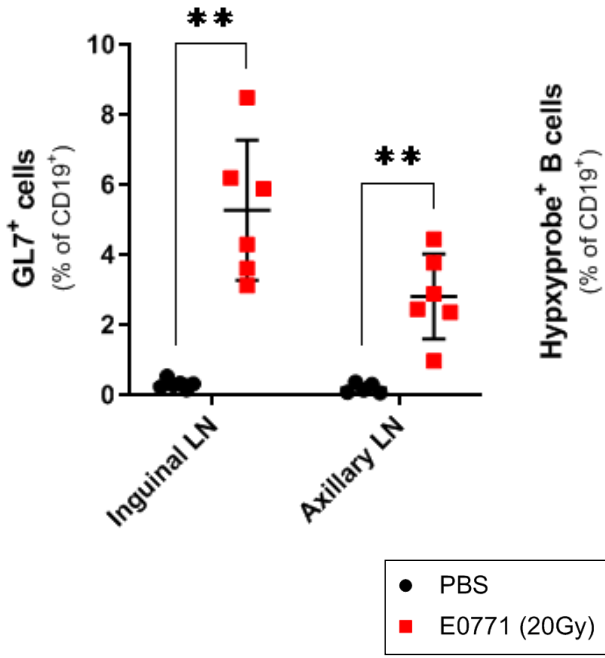
Supplemental Figure 1



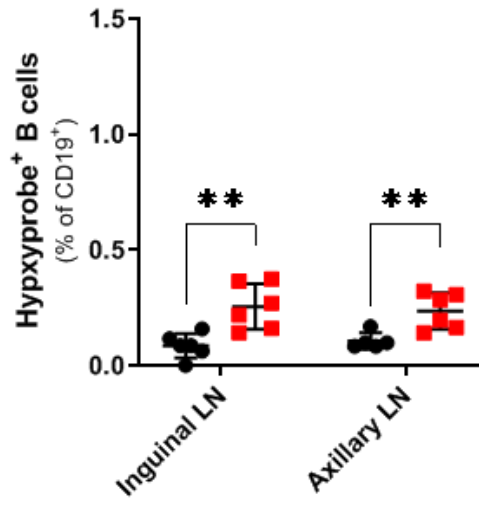
Supplemental Figure 2

**A**

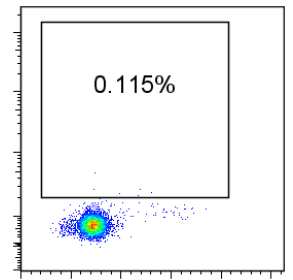
C57BL/6

**B**

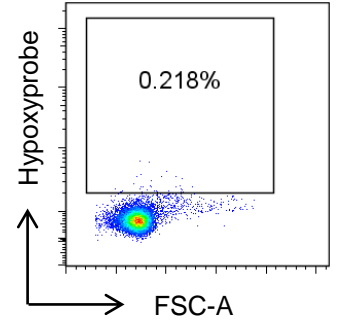
C57BL/6



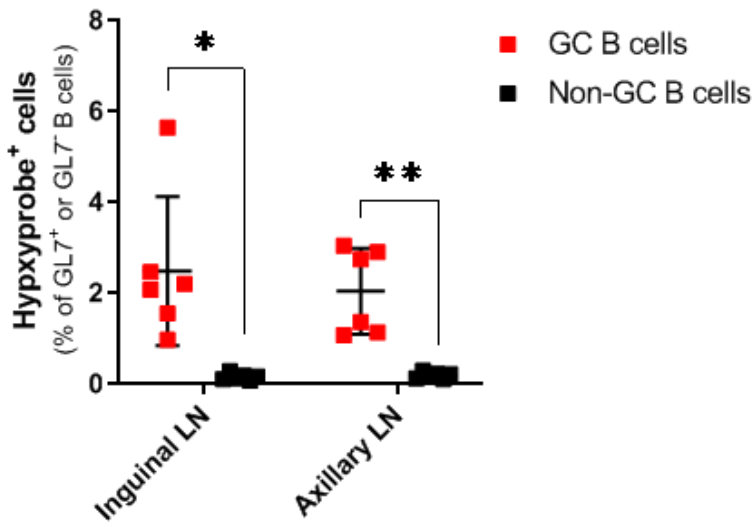
Naïve



E0771 (20Gy)

**C**

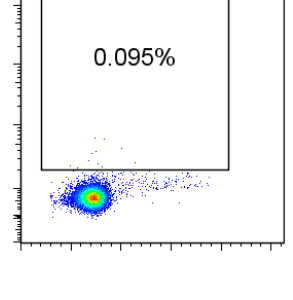
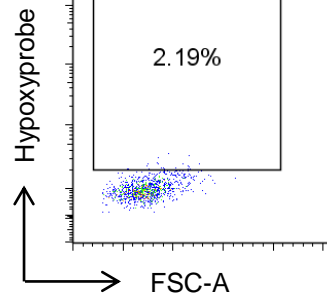
C57BL/6

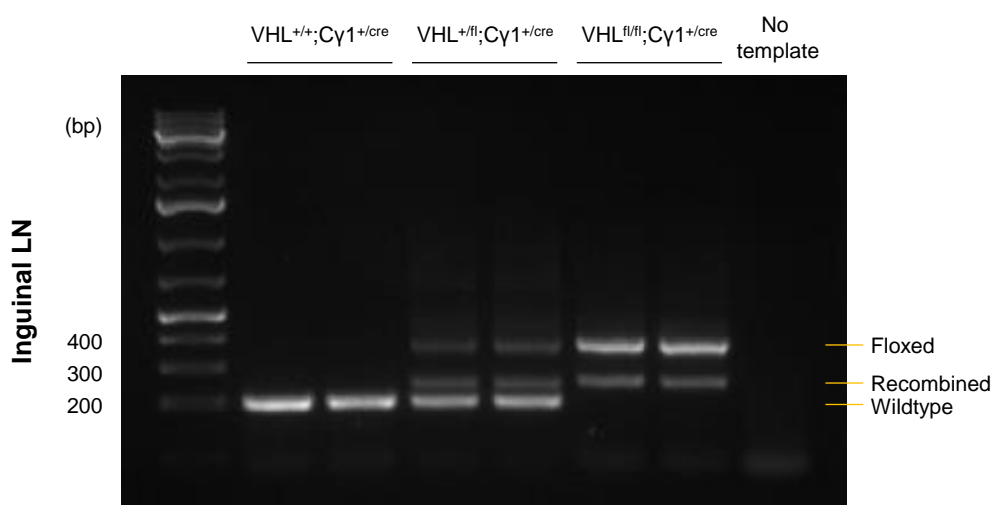
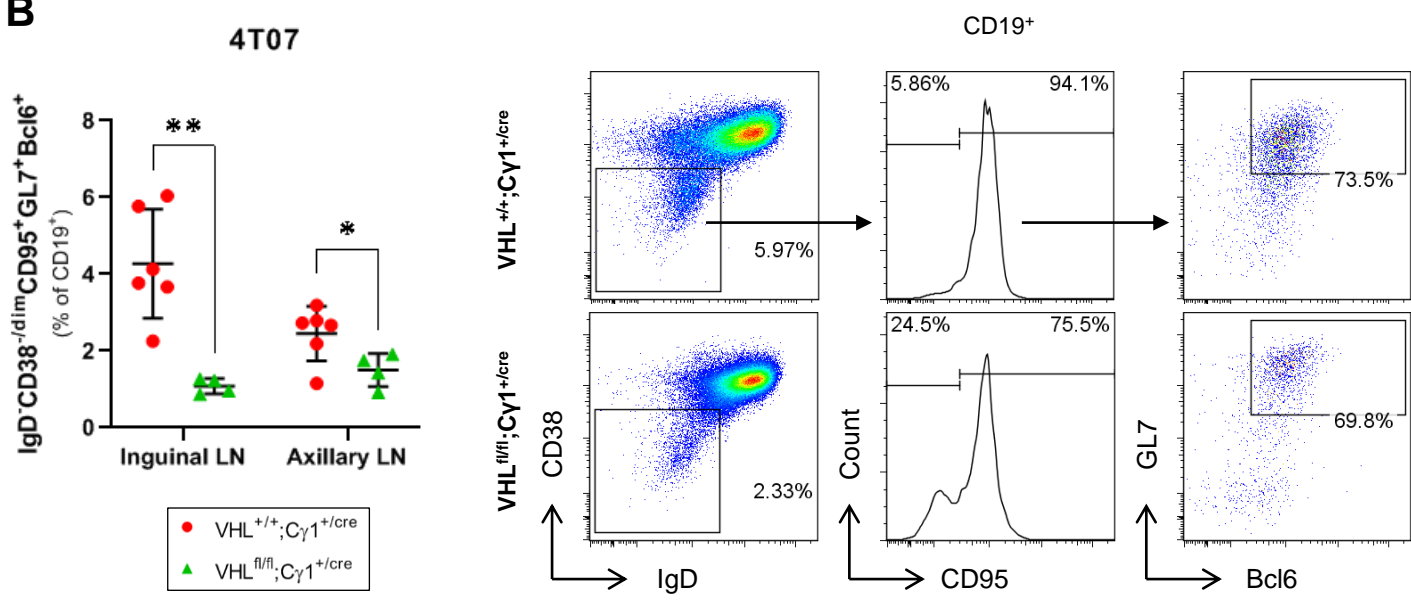
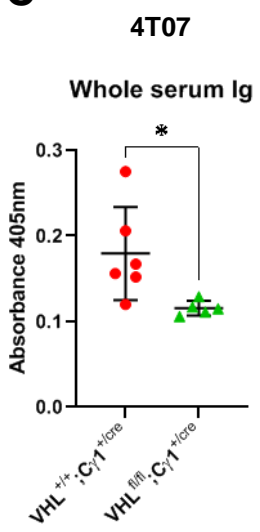
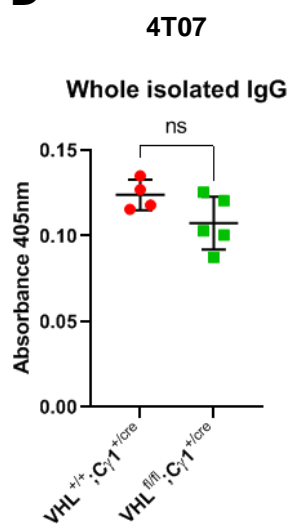
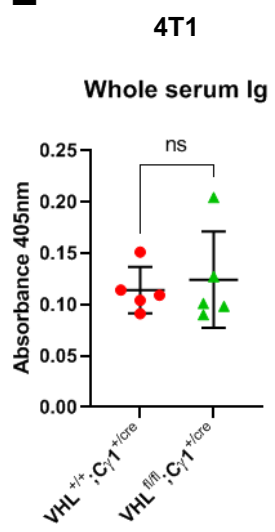


E0771 (20Gy)

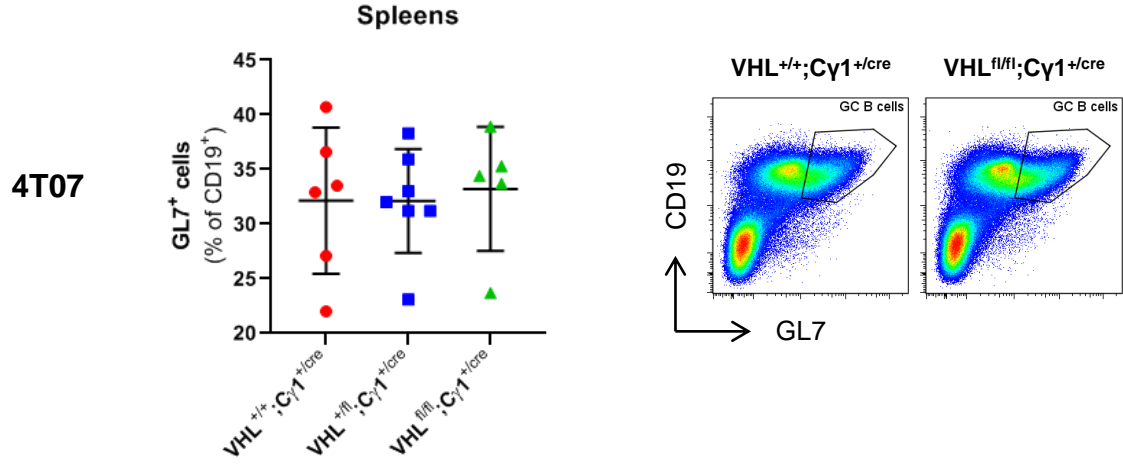
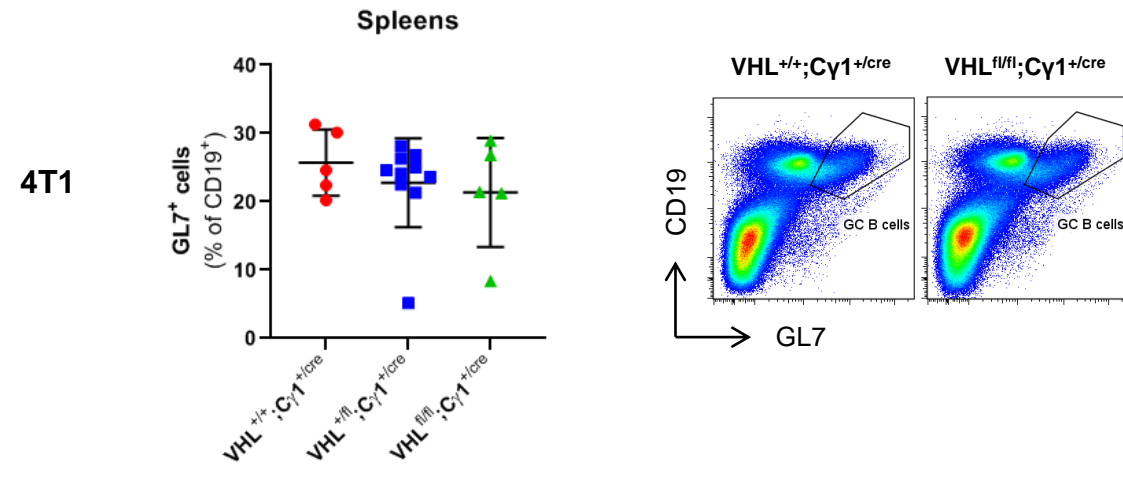
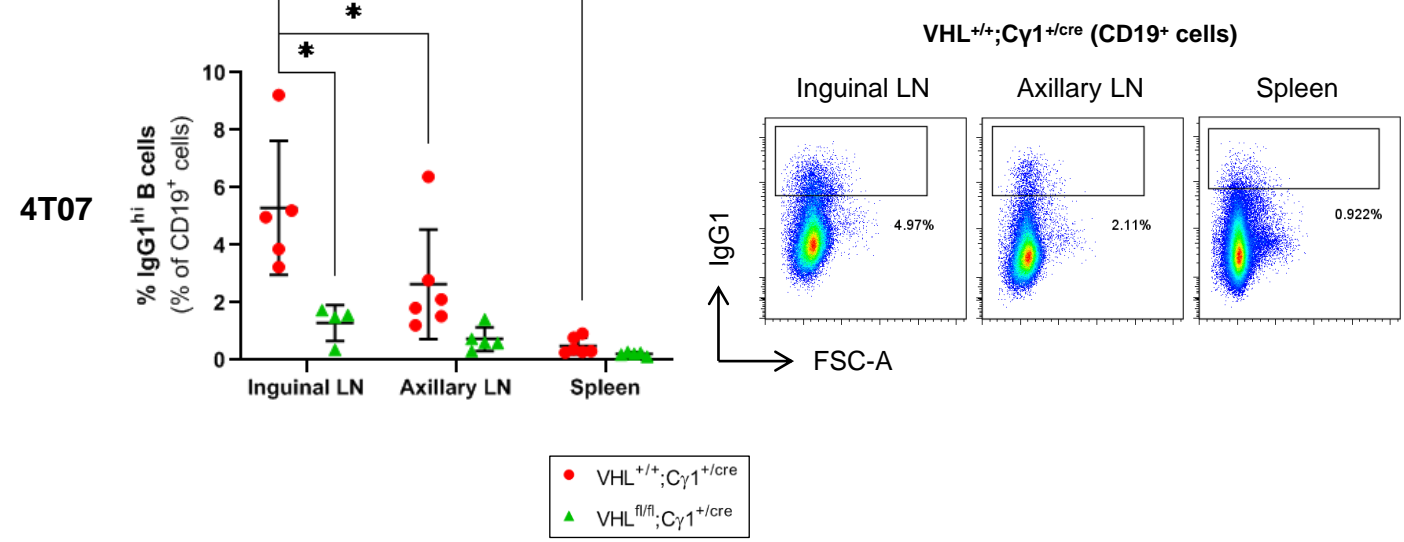
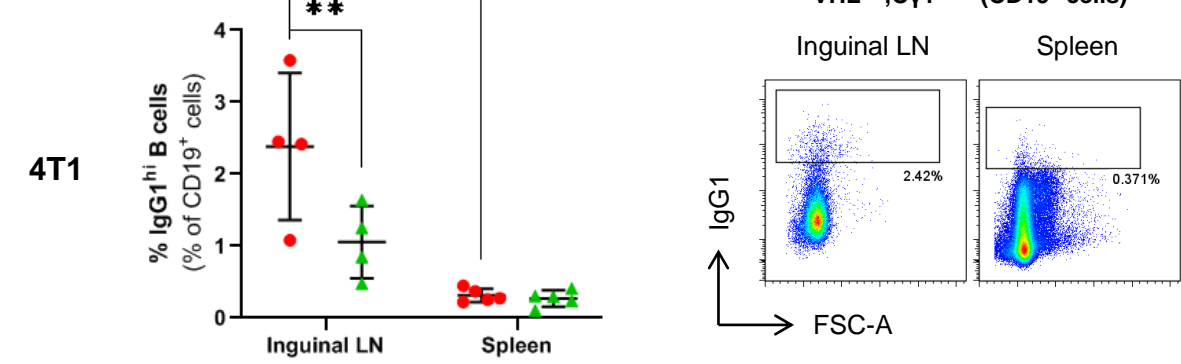
GC B cells

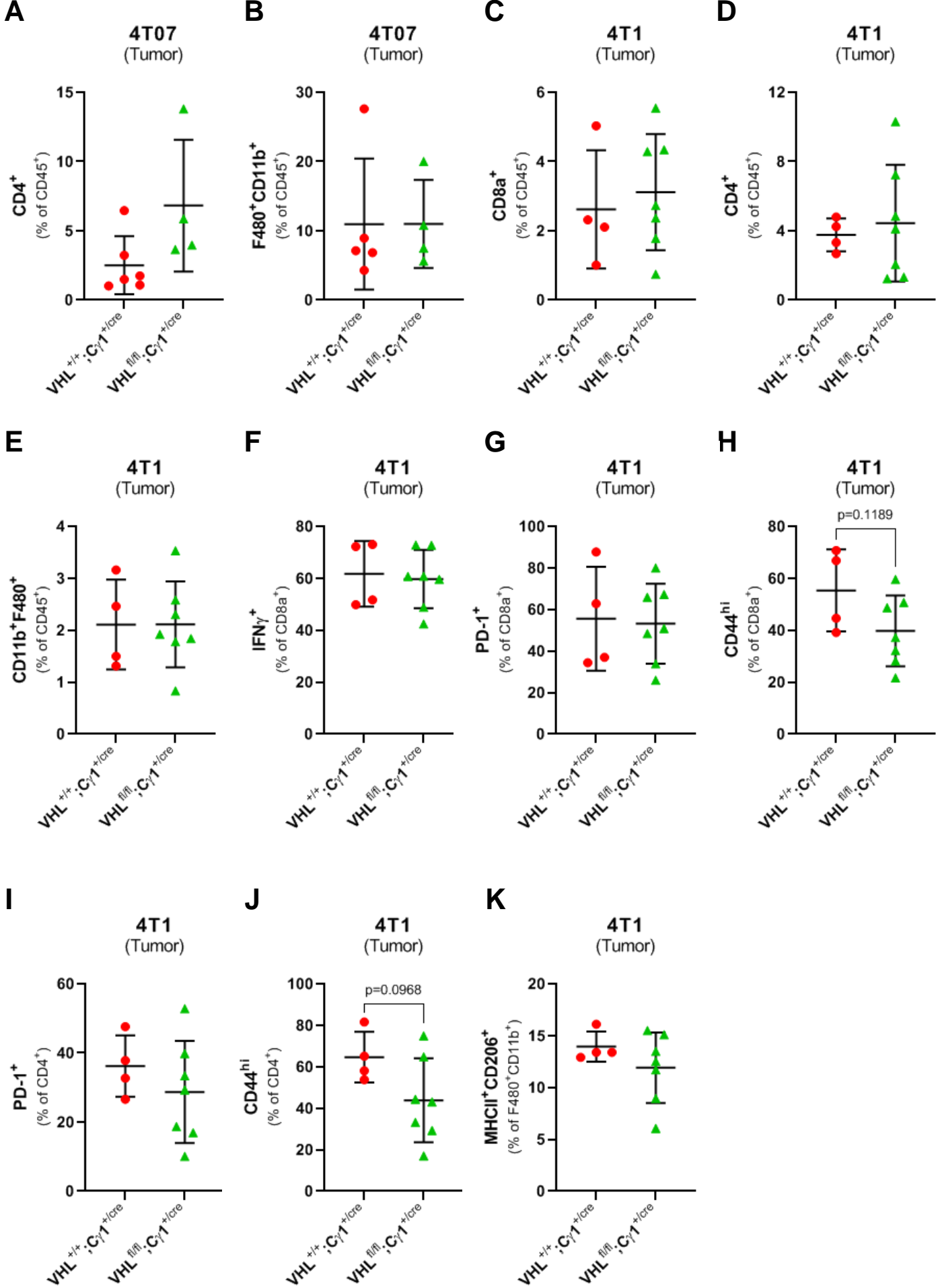
Non-GC B cells



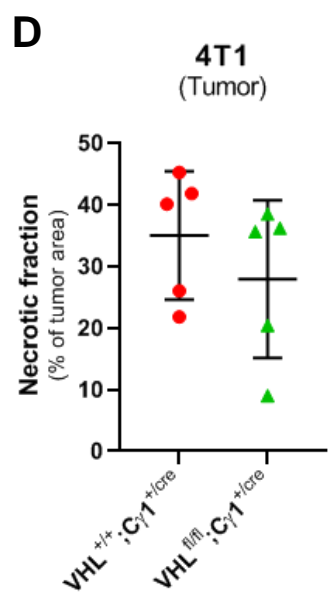
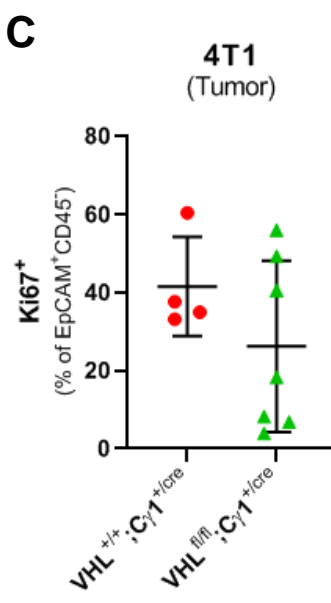
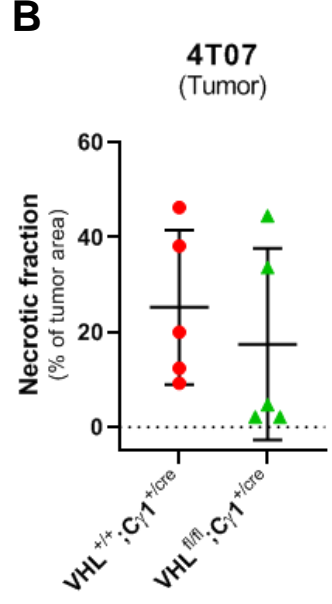
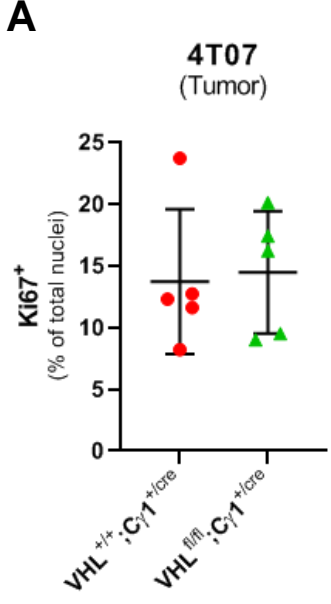
**A****B****C****D****E**

Supplemental Figure 4

**A****B****C****D****Supplemental Figure 5**



Supplemental Figure 6



Supplemental Figure 7

<i>Clinicopathological features</i>	<b>TNBC node negative n = 3 (%)</b>	<b>TNBC node positive n = 3 (%)</b>
<i>Age at diagnosis</i>		
< 50 years	1 (33)	2 (67)
≥ 50 years	2 (67)	1 (33)
<i>Histological description</i>		
▪ Infiltrating duct. carcinoma	3 (100)	3 (100)
<i>Histological grade</i>		
1	0	0
2	0	0
3	3 (100)	3 (100)
<i>Pathological tumor classification*</i>		
1C	3 (100)	1 (33)
2	0	1 (33)
3	0	1 (33)
<i>Pathological LN classification**</i>		
1A	0	1 (33)
2A	0	2 (67)
3A	0	0

\*1C: greatest dimension >1cm and ≤2cm; 2: greatest dimension >2cm and ≤5cm; 3: greatest dimension >5cm

\*\*1A: Metastasis in 1 to 3 axillary lymph nodes; 2A: Metastasis in 4 to 9 axillary lymph nodes, at least one deposit >2.0mm; 3A: Metastasis in 10 or more axillary lymph nodes (at least one tumor deposit >2.0mm); or metastases to the infraclavicular (level III) axillary lymph nodes