

Supplementary Material to “Spontaneous chromosomal instability in peripheral blood lymphocytes from two molecularly confirmed Italian patients with Hereditary Fibrosis Poikiloderma: insights into cancer predisposition”

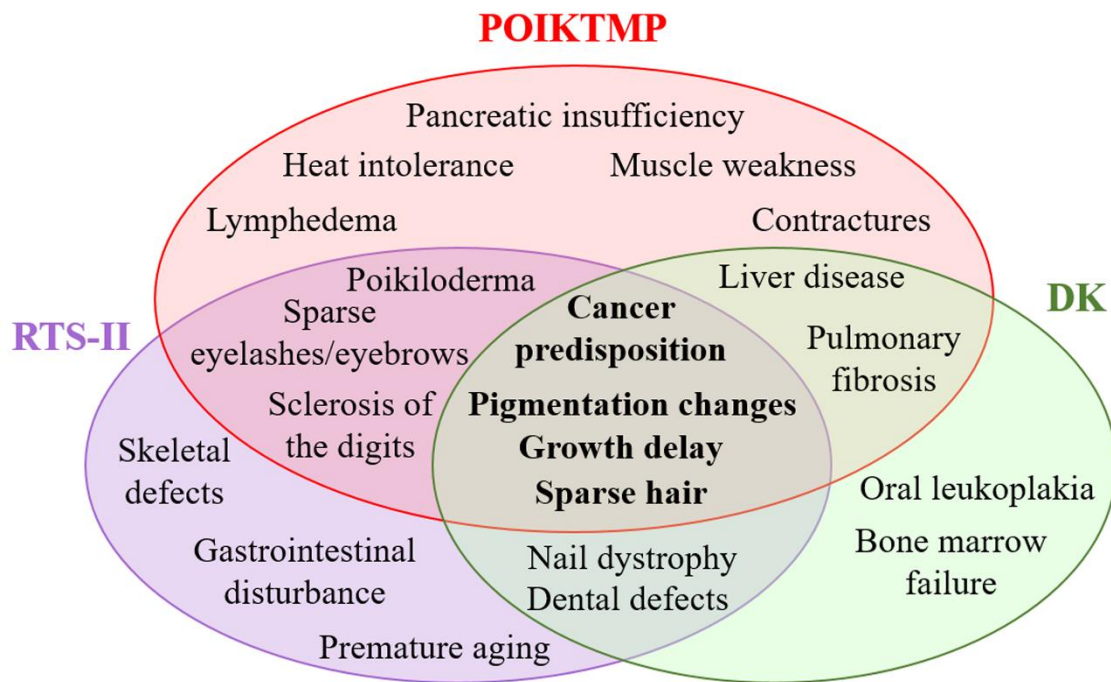


Figure S1 - Common and specific clinical features of POIKTMP, RTS-II, and DK.

Diagram illustrating the main clinical signs (black-boldd characters) shared by patients with the three syndromes having POIKTMP as reference. Distinctive features of each disorder are indicated in red for POIKTMP, violet for RTS-II, and green for DK.