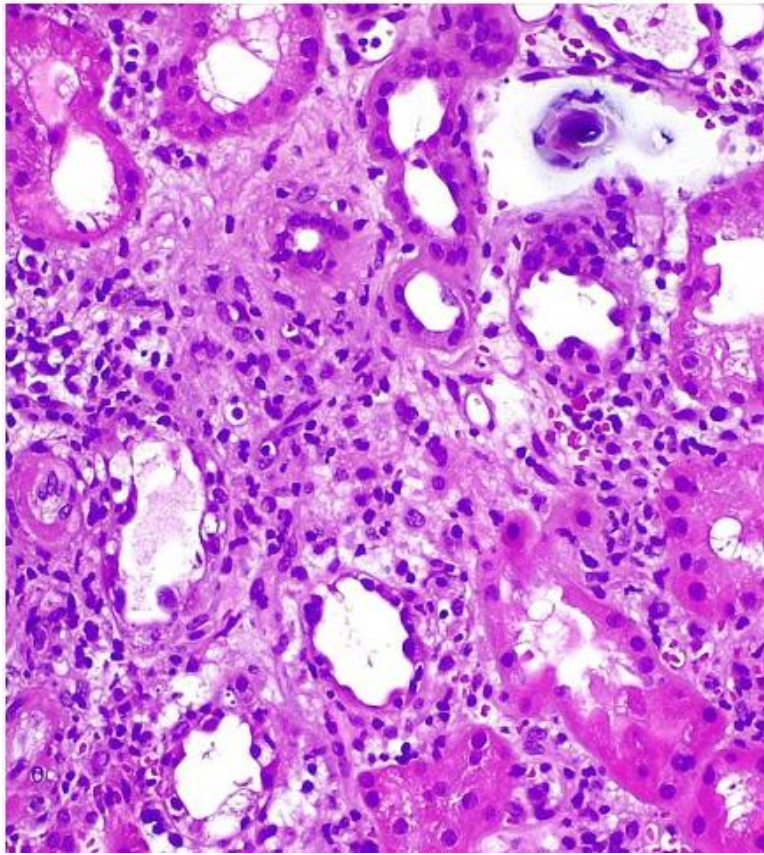


Figure S1. Hematoxylin and eosin stain of kidney tissue. BANFF score was compatible with borderline changes (g0, i1-2, ti1-2, i-IFTA1-2, t1, v 0, ptc0, ah3, aah3, cg0, ci0, ct0, cv0, mm0).

A



B

