

# Contrast-Enhanced MR Imaging of Tolosa-Hunt Syndrome: A Case Report

S. P. Desai,<sup>1</sup> J. Carter, and J. R. Jinkins

Tolosa-Hunt syndrome is characterized by repeated episodes of boring retroperiorbital pain, which is separated by days or months and is accompanied by variable deficits of the third through sixth cranial nerves. It is of unknown origin, responds promptly to corticosteroids, and remains primarily a diagnosis of exclusion [1, 2]. This article details the angiographic and MR features of a case of Tolosa-Hunt syndrome.

## Case Report

A 33-year-old woman began experiencing left frontal and orbital headaches in early December 1988. One month later she had the onset of diplopia, followed 2 days later by ptosis on the left side. Over the next several days she developed subjective numbness of the left face, nausea, vomiting, and neck pain with stiffness.

Examination at the time of admission was remarkable only for abnormalities of ocular motility involving the left eye. There was ptosis, no abduction, markedly impaired upgaze, and moderately impaired abduction and downgaze. There was no torsion evident on attempted downgaze. No objective sensory deficit could be demonstrated on the left face. Visual function and fundus examination was entirely normal bilaterally, and there was no proptosis.

All pertinent laboratory studies were normal except for an elevated erythrocyte sedimentation rate of 33 mm/hr. Lumbar puncture revealed a normal opening pressure, glucose, protein, cell count, and differential.

On admission, multiplanar MR imaging with IV contrast administration demonstrated a plaque-like area of enhancement contiguous with the left cavernous sinus surrounding the left internal carotid flow void (Figs. 1A–1C). The region of abnormality was isointense with gray matter on short TR/TE acquisitions, and iso- to slightly hyperintense on long TR/TE studies. No orbital extension could be identified. A cerebral angiogram (Fig. 1D) revealed focal narrowing of the cavernous segment of the left internal carotid artery. No tumor vessels or angiographic tumor blush could be identified.

A diagnosis of presumed Tolosa-Hunt syndrome was made, and the patient was treated with oral prednisone, 60 mg daily. Within 24 hr her pain had resolved. She was discharged on 60 mg prednisone daily, and the dose was gradually decreased over 4 weeks. An MR study, performed 5 weeks after initiating steroids, showed subtotal resolution of the parasellar enhancing abnormality (Fig. 1E).

Subsequently, there has been only irregular clinical follow-up;

however, the patient's ocular motility reverted to and has remained normal since her last examination in April 1989.

## Discussion

The number of reported cases of Tolosa-Hunt syndrome has been increasing in recent years since the publication of the original reports in 1954 and 1961 [1–10]. The symptom complex is characterized by recurrent, unilateral, painful ophthalmoplegia, which characteristically responds dramatically to systemic steroid therapy. However, spontaneous remission is known to occur. Tolosa-Hunt syndrome is believed to be caused by low-grade idiopathic granulomatous inflammation of the tissues within and surrounding the cavernous sinus and superior orbital fissure, sometimes extending into the orbital apex. Carotid angiography characteristically shows focal narrowing of the cavernous portion of the internal carotid artery.

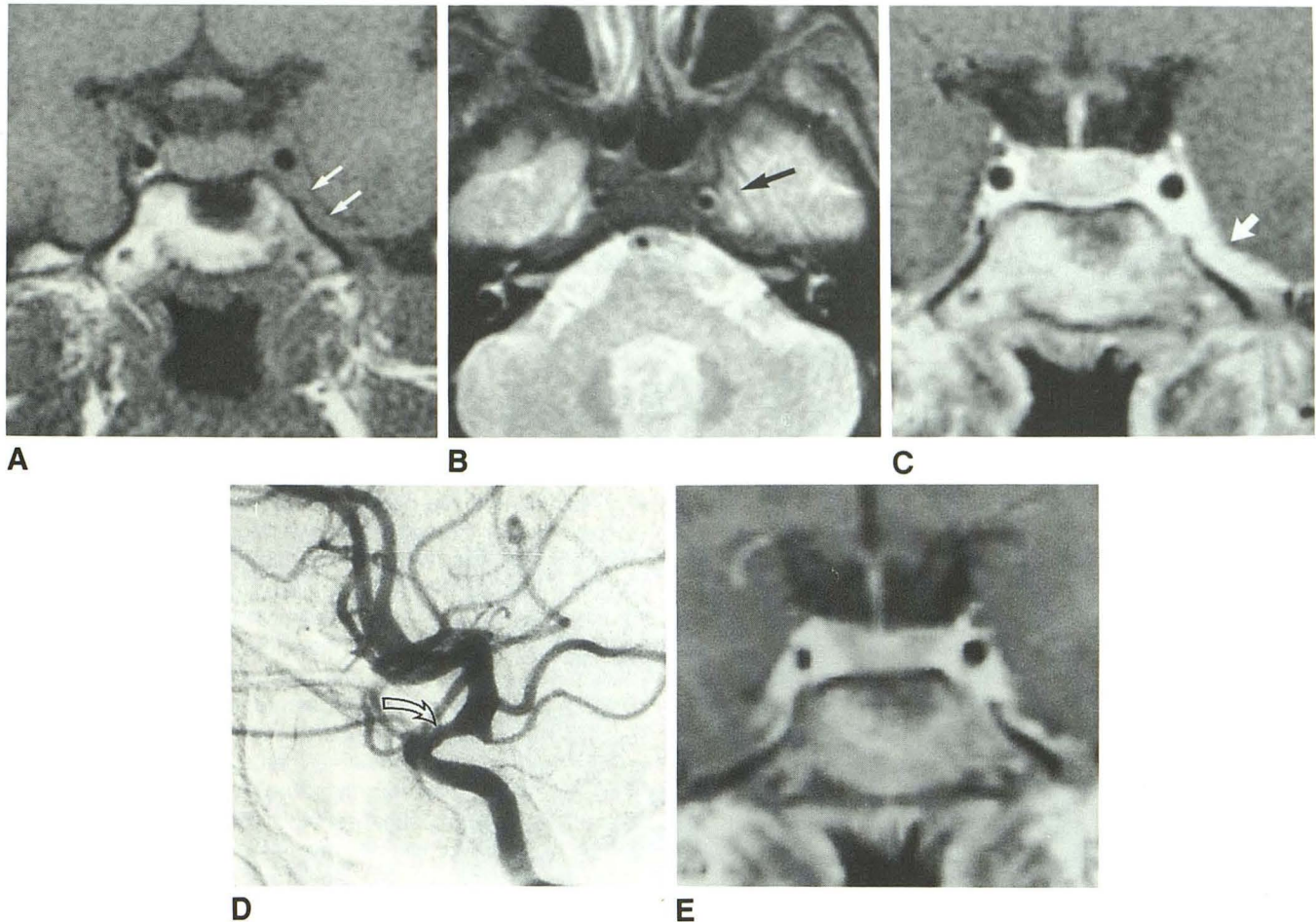
A recent report [11] concerning the appearance of the Tolosa-Hunt syndrome on noncontrast MR included the following characteristics: (1) signal changes in the mass itself as compared with surrounding normal structures (i.e., isointense with muscle on short TR/TE scans, and isointense with fat on long TR/TE images); (2) enlargement of the affected cavernous sinus; and (3) extension of the pathologic process into the orbital apex in a large percentage of cases. It is important to note that a small number of patients in this same series had a normal MR examination.

Certain other conditions should be considered in the differential diagnosis of Tolosa-Hunt syndrome, including intracavernous aneurysm of the internal carotid artery, cavernous sinus thrombosis, invasive tumors from the paranasal sinuses and sella turcica, neoplasia arising from structures within the cavernous sinus and overlying meninges, and nonspecific inflammatory involvement of cranial nerves [1, 11]. The latter encompasses infectious diseases, such as fungal or bacterial conditions as well as inflammation of unknown origin (i.e., sarcoid).

The present case suggests that the findings represent the

Received April 12, 1990; revision requested July 23, 1990; revision received August 21, 1990; accepted August 28, 1990.

<sup>1</sup> All authors: Department of Radiology, The University of Texas Health Science Center, 7703 Floyd Curl Dr., San Antonio, TX 78284. Address reprint requests to J. R. Jinkins.



**Fig. 1.**—33-year-old woman with Tolosa-Hunt syndrome.  
**A,** Precontrast coronal T1-weighted image shows left parasellar mass isointense with gray matter and inseparable from cavernous sinus (arrows).  
**B,** T2-weighted axial image shows slightly prominent left cavernous sinus as compared with right, but with no difference in intensity (arrow).  
**C,** Contrast-enhanced T1-weighted coronal image reveals plaque-like area of enhancement surrounding carotid flow void and extending onto floor of middle cranial fossa (arrow).  
**D,** Left carotid angiogram shows focal narrowing of cavernous segment of internal carotid artery (arrow).  
**E,** Repeat contrast-enhanced coronal T1-weighted study 5 weeks after initiation of steroid therapy shows subtotal resolution of parasellar enhancing tissue shown in A.

MR equivalent of the clinical manifestations of the Tolosa-Hunt syndrome, although confirmation must await additional observations. However, in any individual case, given the large differential possibilities listed above, it becomes imperative to confirm the MR diagnosis with angiography and follow-up MR to prove resolution in order to avoid an erroneous diagnosis of this syndrome in the face of an actual neoplastic, vascular, or more specific inflammatory lesion [4–6].

#### REFERENCES

- Hoes MJA, Bruyn GW, Vielvoe GJ. The Tolosa-Hunt syndrome: literature review: seven new cases and a hypothesis. *Cephalalgia* 1981;4:181–194
- Hunt WE, Brightman RP. The Tolosa-Hunt syndrome: a problem in differential diagnosis. *Acta Neurochir* 1988;42:248–252
- Tolosa EJ. Periarteritic lesions of carotid siphon with clinical features of carotid infraclinoid aneurysm. *J Neurol Neurosurg Psychiatry* 1954;17:300–302
- Hunt WE, Meagher JN, Lefever HE, Zeman W. Painful ophthalmoplegia: its relation to indolent inflammation of the cavernous sinus. *Neurology* 1961;11:56–62
- Sondheimer FK, Knapp J. Angiographic findings in the Tolosa-Hunt syndrome: painful ophthalmoplegia. *Radiology* 1973;106:105–112
- Dorman TL, Espir, MLE, Gale EAM, Tattersall RB, Worthington BS. Remittent painful ophthalmoplegia: the Tolosa-Hunt syndrome? *J Neurol Neurosurg Psychiatry* 1979;42:270–275
- Neigel JM, Rootman J, Robinson RG, Durity FA, Nugent RA. The Tolosa-Hunt syndrome: computed tomographic changes and reversal after steroid therapy. *Can J Ophthalmol* 1986;21:287–290
- Kwan ESK, Wolpert SM, Hedges TR III, Laucella M. Tolosa-Hunt syndrome revisited: not necessarily a diagnosis of exclusion. *AJNR* 1987;8:1067–1072, *AJR* 1988;150:413–418
- Thomas DJB, Charlesworth MC, Afshar F, Galton DJ. Computerised axial tomography and magnetic resonance scanning in the Tolosa-Hunt syndrome. *Br J Ophthalmol* 1988;72:299–302
- Inzitari D, Sita D, Marconi GP, Barontini F. The Tolosa-Hunt syndrome: further clinical and pathogenetic considerations based on the study of eight cases. *J Neurol* 1981;224:221–228
- Yousem DM, Atlas SW, Grossman RI, Sergott RC, Savino PJ, Bosley TM. MR imaging of Tolosa-Hunt syndrome. *AJNR* 1989;10:1181–1184