

# MR Imaging of Spinal Cord Arteriovenous Malformations at 0.5 T: Study of 34 Cases

D. Dormont<sup>1</sup>  
 F. Gelbert<sup>2</sup>  
 E. Assouline<sup>2</sup>  
 D. Reizine<sup>2</sup>  
 A. Helias<sup>2</sup>  
 M. C. Riche<sup>2</sup>  
 J. Chiras<sup>1</sup>  
 J. Bories<sup>1</sup>  
 J. J. Merland<sup>2</sup>

Thirty-four patients with angiographically proved arteriovenous malformations of the spinal cord were studied between May 1986 and July 1987. Examinations were performed on a CGR 5000 Magniscan 0.5-T scanner with a surface coil in all cases, and multislices in both T1- and T2-weighted sequences were obtained in sagittal and axial planes. The results showed that MR can accurately diagnose all cases of intramedullary arteriovenous malformations, since transverse images were able to precisely locate the nidus within the spinal cord. Other types of spinal cord arteriovenous malformations were also studied (perimedullary fistulae and dural arteriovenous fistula), and the findings confirmed the value of MR in the characterization of these lesions as well.

The routine diagnostic protocol for vascular malformations of the spinal cord includes myelographic and angiographic investigations. Only a few reports [1-4] based on a small number of cases have been published concerning the MR imaging aspects of spinal cord arteriovenous malformations (AVMs).

We report on 34 cases of angiographically proved AVMs studied with MR. The purpose of our study was to establish the value of MR in the diagnosis and characterization of these lesions.

## Materials and Methods

MR imaging was performed on 34 patients with proved spinal cord AVMs. Angiography was done during the same week in all cases and the results of the two diagnostic methods were correlated.

MR was performed before embolization in 20 cases of intramedullary AVMs (10 women and 10 men; mean age, 25 years); four cases of extramedullary AVMs (three women and one man; mean age, 30 years); three cases of perimedullary fistula (two women and one man; mean age, 40 years); and seven cases of dural arteriovenous fistula (AVF) with perimedullary drainage (all men; mean age, 58 years). In five cases MR was also repeated after embolization. These included three cases of AVMs 48 hr after embolization and two cases of dural AVFs 3 months after embolization.

All studies were performed between May 1986 and July 1987 on a 0.5-T CGR 5000 Magniscan imaging unit. A surface coil was used in every case. A multislice program was available, and both T1- and T2-weighted images were obtained with spin-echo sequences (TR = 400-2000, TE = 28-60). An image acquisition matrix 256 × 256 was used. In our routine examination no gated sequence was performed. Slice thickness varied from 6 to 8 mm contiguous in sagittal and axial planes. Average duration of examination (including sagittal T1-weighted images and transverse T1- and T2-weighted images) was 60 min.

## Results

### Intramedullary AVMs

Intramedullary AVMs are frequently revealed by a subarachnoidal hemorrhage in young patients. These lesions are always fed by the anterior spinal artery. In several

Received November 23, 1987; accepted after revision March 13, 1988.

<sup>1</sup> Service de Neuroradiologie, Hopital de la Salpêtrière, 47 bd de l'Hopital, 75013, Paris, France.

<sup>2</sup> Service de Neuroradiologie, Hopital Lariboisière, 2 rue Ambroise Paré, 75010, Paris, France. Address reprint requests to F. Gelbert.

AJNR 9:833-838, September/October 1988

0195-6108/88/0905-0833

© American Society of Neuroradiology



reported cases, the posterior spinal arteries participated in forming the malformation [5-7].

MR was performed in 20 patients with intramedullary AVM. In all, T1-weighted sagittal sequences showed an intramedullary low signal associated with a focal enlargement. This abnormal portion of the spinal cord also contained areas of serpiginous vascular flow void (Fig. 1). These abnormalities characterized the nidus. The nidus was demonstrated in all cases, but it was seen better on axial images, which showed its intramedullary location with some anatomic detail: it appeared as an area of low signal intensity surrounded by normal cord tissue. Vascular signal void corresponding to arterial feeders and venous drainage surrounded the nidus and was seen over and under the nidus in the subarachnoid space (Fig. 1C). T2-weighted sequences in the axial plane were obtained in all cases. Vascular signal voids were better delineated, because of the surrounding CSF signal hyperintensity. Sometimes, the nidus presented with a heterogeneous signal intensity (Fig. 2). In some cases high signal was observed in the spinal cord over and under the nidus in T2-weighted sequences.

Some special findings are worth pointing out.

1. Postembolization examination: MR was repeated in three cases 48 hr after embolization and no significant change was detected.

2. Five patients displayed a Cobb syndrome with a vertebral angioma (Fig. 3). According to Riche et al. [7], a Cobb syndrome is defined as a metameric angiomatosis associated with intramedullary AVM and/or epidural AVM and/or vertebral and/or superficial angiomas. On T1-weighted images the vertebra involved by the angioma showed a low signal intensity.

3. Three patients had complications closely related to the intramedullary AVM. In one case, hemorrhage revealed the AVM, and a sagittal T1-weighted image clearly demonstrated the high signal of a subacute subdural hematoma (Fig. 4).

4. Atrophy of the spinal cord (Fig. 5) was noticed in one case. Major scoliosis and syrinx cavity were observed in another patient.

#### Extramedullary AVMs

Extramedullary AVMs are a very rare type of spinal cord AVM [8]. Clinical data are similar to those that characterize intramedullary AVMs. In four cases, the extramedullary AVM was diagnosed by angiography (angiotomomyelographic examination). In two of these cases MR disclosed a previous erroneous angiographic diagnosis of extramedullary lesion by showing both intra- and extramedullary angiomatous components. Sagittal T1-weighted images clearly demonstrated a localized enlargement of the spinal cord with a central low signal corresponding to the intramedullary portion of the nidus. The extramedullary portion of the nidus was also well visualized in axial T1- and T2-weighted sequences (Fig. 6).

In the two other cases, the malformation was strictly extramedullary. On sagittal T1-weighted images, it was not possible to distinguish between low signal intensity due to CSF and flow-void phenomenon due to extramedullary vessels. The spinal cord was of normal size and appearance and demonstrated a normal signal at the level of the angiographic abnormalities. Extramedullary vessels were only identified on transverse T1- and T2-weighted images. For those two patients, the normal aspect of the spinal cord confirmed the diagnosis of strictly extramedullary AVM.

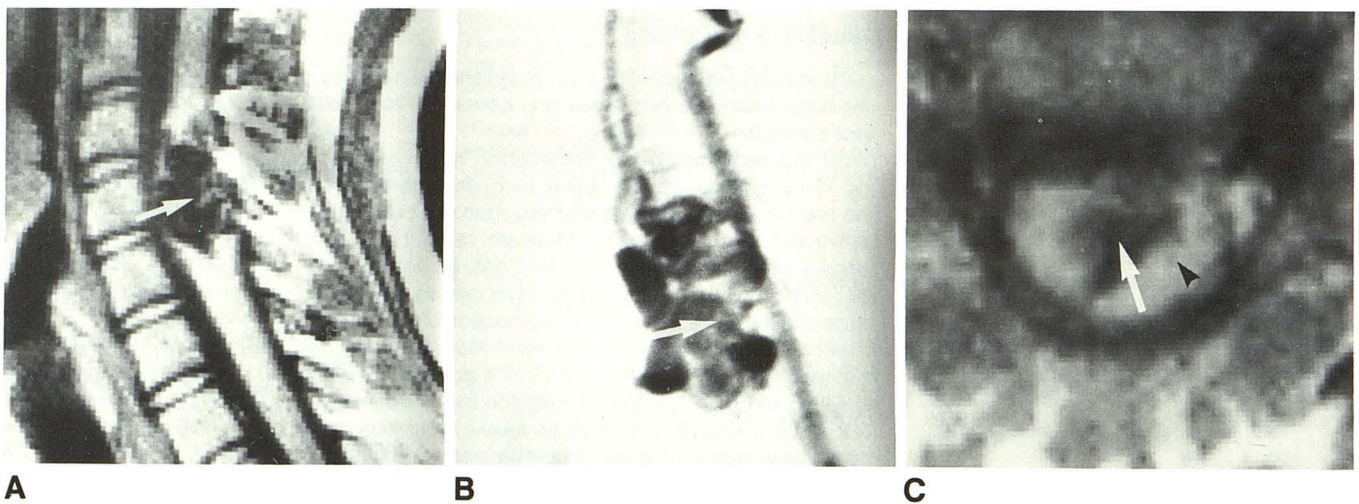


Fig. 1.—21-year-old woman with cervical intramedullary arteriovenous malformation.

A, Sagittal T1-weighted (400/28) image shows characteristic MR findings of intramedullary vascular malformation: local enlargement and signal void are seen within spinal cord (arrow).

B, Corresponding selective vertebral angiogram: note the nidus (arrow).

C, Transverse T1-weighted (400/28) image provides accurate information about intramedullary site of nidus. It appears as an area of low signal intensity (arrow) surrounded by normal spinal cord signal (arrowhead).



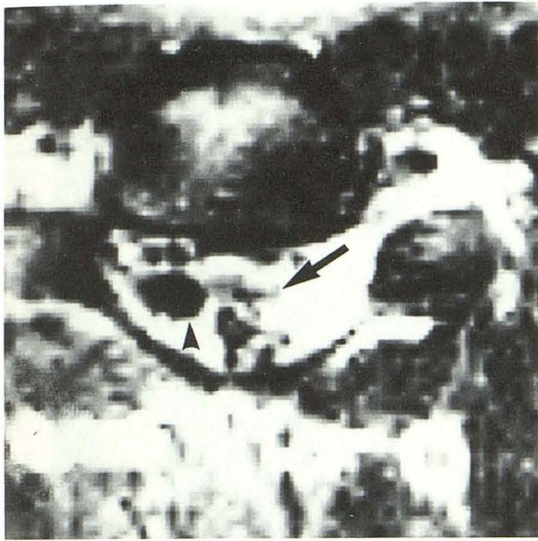

Fig. 2.—Cervical intramedullary AVM in a 30-year-old man. Transverse T2-weighted (2000/120) image. Nidus within spinal cord appears as an area of low intensity with signal void images (arrow) and extramedullary vessels outlined well by high-intensity CSF (arrowhead).

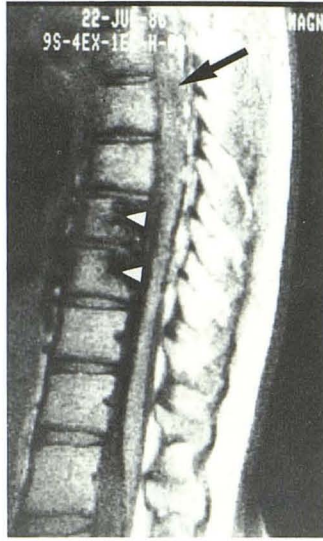

Fig. 3.—Cobb syndrome with thoracic (T7) intramedullary arteriovenous malformation (arrow) in 18-year-old boy. Sagittal T1-weighted (400/28) image shows that vertebral angioma involves T8 and T9 with huge low-intensity signal within vertebral body (arrowheads).

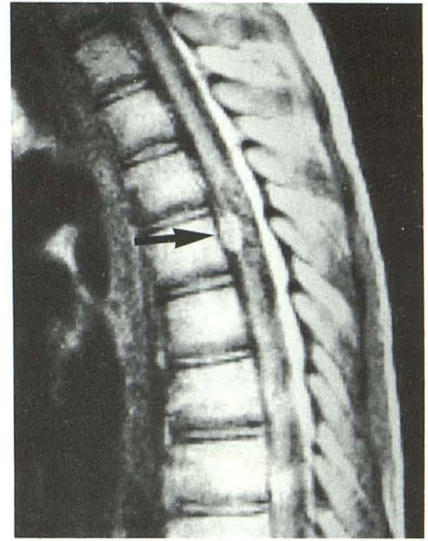


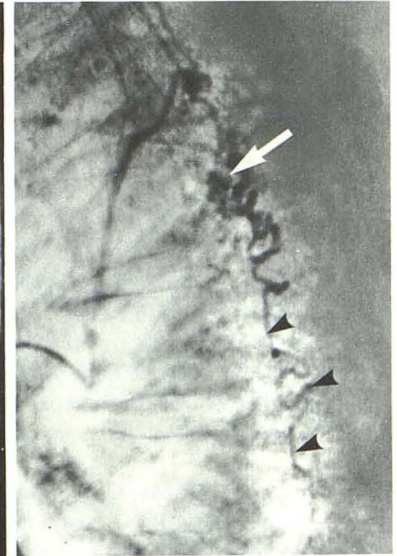
Fig. 4.—Thoracic intramedullary arteriovenous malformation in 15-year-old boy. Pre-midline hyperintensity on sagittal T1-weighted (400/28) image corresponds to a chronic subdural hematoma (arrow).

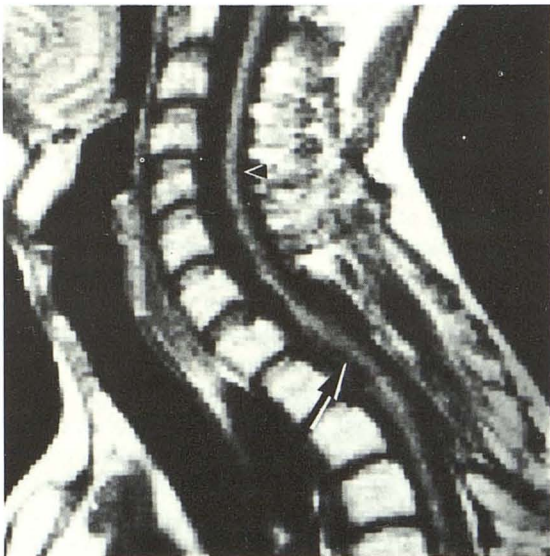
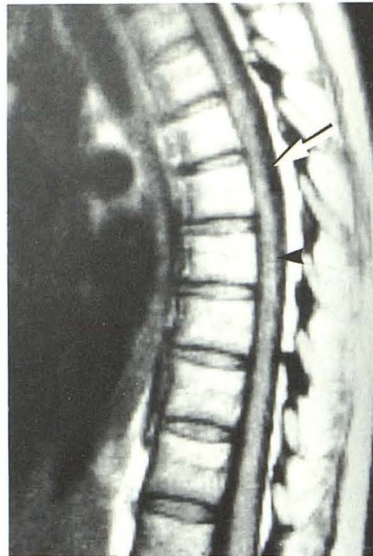
Fig. 5.—Sagittal T1-weighted (400/28) image shows upper thoracic intramedullary arteriovenous malformation (arrow) associated with cervical spinal cord atrophy (arrowhead) in 28-year-old patient.



A



B

Fig. 6.—Extramedullary thoracic arteriovenous malformation in 30-year-old woman. The identification is difficult on sagittal T1-weighted (400/28) image behind the cord.  
 A, Slight area of low intensity is seen (arrow). Spinal cord signal and size are normal (arrowhead).  
 B, Corresponding selective angiogram, lateral view. The nidus (arrow) is fed by a posterior spinal artery. Note descending dilated veins (arrowheads).



### Perimedullary Fistulae

Perimedullary fistulae fed by radiculomedullary arteries represent another rare type of vascular malformation of the cord affecting young adults [9, 10]. MR was performed in three cases. One of the patients presented with a microfistula of the anterior spinal artery. The MR was normal. The two other patients had a giant fistula of the conus. Huge signal-void images corresponding to the aneurysmal dilatation of the veins were well seen (Fig. 7).

### Dural AVFs with Perimedullary Drainage

Dural AVFs with perimedullary drainage consist of a direct, microscopic fistula between a dural branch of a radicular artery and the perimedullary veins. The fistula is located between D3 and S2. Whatever the level of the fistula, the clinical result is a progressive myeloradiculopathy (often a conus medullaris syndrome) that occurs in patients who are 60 years old or older [11].

MR exploration of the conus medullaris was performed in seven patients. Sagittal T1-weighted images showed a slight enlargement of the conus (Fig. 8A). Axial T1-weighted images define this slight enlargement with a central area of hypointensity, but axial T2-weighted images were more informative. On these T2-weighted images the conus had a high signal in all cases. Careful observation also revealed subarachnoidal signal-void images that could be correlated with enlarged perimedullary veins. After treatment, all patients improved dramatically. In two of them a follow-up MR study showed a significant decrease of the pathologic signal of the conus. And in one patient a strictly normal MR appearance correlated well with the clinical cure (Fig. 8D).

### Discussion

Very few reports of the MR appearance of spinal cord AVMs have been published in the literature. Six cases were reported in a study by Di Chiro et al. [1] in which MR was performed without a surface coil. MR was informative in three of four cases of intramedullary AVM, and the authors identified the nidus as an intramedullary low signal surrounded by spinal cord tissue. In two cases of dural AVF, the examination focused on the level of the fistula and was not able to demonstrate the lesion. A retrospective study showed vascular signal void that could correspond to the venous drainage.

Kulkarni et al. [2] examined a pregnant patient with spinal hemorrhage using a 0.5-T magnet with sagittal and coronal slices (spin echo and inversion recovery). The results showed a vascular signal void that probably corresponded to the feeding vessels.

Recently, Masaryk et al. [3] reported on signal abnormalities of the conus medullaris in three patients with dural AVF.

The purpose of our study was to test the value of MR as a noninvasive procedure for diagnosing AVMs of the spinal

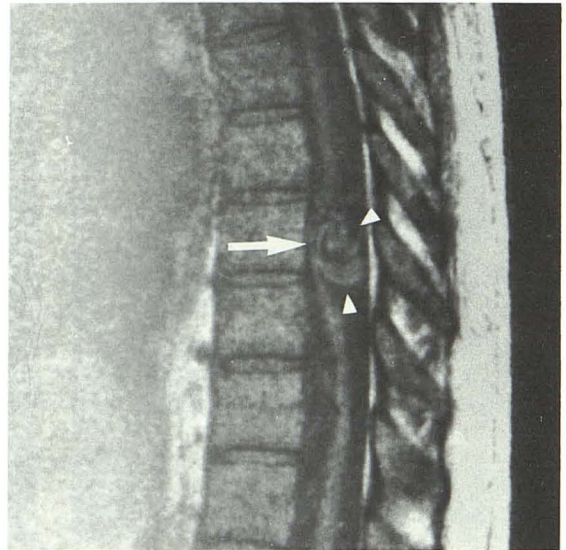


Fig. 7.—Perimedullary fistula above conus medullaris in a 38-year-old patient. Sagittal T1-weighted (400/28) image. In thoracic area, spinal cord is displaced forward (arrow) by huge abnormal signal structures (arrowheads) corresponding to posterior venous drainage.

cord. Today, routine examination of spinal cord AVMs includes myelography and arteriography. Myelography gives an indirect image of enlarged vessels that are defined by selective angiography. The combination of these examinations with anteroposterior and lateral views demonstrates the relationship between the nidus and the spinal cord. In our study, MR diagnostic protocol (TE, TR, image planes) was determined by the performance of our magnet.

### Intramedullary AVMs

We confirmed the ability of MR to easily recognize intramedullary AVMs, or the intramedullary component of an extramedullary lesion. The association of spinal cord enlargement with intramedullary signal changes corresponding to the nidus was a constant and easily recognizable finding in every sequence. Vascular flow-void images do not permit differentiation between arterial feeders and high-flow venous drainage because they produce the same signal. Postembolization aspects are difficult to analyze. We speculate that the disappearance of high-flow signal void and the signal changes within the nidus may correspond to intravascular embolic material and/or consequent progressive thrombosis. Finally, interesting information is also available on such complications as atrophy and chronic hematoma with the latter easily diagnosed on sagittal T1-weighted images.

### Extramedullary AVMs

In our experience these malformations were not identified on sagittal T1-weighted images. But all patients had previous



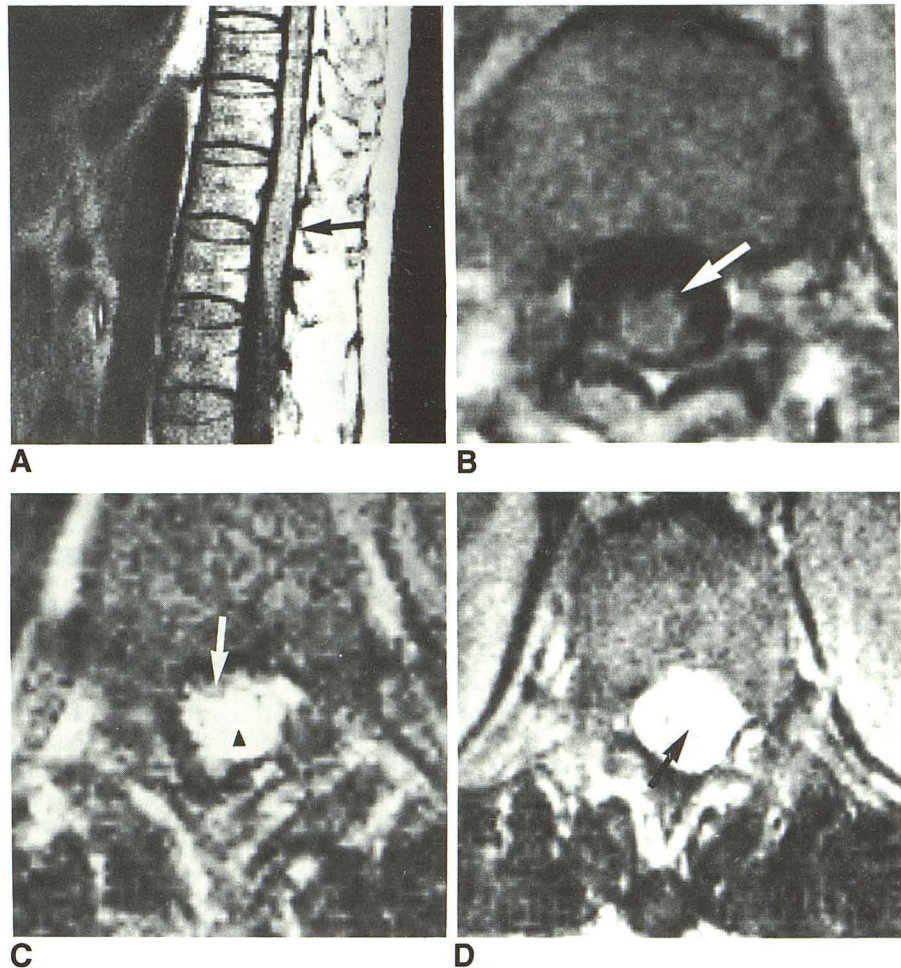
Fig. 8.—Dural arteriovenous malformation with perimedullary drainage in a 60-year-old patient.

A, Sagittal T1-weighted (400/28) image shows that conus medullaris is slightly enlarged (arrow).

B, Axial T1-weighted (400/28) image. Anterior venous drainage can be identified as areas of signal void (arrow).

C, Transverse T2-weighted (2000/120) image shows characteristic MR finding suggesting chronic ischemia. Note anterior signal void corresponding to perimedullary veins (arrow) and global hyperintensity of conus (arrowhead).

D, 3 months after treatment patient has improved clinically and axial T2-weighted (2000/120) image shows significant decrease in abnormal signal (arrow) of conus medullaris.



angiographic examinations, and axial sequences were performed at the level of angiographic abnormalities. Therefore, it is difficult to assess the ability of MR as a diagnostic first step. It must be emphasized, however, that MR seems to be the best examination for defining the site of the nidus, which is important for indicating the course of therapy [12].

#### Dural AVFs

In dural AVFs, the MR slice thickness we had to use (6 mm) seemed to us inappropriate to show the microfistula directly. For this, thinner slices would be necessary. We therefore focused the MR exploration on the conus medullaris, which appeared to be the site of clinical findings (pathophysiological hypothesis suggested a chronic venous high pressure). Conus enlargement and intramedullary high signal were observed in all cases. These abnormalities are compatible with chronic venous ischemia as reported by Masaryk et al. [3]. Clinical improvement after successful endovascular or surgical treatment corresponded to total or partial regression of the MR abnormalities in the two patients reexamined.

#### Conclusions

MR is helpful in the diagnosis of AVMs involving the spinal cord as it provides accurate information as to the exact location of the nidus. As far as extramedullary malformations are concerned, improvement of the MR resolution is still necessary before MR can represent the first diagnostic step. Therefore, myelography might be used only in cases of negative MR examinations. In any case, arteriography cannot yet be discarded as a method for studying the vascular architecture of the malformation.

#### REFERENCES

1. Di Chiro G, Doppman JL, Awyer AJ, et al. Tumors and arteriovenous malformations of the spinal cord: assessment using MR. *Radiology* 1985;156:689-697
2. Kulkarni MV, Burks DD, Price AC, et al. Diagnosis of spinal arteriovenous malformation in a pregnant patient by MR imaging. *J Comput Assist Tomogr* 1985;9:171-173
3. Masaryk TJ, Ross JS, Modic MT, Ruff RL, Selman WR, Ratcheson RA. Radiculomeningeal vascular malformations of the spine: MR imaging. *Radiology* 1987;164:845-849

4. Modic MT, Masaryk TJ, Paushter D. Magnetic resonance imaging of the spine. *Radiol Clin North Am* **1986**;24:229-245
5. Djindjian R. *Angiographie de la moelle épinière*. Paris: Masson Edit., 1970
6. Hurth M, Houdart R, Djindjian R, Rey A, Djindjian M. Arteriovenous malformations of the spinal cord. *Prog Neurol Surg* **1978**;9:238-266
7. Riche MC, Reizine D, Melki JP, Merland JJ. Classification of spinal cord malformations. *Radiat Med* **1985**;3(1): 1, 17-24
8. Djindjian M, Djindjian R, Rey A, Hurth M, Houdart R. Intradural extramedullary spinal arteriovenous malformations fed by the anterior spinal artery. *Surg Neurol* **1977**;8:85-94
9. Gueguen B, Merland JJ, Riche MC, Rey A. Vascular malformation of the spinal cord: intrathecal perimedullary arteriovenous fistulas fed by medullary arteries. *Neurology* **1987**;37:969-979
10. Merland JJ, Riche MC, Chiras J. Les fistules artério-veineuses intracanales extra-médullaires à drainage veineux médullaire. *J. Neuroradiol* **1980**;7:271-320
11. Kendall BE, Logue V. Spinal epidural angiomatous malformations draining into intrathecal veins. *Neuroradiology* **1977**;13:181-189
12. Cogen P, Stein BM. Spinal cord arteriovenous malformations with significant intramedullary component. *J. Neurosurg* **1983**;59:471-478