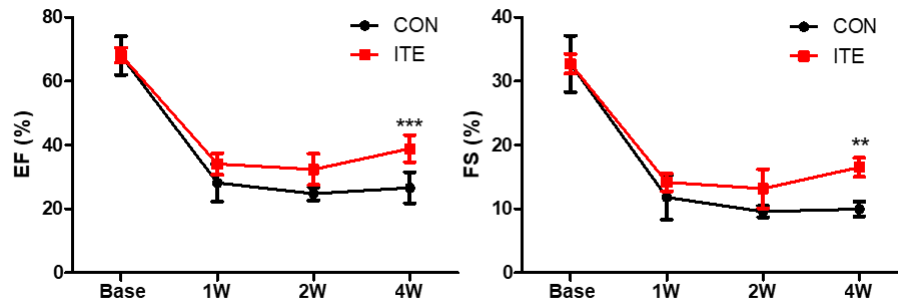


SUPPLEMENTAL MATERIAL

Figure S1. Time course of improvements in EF and FS obtained by echocardiography for 4 weeks.



Echocardiography was performed before LAD ligation (base, n=5) and at 1-week intervals after LAD ligation in each group (control, n=5; ITE, n=10). Data are presented as the mean \pm SEM. ** $P < 0.01$, and *** $P < 0.001$. EF indicates ejection fraction and FS, fractional shortening.