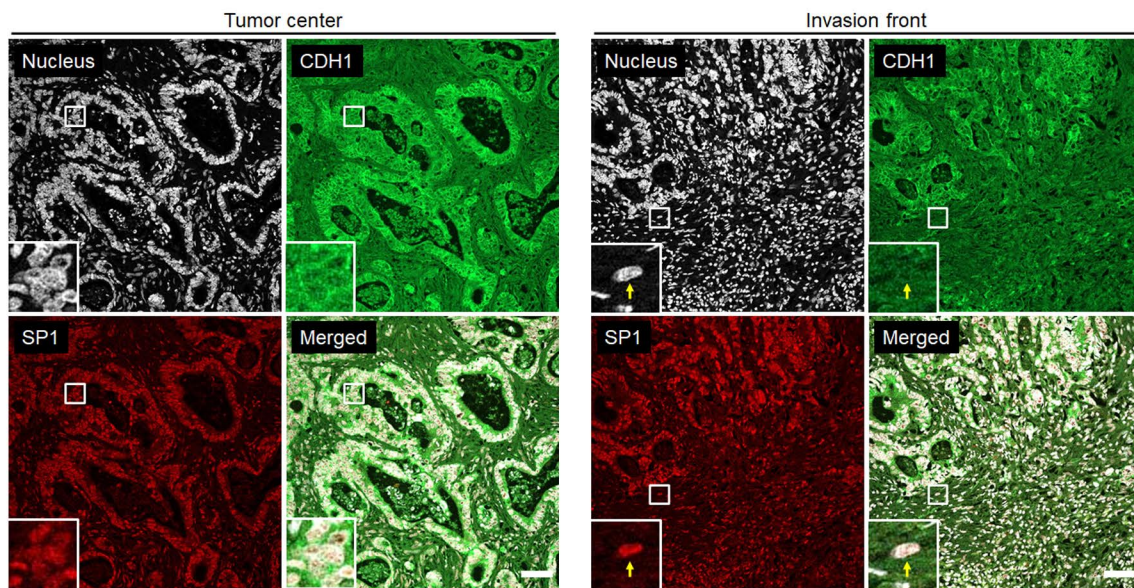


(A)



(B)

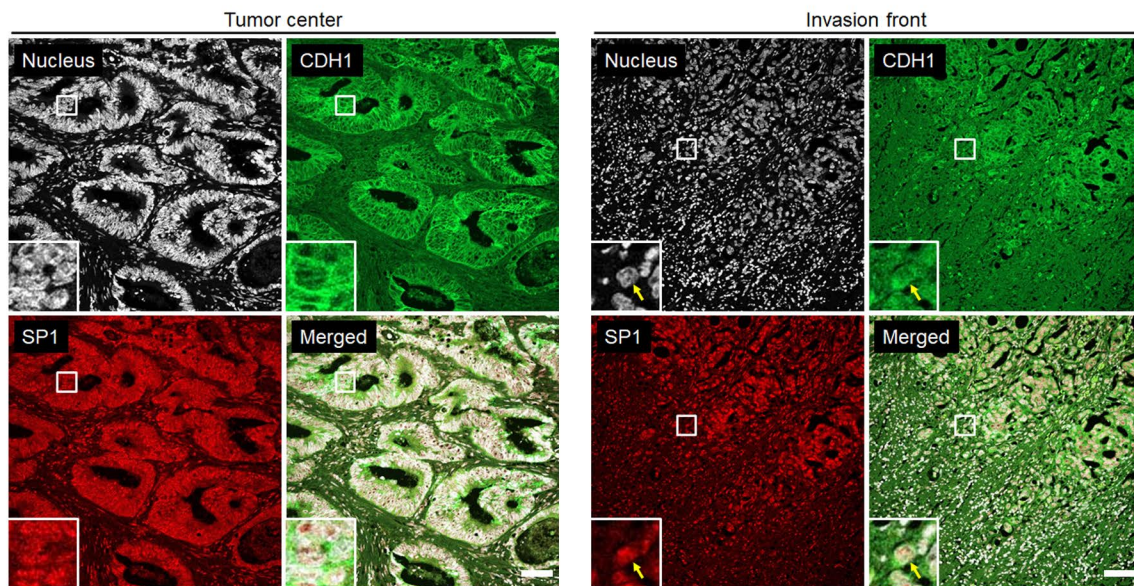


Figure S5

Immunohistochemical analysis of SP1 in clinical CRC samples. A and B, Immunostaining of SP1 (green) and CDH1 (red) in paraffin-embedded sections of primary colon cancer from the same cases as shown in Figure 4 and S4, respectively. Bars, 20 μ m.