

Online Supplement for “Quantitative Video-Oculography to Help Diagnose Stroke in Acute Vertigo and Dizziness: Toward an ECG for the Eyes” by Newman-Toker, et al.

Table I. ‘H.I.N.T.S.’ to ‘I.N.F.A.R.C.T.’: Oculomotor findings differentiate peripheral vestibulopathy from vertebrobasilar stroke in acute vestibular syndrome (AVS)* (estimates from Tarnutzer, et al., 2011¹)

Oculomotor Finding on Clinical “H.I.N.T.S.” Battery (<u>H</u> ead <u>I</u> mpulse, <u>N</u> ystagmus, <u>T</u> est of <u>S</u> kew)	Vertebrobasilar Stroke	Vestibular Neuritis
<u>I</u> mpulse <u>N</u> ormal†: horizontal head impulse test (h-HIT) measures normal VOR response ²	99% (PICA/SCA); 62% (AICA‡)	5%
<u>F</u> ast-phase <u>A</u> lternating: direction-changing horizontal nystagmus ³ evoked by lateral gaze right and left	38%	8%
<u>R</u> efixation on <u>C</u> over <u>T</u> est: vertical skew deviation ⁴ as assessed by alternate cover testing	30%	2%
No ‘I.N.F.A.R.C.T.’ eye signs: unilateral abnormal h-HIT, direction-fixed horizontal nystagmus, no skew deviation	2%	85%

AICA – anterior inferior cerebellar artery; PICA – posterior inferior cerebellar artery; SCA – superior cerebellar artery; VOR – vestibulo-ocular reflex

* The pooled sensitivity of the H.I.N.T.S. approach when applied clinically by experts is 98% (n=97/99) compared to 80% (n=220/275) for early, acute MRI (<24 hours after AVS onset).¹ A non-stroke H.I.N.T.S. result reduces the odds of stroke 50-fold (negative likelihood ratio 0.02, 95% CI 0.01-0.09).¹ Our systematic review found strong evidence (GRADE system⁵) for adequately-trained providers to use these findings for stroke diagnosis in AVS.¹

† The H.I.N.T.S. approach is only effective if applied specifically to patients with AVS, since a normal physiologic finding (i.e., impulse normal) is considered a “bad sign” (i.e., predicts stroke). Using this approach in patients with transient or purely positional dizziness or vertigo will lead to many ‘false positive’ H.I.N.T.S. results. However, when AVS patients have persistent pathologic nystagmus of any kind (e.g., spontaneous or gaze-evoked), a normal head impulse result is a powerful (nearly perfect) predictor for the presence of a central lesion, usually stroke.¹

‡ AICA-territory strokes often mimic benign peripheral lesions more closely than other posterior fossa strokes. This is because the blood supply to the inner ear usually derives from the AICA, often leading to isolated labyrinthine or combined posterior fossa and labyrinthine infarctions that impair the VOR through direct ischemia to the inner ear.⁶ These ‘pseudo-labyrinthine’ cases are usually detectable by the presence of one or both of the other two H.I.N.T.S. signs (i.e., direction-changing nystagmus or skew deviation). The magnitude of this diagnostic problem clinically is small. Together, PICA and AICA strokes account for ~95% of strokes causing the AVS, and, in this population, PICA strokes outnumber AICA strokes roughly 5:1.¹ In total, AICA strokes only account for about 15% of AVS presentations, and only 38% of AICA infarctions present with an abnormal head impulse.¹ Thus, AICA strokes with clinically abnormal impulses (pseudo-labyrinthine) only account for about 6% of AVS presentations. Approximately 1-2% of all AVS presentations are due to AICA strokes with a pure peripheral mimic on all three H.I.N.T.S. tests.

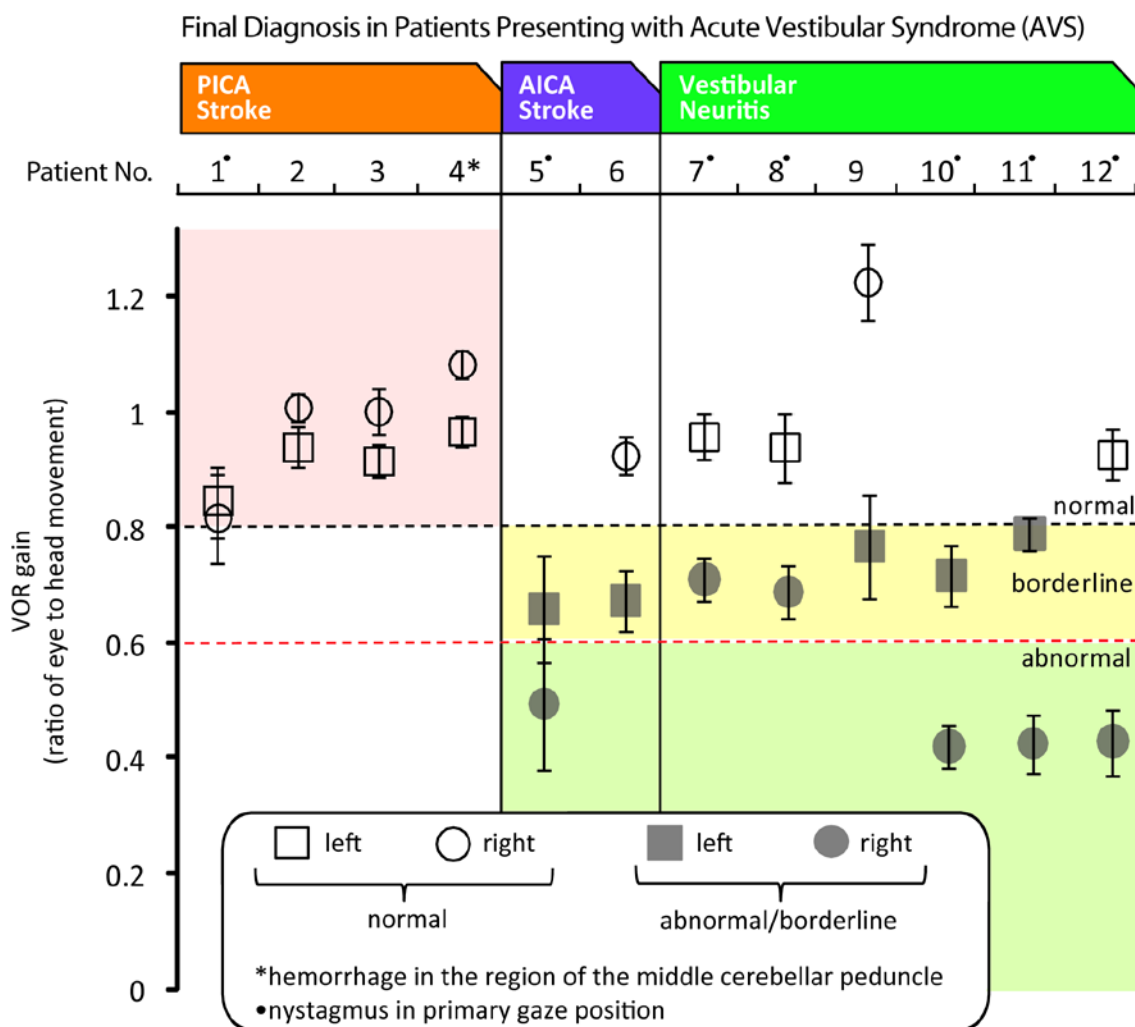


Figure II. Absolute VOR gain abnormalities for 12 AVS patients with confirmed final diagnoses

Shown are results from the 12 AVS patients in whom gold-standard diagnostic neuroimaging was performed. Nine experienced vertigo but three had non-vertiginous dizziness (Patients #1, #3, #6). Associated clinical features included headache or neck pain in four (Patients #3, #8, #10, #11), and focal general neurologic signs in two (Patients #1, #6). All patients had pathologic (i.e., spontaneous, primary position [straight ahead gaze] or gaze-evoked) nystagmus; patients with gain asymmetries were more likely to have primary position nystagmus.

Results are from quantitative, bedside h-HIT testing using a video-oculography device. Patients are grouped by diagnosis and arrayed from least to greatest relative right-left VOR asymmetry (as shown in manuscript Figure 3A). The figure above shows mean right- and left-sided VOR absolute gain values and 95% confidence intervals. Borderline or abnormal gain values are shown in gray. Pink shading indicates patients with bilaterally normal VOR gains, all of whom had radiographic cerebrovascular events (four PICA strokes and one a small cerebellar hemorrhage abutting the fourth ventricle in the region of the middle cerebellar peduncle). Among those with borderline (yellow shading) or abnormal (green shading) VOR gain values, AICA strokes could be differentiated from vestibular neuritis based on the presence of direction-changing nystagmus or skew deviation (manuscript Figure 3B). AICA strokes mimic vestibular neuritis more closely than PICA strokes because the blood supply to the inner ear usually derives from the AICA, frequently resulting in combined cerebellar and labyrinthine infarctions, the latter of which impair the VOR response. Approximately 80% of strokes causing AVS are PICA strokes.¹

Abbreviations: AICA – anterior inferior cerebellar artery; AVS – acute vestibular syndrome; h-HIT – horizontal head impulse test; PICA – posterior inferior cerebellar artery; VOR – vestibulo-ocular reflex

e-Methods. Detailed Methods Description

Study Design

We conducted a proof-of-concept study at two tertiary-care academic medical centers (OSF Saint Francis Medical Center [SFMC], Peoria, IL; The Johns Hopkins Hospital [JHH], Baltimore, MD). Results of a new test (quantitative head impulse video-oculography) were compared to the reference standard (neuroimaging) for acute stroke diagnosis. To be included, all patients had to undergo stroke-protocol MRI within seven days of symptom onset; some also underwent CT. Tests were performed prospectively but analyzed post-hoc by masked experts.

Study Population

We enrolled adult (≥ 18 years) ED patients with AVS seen < 7 days since symptom-onset and still symptomatic. Patients were recruited through a combination of active and passive surveillance during convenience shifts (generally business hours), but we report here a consecutive series of those who had the requisite imaging. We included patients with continuous vertigo or dizziness having lasted at least one hour plus pathologic nystagmus and at least one of the following: (1) nausea or vomiting, (2) head motion intolerance, or (3) new gait or balance disturbance. We defined pathologic nystagmus as (a) any spontaneous nystagmus appearing in the straight ahead gaze position, or (b) nystagmus on lateral gaze that was sustained or asymmetric. Visual fixation was blocked using Frenzel goggles in all patients to unmask any spontaneous or gaze-evoked nystagmus. We excluded patients with relevant prior vestibular or oculomotor disorder (e.g., vestibular neuritis, congenital nystagmus), acute drug/alcohol intoxication, or new head trauma. The study protocol was approved by the institutional review board at both sites.

Data Collection

We recorded demographic data, symptoms, and oculomotor signs through direct patient interview and examination. Two trained post-doctoral fellows (JHH) and either a trained nurse or neuro-otologist (SFMC) used a noninvasive, quantitative video-oculography device (ICS Impulse, GN Otometrics, Taastrup, Denmark, www.icsimpulse.com) to measure and record eye movements, including the quantitative horizontal head impulse test (h-HIT). Patients were examined seated upright. The h-HIT was applied as a rapid horizontal head rotation from lateral to center with the patient visually fixating on a target roughly 5-10 feet away. The amplitude of the movement applied was generally very small (usually 5-10 degrees). This amplitude is smaller than is often applied in non-quantitative clinical h-HIT testing. When using the device, a larger amplitude movement causes the eye to move out of the camera frame and is unnecessary because of the enhanced sensitivity of the device to small-amplitude refixation saccades. Optimal head velocity was 100-200 degrees/second, and at least 20 h-HIT trials to each side were performed. Examiners (either a neuro-otology fellow or expert neuro-otologist) also looked for a clinically-abnormal h-HIT, nystagmus in different gaze positions, and ocular alignment (alternate cover test for vertical misalignment of the eyes [skew deviation]).^{7,8}

The video-oculography device measures head velocity with an internal sensor. It records monocular eye movements with a high-speed infrared camera over the right eye (maximum frame capture rate 250 frames per second). Computer software (OTOSuite Vestibular Software Version 1.20 Build 310) detects eye position and velocity from the video in real time using an automated pupil-tracking algorithm. A brief (< 1 minute), simple calibration procedure ensures accurate eye movement recordings; this involves asking the patient to look at a series of dots of light projected onto a flat surface (e.g., wall) in front of them. The device has been validated against the gold standard for oculomotor recordings (magnetic scleral search coils) to accurately measure the h-HIT in humans with normal and chronically-abnormal vestibular function.⁹ This device is sold commercially and was approved by the US Food and Drug Administration (FDA) as a vestibular function test device in February, 2013. During the conduct of our study, the device, sold commercially in Europe, was used in the US for research pending regulatory approval. The ICS Impulse device is **not** FDA-approved for the indication of diagnosing stroke or any other condition.

Stroke protocol MRI images at JHH included axial T2, FLAIR, and DWI (25 5-millimeter axial slices with an interslice gap of 1.5 millimeters) performed on a 1.5-T Aera MR imaging unit (Siemens, Erlangen, Germany). Stroke protocol MRI images at SFMC included axial T2, FLAIR, and DWI (20 5-millimeter axial slices with an interslice gap of 2 millimeters) performed on a 1.5-T MR imaging unit (GE Medical Systems, Milwaukee, WI). Original neuroimages were extracted from electronic medical records for masked review.

Outcome Measures

The device software recognizes and collects correctly-performed h-HIT maneuvers using a two-stage algorithmic filtering process. It discards inappropriately performed h-HITs (e.g., too fast or too slow a head velocity) and trials in which pupil tracking is lost (e.g., due to blinks). The software reports final h-HIT results graphically as overlaid head and eye velocity traces across multiple trials (manuscript Figures 1/2, panels A/B). It also plots the VOR gain ratio (eye velocity divided by head velocity using area-under-the-curve methods, after using an automated algorithm to ‘de-saccade’ the head impulse of any intrusive, fast eye movements) for each h-HIT trial, and then calculates a side-specific mean across all trials for that patient (manuscript Figures 1/2, panel C). We separately calculated the relative right-left asymmetry in mean VOR gain ratio ($1 - [\text{lower mean gain}/\text{higher mean gain}] \times 100\%$). The relative right-left asymmetry in the VOR gain (displayed in manuscript Figure 3A) was calculated as follows:

$$\text{Asymmetry [\%]} = \left(1 - \frac{\text{lower gain}}{\text{higher gain}}\right) \times 100\%$$

We did not apply Jongkees’ formula (normalized relative right-left asymmetry), which is typically used for comparing right and left VOR function during caloric testing.¹⁰ We chose our approach because there was no need to normalize the data—the head impulse input (peak head velocity) and output (peak eye velocity) is well defined (i.e., for a gain of 1.0, the expected output = input). By contrast, this is not the case in caloric testing, where the effective applied thermal energy varies across subjects and ears, so results must be normalized to have meaning.

The mean gain ratio is the primary composite measure of overall VOR function on each side (i.e., right and left). It may be supplemented by expert interpretation of the physiologic traces and graphical gain plots, which can indicate confirmatory physiologic patterns or help identify low-quality data. In this study, experts assessed all aspects of the h-HIT reports. We considered a mean gain ratio >0.8 normal, <0.6 abnormal, and 0.6-0.8 borderline (see Technical Notes below). If a mean absolute gain was borderline, a right-left asymmetry >20% was considered an abnormal h-HIT. Two independent, expert neuro-otologists masked to all other clinical information, including neuroimaging, categorized each patient as a suspected central pattern (i.e., bilaterally normal VOR), a suspected peripheral pattern (i.e., unilaterally abnormal VOR), or equivocal, using only h-HIT results (physiologic traces, gain value plots, mean gain). They were then given the other clinical H.I.N.T.S. findings (nystagmus and skew) and asked to re-code.

Results were compared to final radiographic diagnoses of “stroke” or “no stroke” (i.e., non-stroke cause evident by neuroimaging or no cause identified). Stroke diagnoses were based on CT or MRI showing acute hemorrhage, MRI-DWI showing acute ischemic stroke (any time post symptom-onset), or delayed MRI-DWI showing no acute stroke (>48 hours but <7 days after symptom-onset). Neuroimaging diagnoses (stroke vs. no stroke) were rendered by two independent neuroimaging experts, masked to all clinical information.

Statistical Analysis

We report descriptive statistics and detailed quantitative results for all patients. For agreement between raters, Cohen’s kappa was calculated using SPSS software version 17 (SPSS Inc., Chicago, IL).

Additional Note on Commercial Relationships and Choice of Device

The authors would like to make a final note regarding choice of the ICS Impulse device (<http://icsimpulse.com/>) over similar commercially-available products such as the EyeSeeCam (<http://eyeseecam.com/>) or Video Head Impulse Test Ulmer (<http://www.synapsys.fr/en/p-video-head-impulse-test-ulmer-vhit-ulmer-48.htm>). As indicated in the disclosure section, no one on our team has any commercial or financial interest in the ICS Impulse device. Our choice to focus on using this particular device for this study was made for scientific reasons. To our knowledge, only the ICS Impulse and EyeSeeCam devices have been validated against magnetic scleral search coil recordings (the gold standard in eye movement recording techniques). Both companies have loaned their devices to our study team for research purposes. Although the EyeSeeCam has greater oculomotor measurement flexibility in its current software, the ICS Impulse has a simpler, unibody design without moving or detachable parts, is more comfortable, operates in a Windows rather than Macintosh environment, is fully UL and biocompatibility compliant, and was closer to FDA approval in the US (and, at the time of publication, had been approved by the FDA as a vestibular testing device). We believe these features make the ICS Impulse device more likely to be widely disseminated in an emergency department environment, especially in the US, so we chose to focus our initial efforts in AVS using this particular device. We have been using the EyeSeeCam preferentially for laboratory-based studies.

Technical Notes

Outlier values and test-retest reliability: Video-oculography is an imperfect measure relative to the gold standard for eye movement assessment (magnetic scleral search coil recordings). In general, our h-HIT values were clustered fairly tightly across multiple attempts (e.g., Figures 1/2, panel C). Sometimes, however, individual measures (or even h-HIT means) were outside the anticipated range. For example, patient #9 with vestibular neuritis (online-only Figure I above) had a mean measured VOR gain on the unaffected side of roughly 1.2. Theoretically, a normal gain value should not exceed ~1.0. Nevertheless, “normal” mean VOR gains of up to about 1.2 are sometimes seen using search coil recordings.¹¹ Thus, some of our gain elevations (>1.0) may represent true physiologic values, but others could reflect measurement error using the device. Additional laboratory testing we have done with the ICS device indicates that goggles slippage may result in small, false gain elevations bilaterally (+ ~0.1-0.2). While this could have affected some of the absolute measures shown in online-only Figure I, they are unlikely to have affected the relative right-left measures (manuscript Figure 3A). Ultimately, because we are suggesting this method might eventually be used in clinical practice, we elected to include all relevant results (rather than removing outlier impulses, as might be done in a basic science study about VOR physiology). We believe our results show that the clinical diagnostic accuracy of the quantitative H.I.N.T.S. approach is robust to such minor measurement errors.

Normative values for quantitative head impulse results: Normative data from the outpatient setting using the ICS Impulse device indicate that quantitative head impulse results with gain <0.6 are clearly abnormal (ICS Impulse User Manual; ICS Impulse FAQ at <http://icsimpulse.com/>). However, VOR gain values between 0.6-0.8 have been reported using search coils in patients with acute vestibular neuritis, and these are presumed to represent true deficits, since the acute unilateral vestibular failure shown in these cases recovered over time.¹² Head impulse VOR data measured by coils in normal subjects suggest that right-left asymmetries of ~15-20% or more are pathologic.¹¹ In our study, the 0.8 and 20% asymmetry thresholds matched the clinical interpretation of abnormal impulses (based on inspection of eye movements by experts) and final anatomic diagnoses as rendered by gold standard MRI.

References

1. Tarnutzer AA, Berkowitz AL, Robinson KA, Hsieh YH, Newman-Toker DE. Does my dizzy patient have a stroke? A systematic review of bedside diagnosis in acute vestibular syndrome. *CMAJ : Canadian Medical Association journal = journal de l'Association medicale canadienne*. 2011;183(9):E571-92. PMID: 3114934.
2. Halmagyi GM, Aw ST, Cremer PD, Curthoys IS, Todd MJ. Impulsive testing of individual semicircular canal function. *AnnNYAcadSci*. 2001;942:192-200.
3. Leigh RJ, Zee DS. *The neurology of eye movements* (4th edition). New York: Oxford University Press, 2006.
4. Brodsky MC, Donahue SP, Vaphiades M, Brandt T. Skew deviation revisited. *SurvOphthalmol*. 2006;51(2):105-28.
5. Guyatt GH, Oxman AD, Kunz R, Falck-Ytter Y, Vist GE, Liberati A, Schunemann HJ. Going from evidence to recommendations. *BMJ*. 2008;336(7652):1049-51. PMID: 2376019.
6. Edlow JA, Newman-Toker DE, Savitz SI. Diagnosis and initial management of cerebellar infarction. *Lancet Neurol*. 2008;7(10):951-64.
7. Newman-Toker DE, Kattah JC, Alvernia JE, Wang DZ. Normal head impulse test differentiates acute cerebellar strokes from vestibular neuritis. *Neurology*. 2008;70(24 Pt 2):2378-85.
8. Kattah JC, Talkad AV, Wang DZ, Hsieh YH, Newman-Toker DE. HINTS to diagnose stroke in the acute vestibular syndrome: three-step bedside oculomotor examination more sensitive than early MRI diffusion-weighted imaging. *Stroke*. 2009;40(11):3504-10.
9. MacDougall HG, Weber KP, McGarvie LA, Halmagyi GM, Curthoys IS. The video head impulse test: diagnostic accuracy in peripheral vestibulopathy. *Neurology*. 2009;73(14):1134-41.
10. Furman JM, Jacob RG. Jongkees' formula re-evaluated: order effects in the response to alternate binaural bithermal caloric stimulation using closed-loop irrigation. *Acta oto-laryngologica*. 1993;113(1):3-10.
11. Hirvonen M, Aalto H, Migliaccio AA, Hirvonen TP. Motorized head impulse rotator for horizontal vestibulo-ocular reflex: Normal responses. *Archives of otolaryngology--head & neck surgery*. 2007;133(2):157-61.
12. Jutila T, Aalto H, Hirvonen TP. Recovery of the horizontal vestibulo-ocular reflex in motorized head impulse test is common after vestibular loss. *Acta oto-laryngologica*. 2012;132(7):726-31.