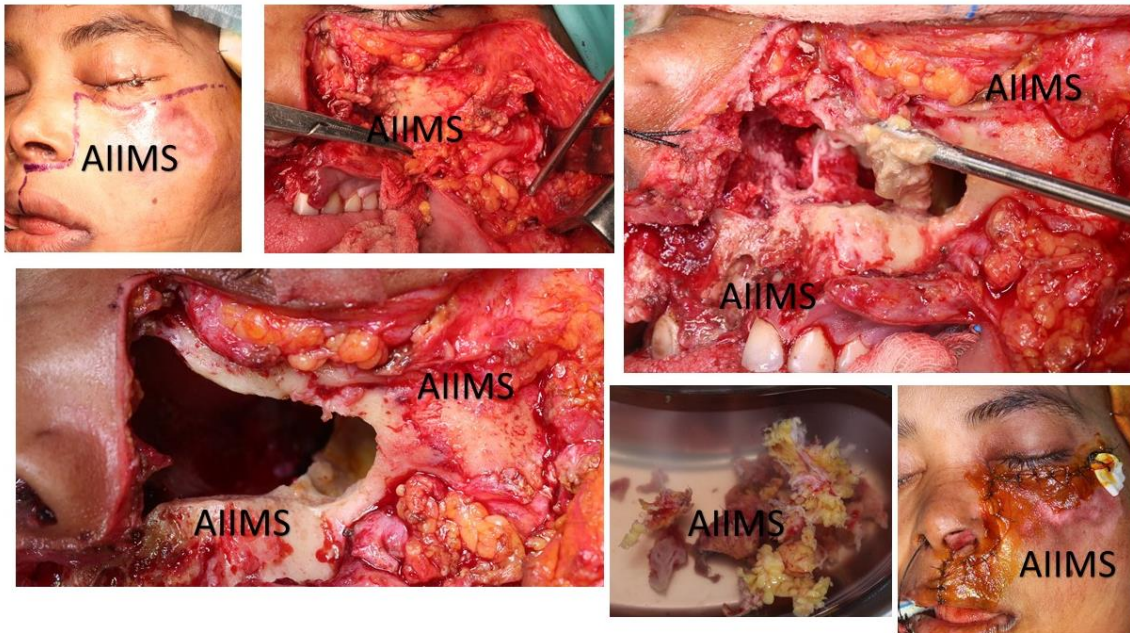
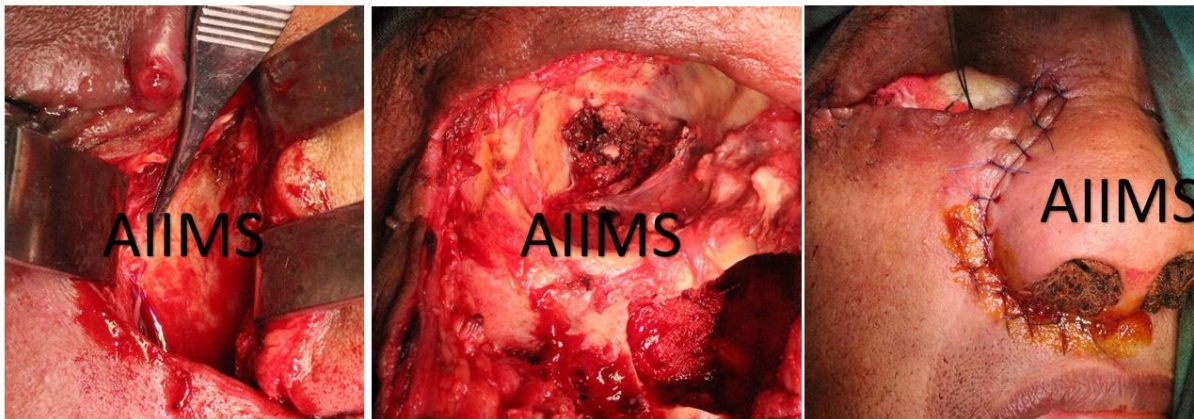


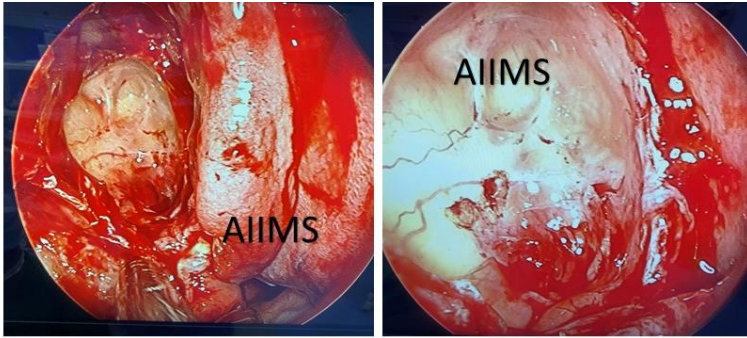
Photographs - intraoperative and post operative



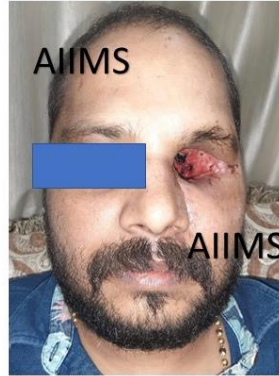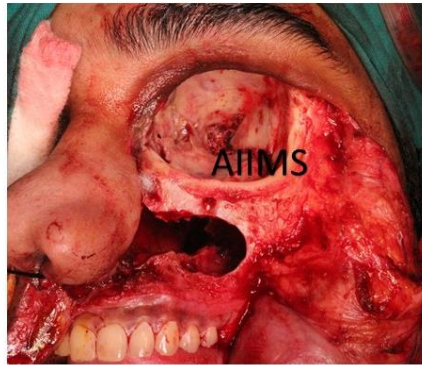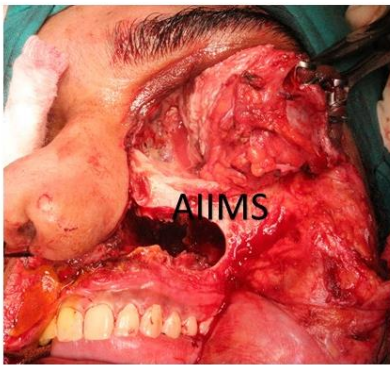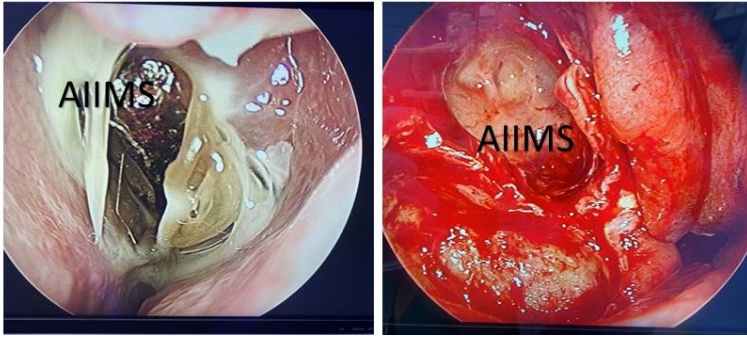Case depicting the Weberferguson with Fairbank - Barbosa extension for medial and anterior maxillectomy - skin and anterior maxillary involvement, primary closure of the defect.



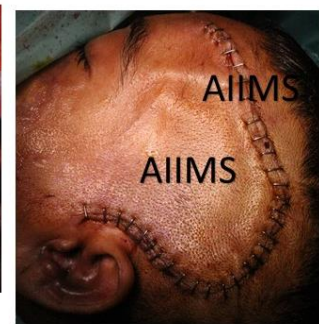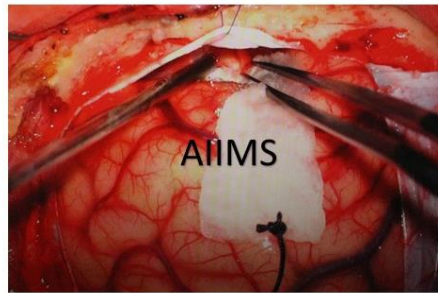
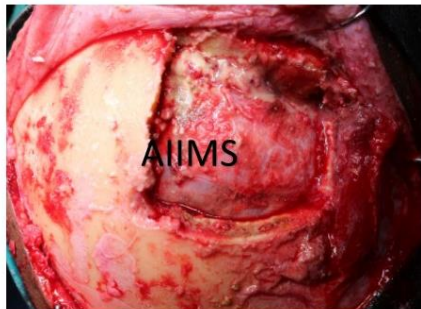
Case showing medial and anterior maxillectomy with orbital excenteration and primary closure.



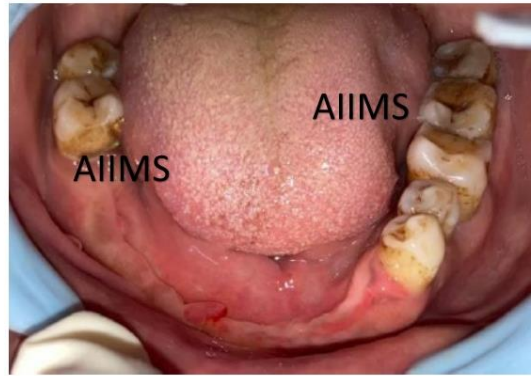
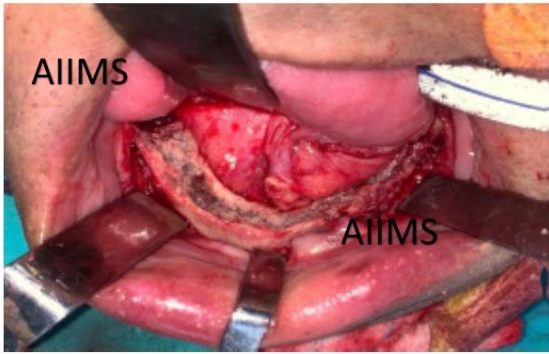
Photographs depicting the endoscopic debridement



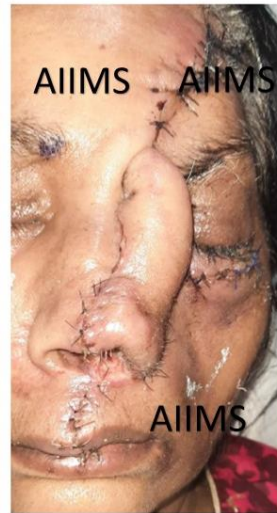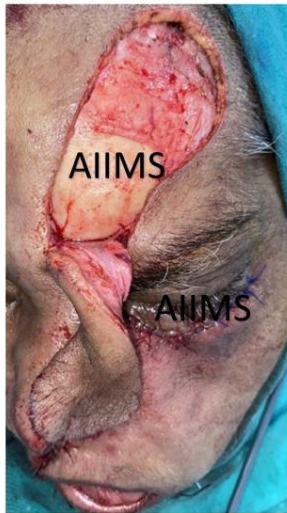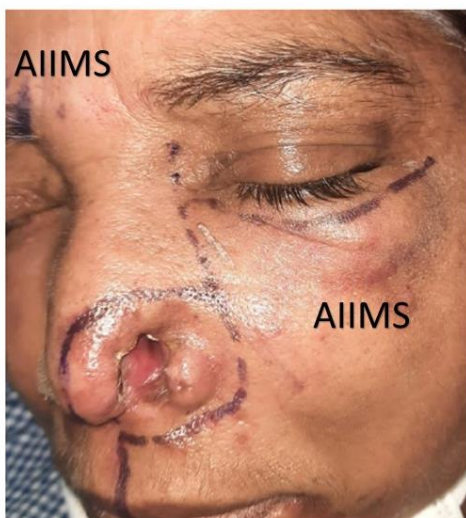A case of sino-naso-orbital mucormycosis with intraoperative and post operative photo.



Intra and post operative pictures of craniotomy for Mucormycosis.



Intra and post operative pictures of mandibular mucormycosis - marginal mandibulectomy with primary closure and post operative photograph (similar case)



Sino-Nasal mucormycosis with cutaneous involvement following debridement and paramedian forehead flap for alar repair.