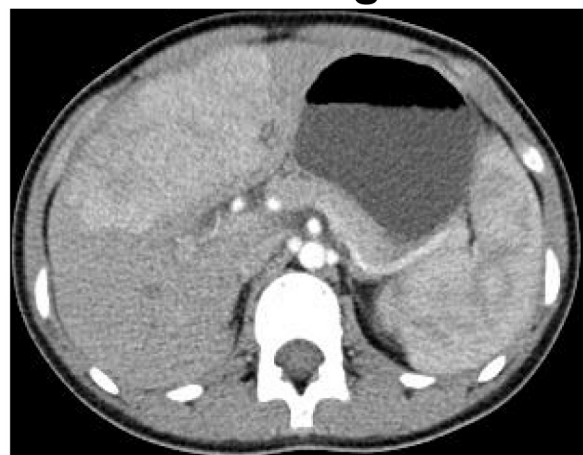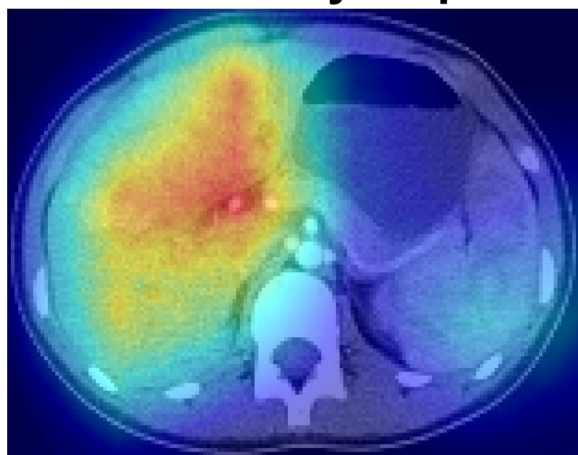


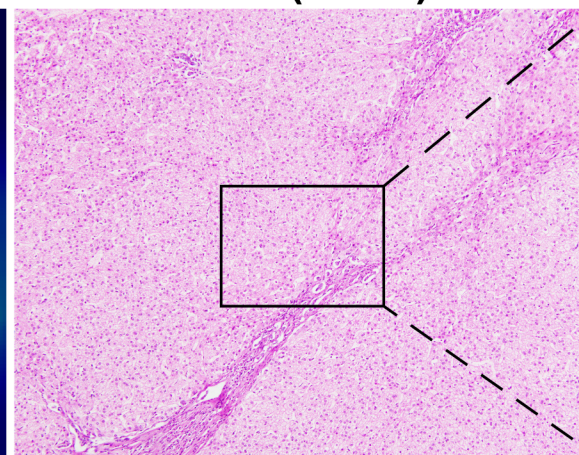
CT image



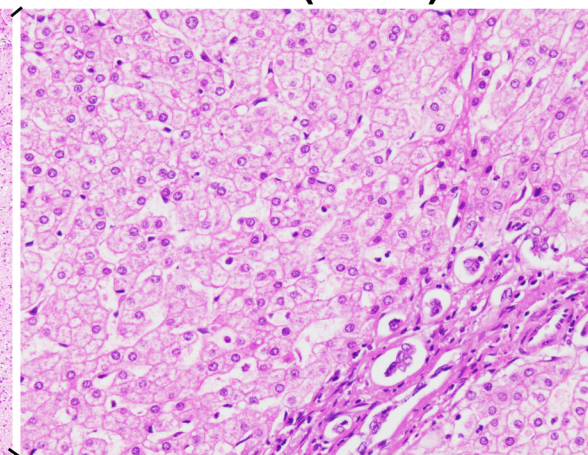
Saliency map



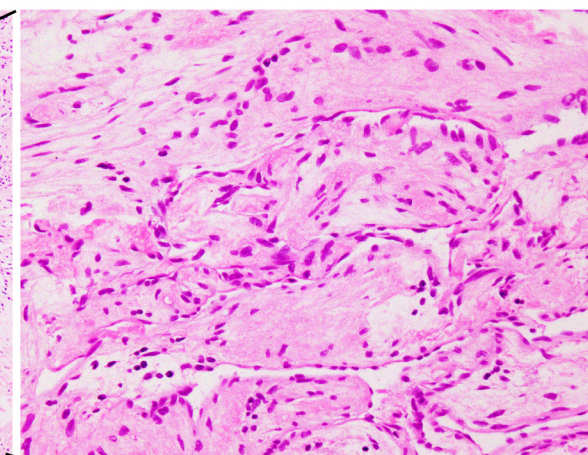
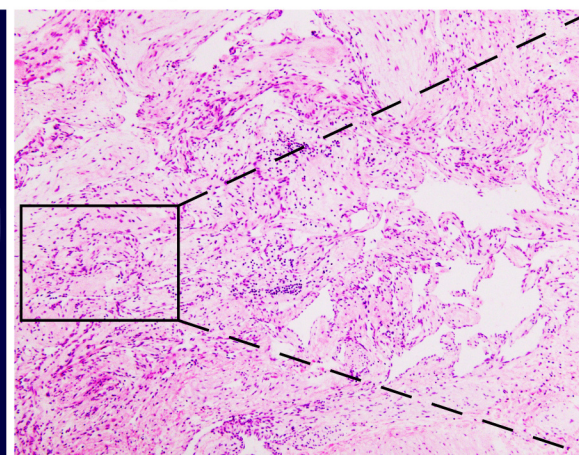
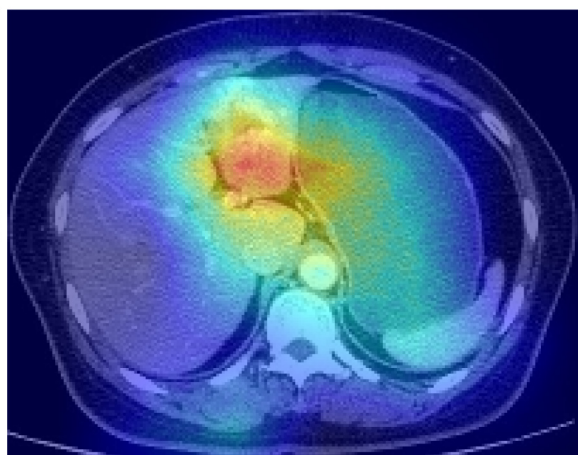
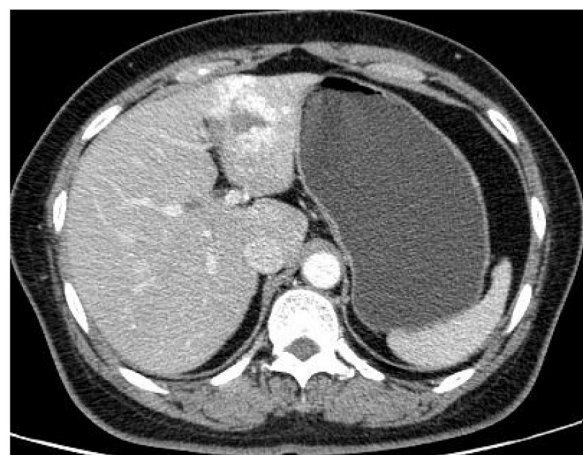
H&E(100X)



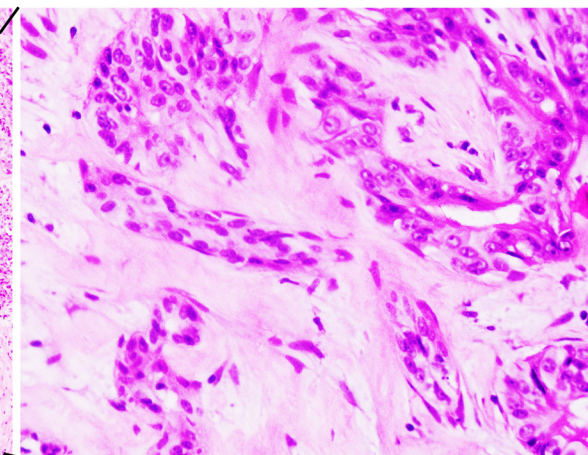
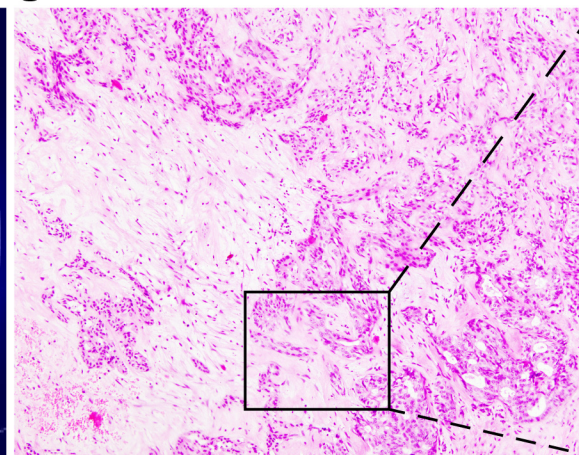
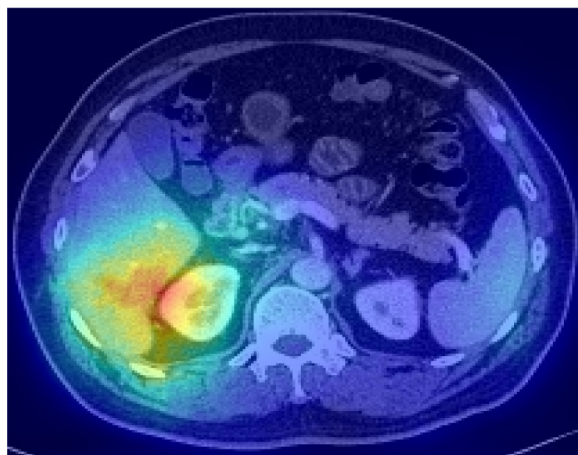
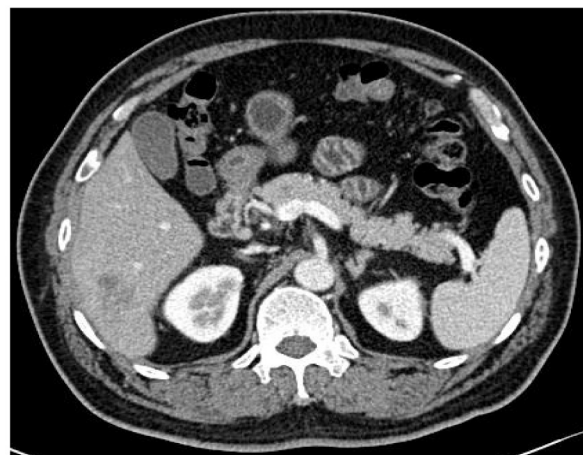
H&E(400X)



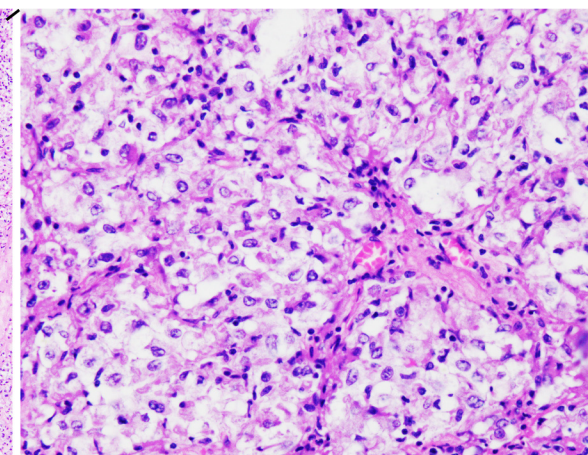
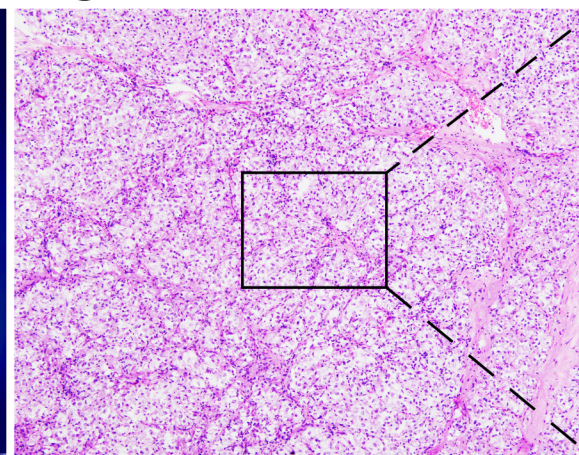
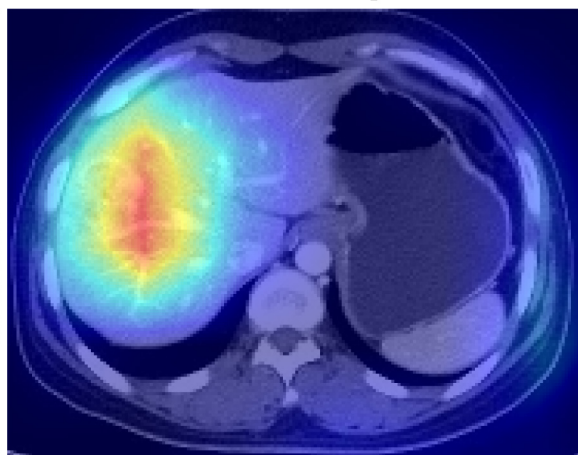
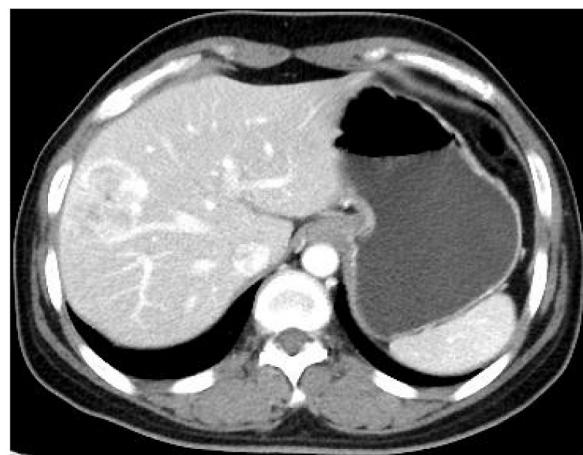Focal nodular hyperplasia



Hemangioma



Intrahepatic cholangiocarcinoma



Angioleiomyolipoma