

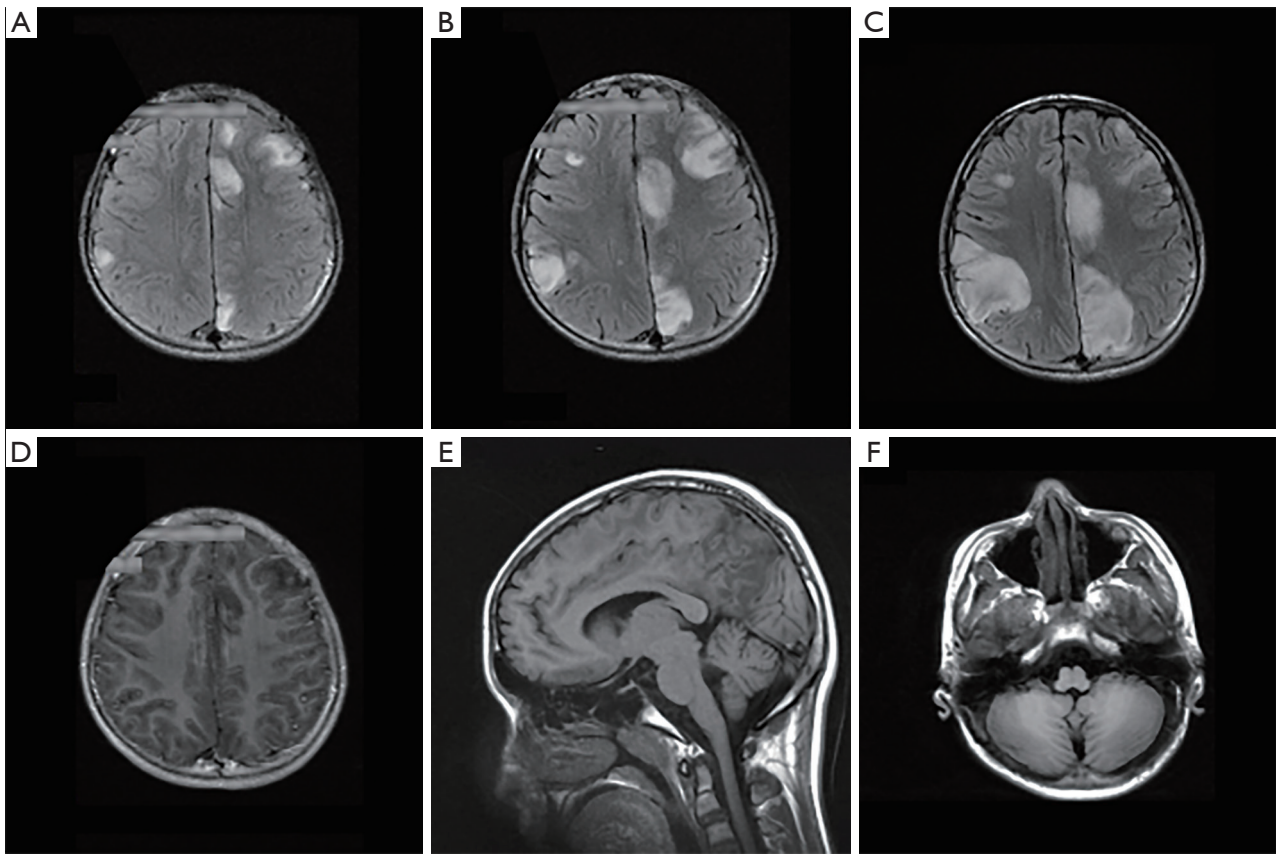Figure S1 Additional imaging features of the novel R317S variant. (A-C) Sequential MRIs taken 2 weeks apart from each other showed increased size of the cortical signal abnormalities on Axial FLAIR sequence. (D) No abnormal gadolinium enhancement was seen on contrast-enhanced T1-weighted imaging. The sagittal (E) and axial (F) T1-weighted imaging did not reveal clear cerebellar atrophy.




Figure S2 *KCNC1* p.R317S variant of the proband family. *KCNC1* p.R317S variant of this family was demonstrated by NextGENE viewer. From left to right is the proband, his father and mother.

Table S1 Sequencing quality scores of the proband and parents

Sequencing quality scores	Proband	Father	Mother
Total reads	86,590,137	92,721,186	99,109,767
Q20	98.3%	98.4%	98.3%
Q30	95.7%	95.7%	95.6%
Average coverage	484.9x	502.9x	571.2x
>10x percentage	99.1%	99.1%	99.0%
>20x percentage	98.9%	99.0%	98.9%